

PHILOSOPHICAL TRANSACTIONS.

I. *Contributions to the Comparative Anatomy of the Mammalian Eye, chiefly based on Ophthalmoscopic Examination.*

By GEORGE LINDSAY JOHNSON, *M.D., F.R.C.S.*

Communicated by H. GADOW, F.R.S.

Received May 2,—Read May 17, 1900.

(Plates 1–30.)

CONTENTS.

	Page
SUMMARY	1
INTRODUCTION	7
PART I. Special descriptive part, recording observations as to the appearance of the Fundus oculi by means of the ophthalmoscope in 182 species of Mammals examined. These fall under 103 genera and 47 families, comprising nine out of the eleven natural orders, the Cetacea and Sirenia being omitted.	
Observations as to the refraction of these animals, the divergence of their optic axes, peculiarities of their irides, pupils, and other features are likewise described	9
PART II. Divided into eleven chapters, viz. :—	
CHAP. I.—The Colour of the Fundus oculi and the Tapetum lucidum	36
„ II.—Vascularisation of the Retina	42
„ III.—Reversions of Type and Vestigial Relics	49
„ IV.—Shape and Colour of the Optic Disc	57
„ V.—Shape of the Pupil	58
„ VI.—Divergence of the Optic Axes.	60
„ VII.—Refraction	61
„ VIII.—Binocular Vision	62
„ IX.—Physiological Considerations	65
„ X.—Influence of Domestication.	66
„ XI.—The Ophthalmoscopic Appearance of the Fundus oculi as bearing on Classification	67

SUMMARY OF CONCLUSIONS.

THE colour of the Fundus oculi in animals devoid of a tapetum is mainly determined by reflection from the choroidal pigment. In animals possessing a Tapetum cellulosum (Carnivores), the colour of the fundus is mainly determined by the colour of the retinal pigment. In animals which have a Tapetum fibrosum (Ungulates), the colour

is determined by the structural colour of the tapetum modified by the colour of the retinal pigment. All the animals which I have examined may be considered as capable of being classified under one of three heads:—

1. *The Red Type*, including every shade of red, chocolate, brown, and grey. To this belong Man and all the Primates (with the exception of the Galagos and Loridae); certain Insectivora; the Suricate and Cynictis, among the Carnivores; the Camelidae, Suidae, Rhinoceros, and Hyracoidae among the Ungulates; all the Rodents (with the exception of Pteromys and the Spotted Cavy); the Edentata; the Marsupials (with the exception of the Virginian Opossum), and the Monotreme Echidna.

2. *The Yellow Type*.—This includes all shades of yellow and orange. To this belong the Galagos and Lorides among the Primates; the Chiroptera; some of the Felidae and Mustelidae; the Tapir and Elephants among the Ungulates, and lastly the above-mentioned Flying Squirrels and Spotted Cavy among the Rodents.

3. *The Green and Yellow-green Type*.—To this belong all the Carnivores, with the exception of those already mentioned; all the Selenodonta, with the exception of the Goats and Camels.

The red end of the spectrum is the most common, next the orange and yellow, and then the green, the colours being rarer in proportion to their refrangibility.

The vascularisation of the retina can be summarised as follows:—

1. *Indirect Supply*.—By means of osmosis from the vessels of neighbouring parts.
 A. Hyaloid supply. (a) The corpus vitreum is nourished by a processus falciformis, the hyaloid vessels lying well inside the corpus vitreum (Elasmobranchs). (b) The hyaloid vessels spread over the surface of the corpus vitreum, being in consequence in the immediate vicinity of the retina (*e.g.*, holosteous and many teleosteous fishes). Hereto belong also the Amphibia and most of the Reptiles devoid of a pecten.
 B. Choroidal supply. This is probably the chief supply of the retina in those animals which possess a well-developed pecten (most Sauropsida), but are devoid of superficial hyaloid vessels. This choroidal supply by osmosis is also with certainty demonstrated in the Mammalia for at least part of the thickness of the retina.

2. *Direct Supply*.—A. From the superficial hyaloid vessels. This is known to be the case when the hyaloid vessels are directly continued into the retina, where they produce two vascular layers. B. From special retinal vessels cumulating in the arteria centralis. This mode is restricted to the Mammalia and some of the Snakes.

The vessels of the falciform process of the Fishes and the central hyaline artery, wherever this occurs, are essentially the same. The falciform process and the pecten are analogous, but not homologous, structures. In Reptiles and Birds the hyaloid artery is superseded by a new development, viz., the Pectinal system. In some of the lower Mammalia both systems actually occur side by side, but both are rendered unnecessary by the development of a third system of supply, viz., special retinal vessels, which ultimately culminate in the possession of an arteria and vena centralis retinae.

Some of the normal conditions observable in certain animals closely resemble those which we find in Man as congenital defects or vestigial relics. 1. *Membrana nictitans*. A fully developed nictitating membrane, active enough to sweep the whole cornea, exists only in the Ungulata, and not even throughout this order. In the Carnivora and Marsupials it is much less developed, whilst throughout the Primates, Insectivora, Rodents, Edentata, and Echidna it is still more reduced, and with rare exceptions entirely without movement. The primary use of this third lid, viz., that of cleaning the corneal surface, is lost within the class Mammalia, and seems to serve chiefly to protect the eye in the animals which graze and poke their heads down into the long and sharp grass. 2. The retractor muscle of the eyeball is of frequent occurrence, chiefly in Marsupials, Edentates, Rodents, and Insectivora, *i.e.*, in the lower orders of Mammals. 3. Opaque nerve fibres. All stages of opacity occur congenitally in Man, and are to be found normally throughout the Mammalia. Opaque nerve fibres are most marked in some of the Rodents and Marsupials. 4. Physiological Cup and congenital discoloration of the disc frequently occur in Man. An appearance similar to the physiological cup occurs in all Felidæ, and in a considerable number of the other Carnivora; also in the Flying Squirrels and some of the other Rodents. White and grey discs occur normally in a number of animals widely separated in classification, such as the Skunk, Rhinoceros, Porcupine, Armadillo, and Echidna. 5. Structures protruding from the disc into the corpus vitreum. A. Persistent hyaline artery. This congenital defect in Man is found as a normal condition in nearly all the Ruminants, and in a large number of Rodents. B. Vestiges of a pecten. In some of the Rodents, more especially in all the Agoutis, a button-shaped vascular pigmented rudimentary pecten protrudes from the disc into the vitreous. It is remarkable to find in the Mammalia a relic of this Sauropsidan organ. In a number of Marsupials vascular protuberances from the disc into the vitreous occur in different forms. 6. Colobomata. The papillary coloboma (FUCHS' Coloboma) has its analogy in a white or coloured scleral ring, which is normally met with in a large number of animals. 7. Retinitis pigmentosa. In the Galagos and Lorides a spreading of pigment occurs circumferentially in the retina which greatly resembles Retinitis pigmentosa. If these nocturnal animals are exposed for prolonged periods to daylight, the pigment advances concentrically, similar to the manner in which it progresses in Man, so that the animals gradually go blind. 8. Visible choroidal vessels and stippled fundus. Visible choroidal vessels occur in most of the Simiæ below Hylobates, and in a number of the other orders. They are most marked in the Macropodidæ and some of the other Marsupials, which present the appearance observable in the extreme cases of the analogous congenital defect in Man. Stippled fundi are found in the feline *Douroucoulis* and in the Lemurs, an appearance occasionally met with in Man. 9. Ectropion of the Uvea. In a number of the Ungulates which have large oval pupils, either pigmented excrescences or a specialised development of the elastic fibres of the iris are met with, and these evidently serve to screen the eye against

glare, since their pupils only contract moderately to light. In the Hyracoidæ we meet with a distinct specialised organ, which can be projected from the iris towards the cornea like a small screen, and this I propose to call the Umbraculum. (See p. 27.)

The shape of the optic disc in the Mammalia is mostly circular; exceptions occur in the Carnivore Cynictis, which has a horizontally oval disc, whilst in the Wolves, Jackals, and Foxes we find it lozenge or kidney-shaped. The disc is horizontally oval in most of the Artiodactyls and in all the Equidæ, but we find it circular in the Goat, Llama, Camel, Tapir, and Rhinoceros.

The disc lies either on a level with the retina, or is sunk below it, forming a kind of cup, a feature almost entirely confined to the Carnivora and Flying Squirrels.

In Man and all the Simiæ the disc is rosy pink or red; whilst in the Galagos and Loridæ it is black or green. In the Lemurs, Bats, Rodents, Edentates, Marsupials, and Echidna it is chalky-white. It is red or pink in nearly all the Artiodactyls, whilst in the Perissodactyls, Hyracidæ, and Elephantidæ it is white or cream coloured, with the only exception of the Equidæ, which have red discs. In the Hedgehog and Mole the discs are a bright red. The greatest diversity of colour prevails in the Carnivora, viz., grey, brown, red, and various shades of buff and white.

The shape of the pupil is circular in most of the Mammalia. It is slightly vertically oval in the Lemurs and the Galagos, Foxes, Raccoon-like Dog, Lycaon, Hyæna Striata, Melursus, Coipu, Capybara, and Spotted Cavy. Vertical slit-like pupils, dilating to a true circle, or nearly so, occur in a number of Felidæ and in the Pinnepedia. The pupil is horizontally oval in Cynictis and Herpestes, all the Artiodactyls, Equidæ, Hyracidæ, Cetacea, and Sirenia, the Marmots, Viscacha, and a few Sciuridæ.

The shape of the pupil and that of the disc seem to concord to some extent; this is especially marked in the Ungulates.

The divergence of the optic axes follows the classification to a marked degree. The higher the order the nearer the axes approach parallel vision. Parallel vision with the power of convergence only occurs in those animals which possess a true macula, viz., Man and all the Simiæ. In other words, convergence appears to be the necessary outcome of a macula. This macula, which is bounded by a reflex ring, exists in all Simiæ and *in no other Mammals*, so that the macula ceases with the last of the Simiæ.

If we eliminate the domestic animals, in which the refraction varies over considerable limits in all directions, we find throughout the Mammalia, with a few notable exceptions, vision is hypermetropic. The eyes of amphibious and marine Mammals are adapted for vision in two ways. Those which live in fresh water have immensely developed ciliary muscles and proportionally increased accommodative power, enabling them to compensate for the loss of the refractive power of the cornea when the eye is submerged. In the marine Mammals, *i.e.*, Pinnipedia and Cetacea, not only is this

ciliary muscle greatly developed, but there is always a large area of the cornea which is flattened in the horizontal meridian, producing an extraordinary degree of astigmatism.

Binocular Vision.—It seems that if Mammals below the Simiæ have binocular vision, they do not rely entirely on it. With the exception of Man and the Simiæ, Mammals very rarely move their eyes for the purposes of vision, but move their heads instead.

In all the Mammals below the Simiæ which have no macula we find a larger sensitive area, which, however, cannot be even roughly defined by means of the ophthalmoscope, since, except in the Ruminants and Carnivora, there is no alteration in the colour of the fundus, or marked absence of retinal vessels to serve as a guide in locating it. Sensitive areas of restricted dimensions, omitting those cases in which the area is limited to a macula, exist in the Carnivora, in which order the divergence is not great. In the Ungulates, Rodents, Edentates, and Marsupials, where we find great divergence of the axes, large corneæ, and nearly spherical lenses, the sensitive areas are larger, and probably the degree of difference in perception over such areas, compared with the more peripheral parts, is but little.

The great transparency of the retina and the extreme brilliancy of the reflecting surface of the choroid in the vast majority of Mammals, and the extraordinary prevalence of colours of every hue, lead one irresistibly to the conclusion that the rays of light do not form an image on the retina as usually taught, but that the image is formed behind the retina on the brilliant surface of the tapetum or fusca pigment layer of the choroid, and is then reflected back on to the terminals of the bacillary layer. This arrangement for vision certainly bears a close resemblance to LIPPMANN'S method of obtaining coloured negatives. He obtained negatives in natural colours by placing a reflecting mercury surface in direct contact with the sensitive film, thus reflecting the light which had traversed the film on to the particles of sensitised silver. In the eye the light passes through the nearly transparent retina (which is analogous to the photographic film), to be reflected on to the terminals of the retinal elements (which may be compared to the particles of silver haloid). In LIPPMANN'S device the colours are produced by interference of light-waves. If we venture to carry our analogy still further, we may presume the same occurs in the eye. One difference between the two methods is that in nature the reflecting surface is always coloured, and only reflects a portion of the incident light. The colour of the fundus, however, is remarkable for the absence of blues and violets, and the great prominence of red, yellow, and green colours. Yellow and orange are the prevailing colours in nocturnal animals. The peripheral area, which is characteristic of animals possessing a tapetum, is usually dark brown, and reflects but feebly. It is probably nearly insensitive to light, as it never occurs in animals having great divergence of the optic axes.

The eye is no exception to the rule that domestication greatly increases variability.

The colour of the Fundus oculi of domesticated races differs not only from that of the wild species from which the races are supposed to be derived, but the colour varies also individually, an occurrence almost unknown in wild species. The influence of domestication, which is merely life under unnatural surrounding conditions, is also well indicated by the frequent occurrence of myopia and astigmatism, which we find most prevalent in the Horse and most marked in the Rabbit, if we compare the latter with the high degree of hypermetropia in the Hare. This myopic condition probably receives its explanation in the small dark hutches in which these Rodents are generally confined. Myopia is almost unknown in wild animals, but it may occur in wild specimens which have long been kept in captivity.

The results obtained afford yet another striking testimony in support of the theory of evolution and the existence of ancestral forms from which the various branches have differentiated.

Although no sound classification can be based on one single organ, a striking concordance exists between an attempted arrangement of the Mammalia according to the Fundus oculi and the most modern classification. The cases of disagreement are wonderfully few; these are restricted to the following:—

Chrysothrix leans towards the Arctopithecii, but since its dentition and cranial characters are distinctly platyrrhine, the aberrant fundus must be due to a case of convergence. I find it necessary to separate the Galagos from the rest of the Lemurs, at least as a sub-family. In the smaller Carnivores it is advisable to establish a separate family, the *Cynictidæ*, to include the otherwise viverrine genera *Cynictis* and *Galictis*, together with *Mephitis*, hitherto placed with the *Mustelidæ*. The *Sciuro-morpha* should be divided into *Sciuridæ* and *Pteromyidæ*, and *Castor* should decidedly be removed into the *Hystricomorpha* group, perhaps into the vicinity of the *Octodontidæ*. The Bats and *Insectivora* rank very low as far as the eye is concerned, possibly on account of their nocturnal habits. Among the Marsupials the *Diprotodontia* are decidedly lower than the *Polyprotodontia*, chiefly on account of the high degree of development of the eyes of the *Didelphidæ* and *Dasyuridæ*. It is probable that the *Polyprotodontia* and *Diprotodontia* are really two divergent groups of equal age, and that in spite of the reduction of the lower incisors the *Diprotodontia* assume the lower rank. Since we meet with genera of the lowest type along with others of the highest type of retinal vascularisation, and again some without, and others with, the additional relic or specialisation of a tapetum, it follows that the details of the vascularisation and of the tapetum have been developed independently in the various main branches of the Mammalia. In fine, the whole Fundus oculi affords a striking illustration of the working of progressive evolution, an example all the more valuable since it illustrates the direct modifying effect of external factors upon a highly-specialised organ, in the present case the continued influence of light upon the eye.

INTRODUCTION.

Notwithstanding an extensive literature, a comprehensive comparative anatomy of the mammalian eye still remains unwritten. Microscopical examination is a tedious process, the procuring of absolutely fresh material is by no means easy, and, after all, fresh material is only to be found in the living eye. No amount of fixation or staining will recover what the delicate internal parts lose within a short time after death. It is here that the ophthalmoscope supplies a reliable and most valuable method of research. That instrument has hitherto been rarely used in comparative investigation; a few observations and illustrations relating to the Dog, Cat, Horse, and a few other domestic animals are to be found in articles scattered throughout various journals, the references to which will be found in the 'Archiv für vergl. Augenheilkunde.' The drawings are mostly small, and usually obtained by the indirect method. The only treatise dealing with the subject is that of NICOLAS and FROMAGET.* These authors have used the direct method, and examined a considerable number of Horses. They have likewise described and depicted the Dog, Cat, Ox, and Goat, and made notes as to the appearance of the Fundus oculi of the Ass, Mule, and Sheep.

My observations extend over a much wider field, and it was not until a large number of animals had been examined, embracing nearly all the families of the Mammalia, that I felt justified in making an attempt at generalisations. A list of the species examined will be found in Part II., Chapter XI., p. 68.

A few words are necessary in order to explain the methods of observation, and how the numerous coloured drawings have been produced. A small selection of these drawings will be found on the accompanying plates.

At first I found it difficult to see the Fundus oculi of some of the animals by the direct method of examination, which necessitates almost contact of the ophthalmoscope with the eye of the animal. This method has the immense advantage of giving not only higher magnification and much greater detail than the indirect, but also of avoiding the distortion caused by the use of an intermediate lens. I therefore persevered in its use, and at length with practice succeeded perfectly. Artificial light was used so as to obtain the same illumination in all cases. In order to keep the animals quiet I began by using anæsthetics, but soon found this undesirable and quite unnecessary. Some of the animals were muzzled and occasionally covered with a net, but, as a rule, kindness, coaxing, and taming proved sufficient. I used the ordinary ophthalmoscope with a swing mirror and correcting lenses, substituting a mirror with a smaller aperture when examining animals with minute pupils. The eyelids were held apart with the fingers, or spring specula, and mydriatics, viz., homatropine, scolopaine, or cocaine, were used in most cases. Wherever possible,

* "Précis d'Ophthalmoscopie Vétérinaire," Paris, 1898.

several animals of the same species were examined in order to eliminate errors due to individual peculiarities or disease; and in all cases both eyes in the same animal were examined. When I had attained considerable practice in dealing with animals and examining their eyes in a darkened room, I was fortunate enough to obtain the assistance of that well-known artist and excellent draughtsman, Mr. A. W. HEAD, F.Z.S. It is entirely due to his talent that I have been able to obtain a great number of excellent and faithful drawings of the Fundus oculi of most of the Mammals to be found in the menageries and zoological gardens of Europe. The chief work, however, was performed in the Gardens of the Zoological Society of London, and I wish here to record my indebtedness to Mr. SCLATER, F.R.S., Mr. BARTLETT, and Mr. THOMSON for their invaluable help and kindness. I noted each peculiarity before it was drawn by the artist, and examined the animal from time to time while the drawing was being made on the spot to ensure accuracy and correctness of detail and colouring.

The magnification obtained with the ophthalmoscope by the direct method varies with the proportionate distance between the posterior nodal point and the retina of the eye examined. The magnification, therefore, varies in the different animals between 10 and 20 diameters, being greatest, of course, in the case of small-eyed animals. The drawings were made to represent the apparent ophthalmoscopic size in each case, and their field was limited to the area which comprised all the essential features.

In every case when examining the eye of the animal with the ophthalmoscope, I determined the refraction by retinoscopy, and whenever possible both with and without atropine. The shape of the pupil as well as any peculiarity of the eye generally were carefully noted, and the angle of divergence of the optic axes was determined by means of a specially-devised goniometer (see p. 60).

Having collected about 200 coloured drawings of the Fundus oculi of different animals, and having made extensive notes throughout, I found it necessary to select a zoological guide, and ultimately adopted the classification of the Mammalia given by GADOW in his 'Classification of Vertebrata,'* as being based on the most recent morphological investigations.

The more recent the classification selected, the closer did my results conform to it, notwithstanding the other numerous considerations which zoologists have had to take into account. Although it has been necessary to restrict the number of illustrations in this paper, they are sufficient to show that the eye is a valuable additional factor in classification, and that where its characters do not agree with the most recent systems, the discrepancies deserve serious consideration.

Some of the results obtained are, moreover, of phylogenetic value, and the well-defined traces of vestigial relics which I have found in many instances, are interesting from an evolutionary point of view.

* 'A Classification of Vertebrata,' London, 1898.

Lastly, the fact that certain conditions which occur in Man as congenital defects are normal in some animals, may assist the ophthalmologist in diagnosis, and we shall certainly find abundant field for physiological speculations which may advance our knowledge of vision, and bring us nearer to the solution of the problem of colour perception.

The first part of this paper contains a systematic record of the observations made. In the second part some of the implied problems and resulting generalisations are dealt with.

I cannot conclude this introduction without expressing my deep indebtedness to my friend Mr. H. DE MOSENTHAL, F.I.C., who has assisted me throughout in the arrangement of the well-nigh overwhelming material, and the co-ordination of the facts arising from it: his assistance has been of the utmost value in compiling this paper.

Lastly, I have to thank Dr. H. GADOW, F.R.S., for his uniform kindness to me, and for the encouraging interest he has taken in this work.

PART I.

I. PRIMATES.

A. *Simiæ*. a. *Catarrhinæ*. 1. *Anthropoidæ*. (Plates 1 and 2.)

1. *Homo*.—When examining the normal eye of Man with the ophthalmoscope, we perceive the fundus of an orange-red or vermilion ground. To the inner side of the axial line of vision we see a well-defined circular or oval pinkish disc—the so-called Blind Spot. Here the optic nerve enters the eye to spread out into the nerve fibre layer of the retina. This disc lies in the same plane as the surrounding retina, and from its centre the retinal arteries and veins branch out in various directions over the entire field. Two and a half disc breadths towards the outer, or temporal, side of the disc we perceive a small circular patch of slightly darker hue than the surrounding fundus, which is known as the Yellow Spot, or Macula lutea. This is usually bounded by a circular reflex ring, which comprises the area of distinct vision. The arteria centralis retinæ enters the eye through the centre of the optic disc, on the surface of which it divides into four main trunks, which subdivide into numerous branches to spread out over the entire fundus, with the exception of the area surrounding and including the macula, a similar arrangement of veins accompanying the arteries. The arteries never anastomose with one another, nor do the veins. In addition to the retinal vessels, we frequently notice a certain number of the vessels of the underlying choroid. They appear numerous and conspicuous in Albinos, fair-haired children, and old people, and more especially in those cases in which the choroid has undergone degenerative changes. They are quite different in appearance from the retinal vessels, being of an orange colour, very broad, and anastomosing freely. Except in Albinos they are rarely to be seen near the macula, but can be seen towards the

periphery of the field. At the macula itself they are never visible, except in disease.

The ophthalmoscopic appearance of the Fundus oculi is practically the same in all the various races of Man, the colour of the background alone differing. In fair-haired Europeans this is of an orange-red, and in brown-haired Europeans of a crimson colour; in North American Indians and Mongolians, brownish-red; in the majority of the natives of India, reddish-brown; and in the Negro type, of a dark chocolate colour.

In the black races, the reflexes or glistening sheen of the retina in the neighbourhood of the vessels and macula, observable to some extent in every hypermetropic dark eye, are very striking in youth; and the minute fibres of the optic nerve, which radiate in every direction from the disc, although quite invisible in Europeans, form in them innumerable semi-transparent striæ.

2. *Troglodytes* and 3. *Simia*.—The Chimpanzee (*Troglodytes niger*), the Gorilla (*T. gorilla*), and the Orang (*Simia satyrus*), have a fundus which closely resembles that of the Negro in almost every detail. We find the same chocolate-coloured field with a darker coloured macula area bounded by a bright circular reflex ring; the same distribution of vessels; the round or vertically oval pink disc, and the same semi-transparent nerve striæ. In fact, with the exception of the colour of the fundus, the general characteristics found in Man are common to *all* the Catarhinæ (Old World Monkeys), and all the Platyrrhinæ (New World Monkeys).

4. *Hylobates*.—The Gibbons have a fundus which departs somewhat from that of the other Anthropoidæ, inasmuch as the choroidal vessels are very marked, and appear as orange-red stripes radiating from the disc as a common centre.

2. *Cercopithecidæ*. (Plate 3.)

1. *Macacus*.—*M. inuus* (Pig-tailed Macaque), *M. rhesus*, *M. cynomolgus*, *M. speciosus* (Japanese Ape), *M. sinicus* (Bonnet Monkey), are all very similar, the appearance and distribution of the choroidal vessels resembling that of the Gibbon. The disc, the retinal vessels, and the semi-opaque nerve fibres are the same as in the Anthropoid Apes.

2. *Cynocephalus*.—*C. porcarius* (Chacma Baboon), *C. mormon* (Mandrill), *Papio hamadryas*, and *Papio flavus* (Yellow Baboon) also closely resemble the Gibbon and the Macaques—but the choroidal vessels are more marked in the Mandril than in the Baboon.

3. *Cercopithecus* generally resembles the other Catarhine Monkeys. *C. albigularis* (SYKES' Monkey) resembles the Mandril. *C. diana* has a grey fundus, and the choroidal vessels cannot be seen, due no doubt to this being a highly-pigmented animal. *C. callitrichus* (Green Monkey) has a fundus like the Mandril, except that the macula is double the diameter of that of any of the other Old World Monkeys.

4. *Cercocebus*.—*C. collaris* and *C. fuliginosus* again bear a close resemblance to the Gibbon, as well as to the other Cercopithecidæ.

5. *Cynopithecus*.—*C. niger* (Black Ape) again no doubt on account of its dark colour has a grey fundus similar to that of *Cercopithecus diana*, and the fundus being dark, the reflex from the vessels and macula ring is very marked.

b. *Arctopithecii*. (Plate 3.)

1. *Hapalidæ*.—The Hapales, or Marmosets have, to judge by the eye, been correctly placed by GADOW in a separate sub-order. They have the fundus peculiar to the strongly pigmented Old World Monkeys; but with a very large macula area—as large in fact as *Cercopithecus callitrichus*, but with this difference, that the reflex ring shows a play of prismatic colours—a peculiarity which I have only found in one other animal, namely, in the Squirrel Monkey (*Chrysotrrix sciureus*), which occupies no doubt the highest position in the next sub-order.

c. *Platyrrhinæ*. (Plate 4.)

The Platyrrhines do not differ from the Catarhines to anything like the extent I would have expected. My observations fully confirm HUXLEY'S axiom as to the similarity between Man and the other Simiæ, in contradistinction to the Prosimiæ, but not HÆCKEL'S view that the axiom can be restricted to the Catarhines alone.

1. *Cebidæ*.—At the head of the family I place the genus *Chrysotrrix*, on account of the prismatic halo around the macula referred to above. Then follow *Lagothrix*, *Ateles*, *Mycetes*, *Cebus*, and *Nyctipithecus*. They all have the characteristics which we find in the Cercopithecidæ. The disc and the vessels are those common to all the Simiæ; choroidal vessels can be seen in all except the highly-pigmented animals, and they have all distinct maculæ. The *Nyctipithecii*, which I place lowest among the Platyrrhine Monkeys, have a fundus stippled all over with minute brown dots. The appearance is very similar to that which we shall find in the Lemuridæ, so that, but for the great distinction due to the presence of a macula, the *Nyctipithecii* closely approach the higher forms of the Prosimiæ, a coincidence probably due to their nocturnal habits.

All the Simiæ have invariably circular pupils, which dilate to mydriatics and contract to myotics, convergence, and light, and in that respect there is no difference except in degree between Man and the other Simiæ. The Simiæ are the only Mammals which have the visual axes parallel, and which possess the power of convergence, factors which seem to be the necessary consequence of the presence of a macula. This convergence is longest sustained in Man, most of the Monkeys being only able to converge for a very short period. In fact, the Mandril (*Cynocephalus mormon*), the Black Ape (*Cynopithecus niger*), and the Red Howler (*Mycetes seniculus*) are the only Monkeys in which I have observed any sustained convergence.

The refraction of all the Monkeys is similar to that of savage Man, viz., slight hypermetropia without astigmatism, the only exception being the Mandrils and Drills, which are all myopic to the extent of 3 D to 6 D.* I have examined six Mandrils and one Drill, and found them all myopic, and in both eyes equally. The Membrana nictitans is rudimentary throughout the Simiæ, as in ourselves—in only one species (*Cynocephalus porcinus*) did I find it capable of any movement. One difference between Man and all the other Simiæ is that Man alone has the power of shedding tears, with the result that the Puncta lachrymalia and canaliculi in all the Simiæ except Man are rudimentary and almost invisible to the naked eye. In all the Simiæ I find the caruncle as in Man, except in the *Papio hamadryas*, in which Monkey the caruncle is capable of being pushed forward in front of the canthus to about 2 millimetres, and retracted apparently at pleasure.

B. Lemures. (Plates 4 and 5.)

The division between Simiæ and Prosimiæ is extremely marked, since in the Simiæ the macula is invariably present, whilst in the Prosimiæ it is entirely wanting, and vascular branches often cross its area, which is never the case in the Simiæ. The pupil is no longer circular, but vertically oval, and the visual axes are not parallel, but slightly divergent. The animals also are incapable of convergence. Moreover, the disc is no longer pink, but entirely or partially covered with black pigment, being white where visible.

1. *Chiromyida*.—I have seen an Aye-Aye, but unfortunately could not get close enough to examine details, owing to its excessive timidity, but the colour of the fundus seems to resemble that of the Galagos.

2. *Lemurida*.—I find two well-marked divisions in the Lemuridæ. I propose to place the true Lemurs in a separate family, and into another family the genera Galago, Nycticebus, and Loris.

The Lemurs, of which I have examined *L. brunneus*, *L. coronatus*, *L. macaco*, *L. niger*, and *L. variegatus*, have all a fundus of a brown or reddish-brown colour, covered with minute pigment spots at regular intervals. Their disc is chalky-white, the margin and often one sector being pigmented. In all, choroidal vessels can be seen with more or less distinctness. In many cases semi-opaque nerve fibres are visible, radiating from the disc, and the area which in all the Simiæ embraces the macula, is noticeable by the absence of visible choroidal vessels, although, contrary to what we find in all the Simiæ, fine retinal vessels pass over it. The pupils are vertically oval, and the eyes do not converge on accommodation. *L. coquerelli* forms

* D in ophthalmic parlance is used to indicate a Diopter, i.e., the refractive power of a lens having a focal length of one metre: hence 3 D has three times this refractive power, and is equal to a lens having a focal length of one-third of a metre; in other words, the myopia in the Mandril can be corrected by lens of this focal length.

an exception; it possesses all the features present in the Fundus oculi of the Galagos, and none of those to be found in the Lemur's eye.

Galago, Nycticebus, and Loris.—All the species examined, viz., *Galago Garnetti*, *G. Maholi*, *G. Monteiroi*, *Loris nycticebus* and *Loris tardigradus*, have black pigmented discs with green margins. The fundus of these animals is a golden yellow of extraordinary brilliancy, like burnished gold, the peripheral area being composed of more or less dense black moss-like patches of pigment, which frequently invade the retina itself in the form of minute detached branches. This appearance strikingly resembles the condition of the human Fundus oculi in the congenital disease known as Retinitis pigmentosa, a fact which I shall refer to in detail on page 55.

The brilliant orange-yellow colour, which we here meet with for the first time, will be found peculiar to almost all Mammals of nocturnal habits.

The brilliantly coloured zone surrounded by a heavily pigmented peripheral area, and the invisibility of choroidal vessels, are indicative of the so-called Tapetum lucidum, common to almost all the Carnivora.

The Galagos and the two other above-mentioned genera have vertically round oval pupils similar to the Lemurs, but they act more readily to light and mydriatics.

Reviewing the Primates, we find a striking difference between the Simiæ and Lemures—the Simiæ alone possessing the differentiated and highly-sensitive area known as the Macula lutea. Hardly any difference can be seen between Man and the Anthropoid Apes. The Platyrrhine Primates closely resemble the Catarhine forms, with the exception of the Douroucoulis (*Nyctipithecii*), which, but for the macula, could be taken for Lemurs. The true Lemurs approach the Simiæ, whilst the Lorides, Galagos, *Nycticebus*, and Aye-Aye have entirely different fundi, approaching in character the fundi of the Carnivora.

In all the Primates the Membrana nictitans is rudimentary and useless. In all, except Man, the Puncta lachrymalia are minute and on a level with the edges of the lids, and the entire lachrymal apparatus is elementary. All the Simiæ have circular pupils—in all the Lemures the pupil is vertically oval. Man alone can sustain convergence; all the other Simiæ have the *power* of convergence, but only for a moment, or at the most for a moderate time. Directly we descend below the last of the Simiæ, convergence ceases and the macula disappears.

The Simiæ alone among the Mammals constantly rotate their eyes for directing vision. The Lemures and all Mammals below them move their heads instead, and only on rare occasions and to a limited degree do they move their eyes for visual purposes. In all the Simiæ, with the exception of the Drills and Mandrils, we find the eye is emmetropic or slightly hypermetropic, as in savage Man.

II. CHIROPTERA. (Plate 6.)

1. *Emballonuridæ* and 2. *Vespertilionidæ*.—Owing to the scarcity of Bats in menageries, and the exceedingly minute eyes and pupils of those which I have been

able to secure, I have found it impossible to examine any of these Bats with the ophthalmoscope in such a manner as to observe detail, but I was able to see that one of the English Bats (*Vespertilio Natterii*) has an ochre-yellow fundus.

3. *Pteropodidæ*.—The Indian Fruit-bat (*Pteropus indicus*) and the Australian Fruit-bat (*P. poliocephalus*) have ochre-yellow fundi, which appear pitted at perfectly regular intervals by dark depressions. Microscopic sections show that these depressions are due to nipple-shaped protuberances of the choroid covered with dense pigment. The disc is chalky-white and round, and a white nipple-like prominence is observable in the centre of the disc. The pupils are large and round and only act moderately to light and mydriatics. Continued exposure to daylight causes blindness. No choroidal vessels can be seen in the fundus, nor are any retinal vessels discernible. Microscopic examination of the eyes of the Fruit-bats as well as those of the English Bat show, that the vascularisation of the retina is restricted to capillaries only. This condition seems to denote a very low degree of development, because we have to descend very far down the scale before we meet with it again. Some of the Sub-ungulates, a few Rodents, and the Edentata are the only other placental Mammals similarly devoid of retinal vessels. Is this primitive condition of the eye of the Bats due to arrested development or partial degeneration of that particular organ through disuse, or must we regard it as disputing the high rank which zoologists have assigned to these strange Mammals? Typical Vespertilionæ are undoubtedly met with in the Eocene epoch, a fact which favours the view that the Bats are really a low, although in many respects a highly-specialised, order. (See also Part II., p. 68.)

III. INSECTIVORA. (Plate 6.)

In *Erinaceus europæus* (Common Hedgehog) the fundus is light grey in colour and uniform all over. The disc is red, and four straight retinal vessels radiate from its centre, throwing off a few branches; no veins can be seen accompanying the arteries. The pupil is small and round.

I examined the eye of the Common Mole (*Talpa europæa*) immediately after death, by removing the front part of the eye, and placing the posterior half under the microscope illuminated by reflected and concentrated light. I found the fundus to be a buff colour, which gradually turned to bluish-green. The disc and the vessels were identical in shape, colour, and position with those of the Hedgehog. The pupil of the Mole is round and microscopic in size. The cornea is very conical and the lids resemble a buttonhole, and are, like those of the Hedgehog, destitute of lashes. The globe can be projected forwards several times its own diameter beyond the orbit, and retracted in like manner. This is necessary for vision, since the dense fur entirely covers the eye when retracted, and it is only by pushing the eye forward between the hairs and making a gap in the fur that the animal can see.

IV. CARNIVORA.

All the Carnivora, with the exception of the Suricate and the Cynictis, have a Tapetum lucidum, such as we have already met with in the Galagos. A peculiarity of this tapetum, due, as we shall see on page 38, Part II., to an opacity of the inner layers of the choroid, is that choroidal vessels can never be seen except in some rare cases, and then only at the extreme limit of the peripheral area. In the Pinnipedia, the Tapetum lucidum is of the same colour all over the visual field, but in all the Fissipedia (with the exception of the Suricate and the Cynictis, which have no Tapetum lucidum) the fundus shows at least two coloured zones: a central zone, known as the Tapetum lucidum, and a densely pigmented peripheral zone, known as the Tapetum nigrum. The Tapetum lucidum, *i.e.*, the central zone, is in many cases further divided into two, and sometimes three, differently coloured areas. The peripheral area appears at the bottom of the pictures. The vascularisation of the Carnivora is most prolific in the Pinnipedia, and in the animals of the sub-order I could not distinguish between veins and arteries. In the Fissipedia, the number of vessels varies considerably, but in all cases we find the arteries accompanied by their veins, and in most of these animals the vessels radiate from the disc with a certain regularity of distribution so as to maintain a star-like appearance. There are, however, among the Viverridæ and Canidæ a number of animals the vascularisation of which is not star-like, but the main trunks of the vessels run straight upwards and obliquely downwards.

In a large number of the Carnivora, more especially the Felidæ, the disc is cup-shaped, lying below the level of the retina, the main trunks curling over the edge. The appearance of this cup resembles the congenital condition known in Man as the "physiological cup," but is still more marked, closely resembling the pathological condition known as glaucomatous cupping.

In all the Carnivora the disc is round, with the exception of some of the Viverridæ, in which we find horizontally oval discs, and in the Canidæ, in which the shape of the disc varies considerably.

The shape of the pupil is, as a rule, circular, but there are a number of exceptions, some of which are not without taxonomic importance.

The refraction shows but slight departure from emmetropia. As a rule, there is little or no astigmatism, thus showing a marked contrast with the Ungulates. The axes of vision are never parallel, but the divergence is in general but slight, measuring 5° to 20° for each eye. There is a complete absence of the power of convergence, at least among the wild species of Carnivores; and even domesticated animals, unless specially trained, do not move their eyes either for convergence or visual purposes, but they move their heads when they want to see in any direction other than the primary position. All the Carnivora, with the exception of the Skunk, have a

movable *Membrana nictitans*, although very few of them use it freely, and some not at all.

As the majority of the Carnivores are either nocturnal animals or animals which prowl at dusk, we find in the central portion of the fundus either a golden yellow or a bright green, and frequently both these colours are found intermixed.

The appearance of the *Fundus oculi* agrees well with the usually-accepted groups of the Carnivora, the only marked exceptions being the *Cynictis*, the *Suricate*, and the Canadian Skunk, the two former resembling the *Suidæ*, the latter having several points in common with the Rodents. These three animals ought evidently to occupy a lower position than that assigned to them, unless other considerations outweigh the indications afforded by the appearance of the *Fundus oculi* and other characteristics of the eye.

A. *Pinnipedia*. (Plate 7.)

1. *Otaridæ*.—I have examined a Sea Lion (*Otaria jubata*). The retinal vessels as well as the disc resemble those of the Seal, but the colour of the fundus is orange-yellow.

2. *Phocidæ*.—The British Seal (*Phoca vitulina*) has a fundus of a very pale straw colour, stippled throughout with minute emerald-green dots, a stippling which is almost universal among the higher Carnivora, but the fundus is uniform in colour, there being no peripheral zone. Although there is evidence of the existence of a *Tapetum lucidum*, we do not meet with the same brilliancy of colour that we find in the *Fissipedia*. The pupil of the Seal is circular when dilated, and closes down to a narrow vertical slit with parallel sides. The refraction of the Seal presents points of great interest, as I have explained in a short paper read before the Zoological Society of London.* The eye is astigmatic, the refraction varying materially according as the eye is accommodated for air or water. This wonderful contrivance, which evidently enables these amphibious animals, the Seal and the Sea Lion, to see both on land and under water, likewise exists in the Porpoise, and to a lesser degree in the Cetacea. The Seal and the Sea Lion have a well-developed *Membrana nictitans*, but do not seem to make much use of it.

B. *Fissipedia*. (Plates 7–11.)

1. *Felidæ*.—All the *Felidæ*, viz., varieties of the domestic Cat, the Siamese and the Kaffre Cat, the Serval, Tiger Cat, Ocelot, Cheetah, Puma, and the African Lion, have that peculiar cupped disc so common to a large number of the Carnivora. The disc is round, varies in colour in the different genera, but is always surrounded by a bright-coloured fringe, mostly emerald-green. The fundus is either divided into two or three coloured zones. The central zone is usually golden yellow, the

* See 'Proc. Zool. Soc.,' 1893.

intermediate green, and the peripheral red, brown, or purple, the central zones being invariably stippled with minute dots. The distribution of the retinal vessels varies in detail, but generally three or four main branches pass diagonally from the disc to the periphery. Choroidal vessels are rarely seen; I have only found them in the red peripheral zone of the Siamese Cat. The pupils of all the Felidæ are round when fully dilated, contracting to a vertically oval slit, or in some cases even to a straight line in all the small animals; while in all the large Felidæ, viz., the Lion, Tiger, Cheetah, Puma, Ocelot, and Serval, the pupil remains round and contracts as with us. The smaller Felidæ can absolutely exclude light by the contraction of the pupil to a vertical line (all chinks being excluded by the uveal pigment), which the larger Felidæ cannot do, since round pupils cannot close entirely. Although the domestic Cat presents a general resemblance to the wild Felidæ, a difference in colour of the fundus exists in every variety that I have examined, and in many cases the coloured pigment of the peripheral zone encroaches in the form of large patches on the Tapetum lucidum.

Domestication and artificial selection evidently affect the colour of the Fundus oculi in a profound degree, and a study of the fundus of the numerous varieties of any of our domestic animals, more especially the Cat and Dog, would well repay the labour of investigation. I have likewise found that the refraction of domestic animals is not the same as that of the wild species—the tendency being always in the direction of myopia and astigmatism.

2. *The Viverridæ*.—The genera *Genetta* and *Paradoxurus* closely resemble the Felidæ, and in the *Herpestes* we have also a family likeness. The Mongoose (*Herpestes griseus*) has the peculiarity of a broad prussian-blue peripheral zone, surrounding a grass-green central area. This is the only animal in which the ophthalmoscope has revealed a prussian-blue periphery. Blue and pure purple are the rarest colours in eyes; I have found them as narrow zones in the Racoons, Jackals, and Foxes, and occasionally distributed as patches over the fundus in the domestic Cat. The Spotted Ichneumon (*Herpestes nepalensis*) has the entire fundus covered with orange patches and brown dots very dense in the peripheral zone, but spread over the entire fundus. The Tayra (*Galactis barbara*), belonging to the Mustelidæ, has similar patches over the entire fundus, whilst in the Common Otter (*Lutra vulgaris*) and in some of the Bears these orange patches are confined to the intermediate zone. I can offer no explanation to account for their presence.

The genera *Cynictis* and *Suricate* have an appearance entirely different from that of any other of the Carnivora. The colour of the fundus is dark grey, similar to that which we have seen in some of the Primates, and such as we shall find in the Suidæ. The fundus is uniform throughout; there are no zones and no Tapetum lucidum. The cupping of the disc is absent, and there are semi-opaque nerve fibres radiating from the disc, an appearance which we shall again notice in the Ungulates and Rodents. The *Cynictis* is the only Carnivore in which I have found a horizontally

oval disc similar to that of many Ungulates and certain Rodents. The disc is covered with a network of black pigment, which we shall meet with in the Cervidæ. I can offer no suggestion as to why the Suricate and Cynictis should differ so entirely from all the other Carnivora. The Cynictis and the Suricate have, moreover, the horizontally oval pupil common to the Artiodactyla. The only other Carnivores which have horizontally oval pupils are some of the Herpestes; the other Viverridæ have all vertically oval pupils like all the smaller Felidæ.

The divergence, refraction, and Membrana nictitans are the same as in the Felidæ. In one other respect again the Spotted Ichneumon (*Herpestes nepalensis*) forms an exception; in fact, it has a peculiarity which I have not found in any other Mammal, which consists in the power of rotating at will either eye outwards. This power of unilateral excursion, common to certain of the Reptiles, such as the Chameleons, must be due to a special mechanism of co-ordination, and it would be worth while investigating whether there is any variation in the optic commissure.

3. *Hyænidæ*.—All the Hyænas, viz., *H. striata*, *H. crocuta* (Spotted Hyæna), and *H. brunnea* (Brown Hyæna), resemble the Felidæ and some of the Viverridæ, having the same retinal vascularisation, and the fundus divided into three zones—the peripheral violet, the intermediate green, and the central golden yellow. The disc is brown and not cupped; the fundus is covered with minute dots as in the Felidæ. The pupils of all three species are vertically oval when the animal is at rest. As soon as it is disturbed by any noise or in any other way, the pupils instantaneously dilate to a complete circle as if the animal had its iris under control. The fact that the Hyænas are distinctly night animals may account for this dilatation of the pupil when the animal is roused. This likewise accounts for the brilliant yellow central zone which throughout the Carnivora invariably occurs in nocturnal animals, being least marked in those which prowl at dusk only.

4. *Canidæ*.—The fundus of the wild Canidæ, like that of the Felidæ, Viverridæ, and Hyænidæ, is divided into three zones—a peripheral zone of reddish or violet-brown, a green intermediate zone, and a central zone of bright golden yellow, characteristic of night animals, the Tapetum lucidum being covered with minute dots or patches. The disc is never cupped, and varies in shape in the different genera. The distribution of vessels is similar to that of the higher families, but the vessels tend upwards before spreading out, and do not always radiate directly from the disc. We shall find this distribution of vessels very marked in the Artiodactyla. The peripheral zone is, as a rule, wider than in the previous families, and in many cases includes the disc. To judge by the Fundus oculi, therefore, the Canidæ ought to be classed immediately above the Hyænidæ.

My observations bear out HÆCKEL'S contention that among the Canidæ we must in the first instance recognise two distinct groups—the Wolves and the Jackals on the one hand, and the Foxes on the other. The fundus of the Wolves, Jackals, and Foxes do not show, it is true, very marked differences. They all have the yellow

and green central zones, the periphery being brown, which is frequently bordered by a narrow purple-blue zone. The disc is never round, but varies in the different species, being triangular, lozenge-shaped, or kidney-shaped. But there is one striking difference between the Wolves and the Foxes, and that is, that all the Wolves have *round* pupils, whilst the Foxes have *oval* pupils. I have examined the Indian Wolf (*Canis pallipes*), the Prairie Wolf (*Canis latrans*), and one or two other Wolves without any marked difference in the species. The same holds good for the Black-backed Jackal (*Canis mesomelas*) and the Common Jackal (*C. aureus*).

The Common Fox (*Canis vulpes*), AZARA'S FOX (*C. Azaræ*), and the Fennec Fox (*Canes cerdo*) are also very similar, except that the shape of the disc varies somewhat. The Arctic Fox (*C. lagopus*), to my great surprise, showed no appreciable difference from other Foxes. I examined him both with his brown summer coat and in his white winter coat, but the appearance of the eye remained the same. It seems as if animals with normal seasonal albinism have not the absence of pigmentation which we find in true Albinos.

The domestic Dog, as in the case of all domestic animals, shows variations in every individual; but in no case have I found such an enormous differentiation in the colour and the appearance of the fundus as in the Dogs, the difference being very much more marked than in the domestic Cats or any of the domestic Ungulates.

I have examined a large number of different Dogs, and have come to the conclusion that they will require a monograph to themselves. HÆCKEL seems to be right in deriving the domestic Dogs from the Wolves and Jackals. In fact, all the Dogs which have come under my notice, with the sole exception of the Raccoon-like Dog (*Canis procyonides*), have the round pupils characteristic of the Wolves and Jackals in distinction to the Foxes. The Chou-Chou Dog of the Chinese is remarkable in having a brilliant orange-red fundus with a black peripheral zone covered with bluish pigment patches, a fundus unlike any of the other Carnivora.

The fundus of the Cape Hunting Dog (*Lycaon pictus*) closely resembles that of the Hyænidæ, and in this respect differs from all other Canidæ. FLOWER, in his work on the Mammalia,* draws special attention to this resemblance on other grounds. The Australian Dingo, on the other hand, seem to bear resemblance to the Wolves. The Raccoon-like Dog (*C. procyonides*) resembles both the Foxes and the Raccoon in having a vertically oval pupil, the fundus strikingly resembling that of the Raccoon.

On examining the Dogs, I again found that whilst all the wild Canidæ, as indeed all the Carnivora, are emmetropic or slightly hypermetropic, and, as a rule, free of astigmatism, the domestic animals had a tendency towards astigmatism and myopia. A few of the domestic Dogs seem able to move their eyes to a slight extent in following an object, but I did not notice any such movement among the wild Canidæ.

In the Dingo and the Raccoon-like Dog, as well as in some of the domestic Dogs, strikingly so in a St. Bernard, I met with an appearance of the fundus found common

* 'Mammals, Living and Extinct,' by W. H. FLOWER and R. LYDEKKER, London, 1891, p. 553.

to all the Mustelidæ, Procyonidæ, and Ursidæ. This appearance is best compared to very coarse crystalline sugar, showing coloured facets densely spread over the peripheral area, encroaching more or less into the Tapetum lucidum. All the animals which have this peculiar crystalline appearance of the fundus have a lens showing distinct concentric rings, which alter the refraction in such a manner that the periphery of the fundus cannot be clearly seen. It may be that the crystalline appearance of the pigment observable with the ophthalmoscope is due to the difference in refraction of the various parts of the lens. The crystalline appearance of the pigment occurs only in the Carnivora from the Canidæ downwards, but the concentric rings noticeable in the lens of these animals likewise occur in the Insectivora, Rodents, Edentata, and in some of the Marsupials.

5. *Mustelidæ*.—All the Mustelidæ have round discs; in some it is cup-shaped, the vessels arising at the margin of the disc and curling over it as in the Felidæ, whilst in others they radiate from the central stem. The Canadian Skunk (*Mephitis mephitis*) has a pure white disc in which no trace of vessels can be seen. The colour of the fundus varies in different members of this family. The Polecat (*Mustela putorius*) resembles that of the Jackals, and so does the Cape Zorilla (*Ictonyx zorilla*). In the Common Otter (*Lutra vulgaris*) the intermediate green zone is strewn over with orange patches similar to those of the Spotted Ichneumon, and this is again a feature in the Tayra (*Galictis barbara*). The Pine-Marten (*M. foina*) has a reddish-brown peripheral zone, and patches of a similar reddish-brown cover the green intermediate zone, whilst the central yellow zone is covered with similarly coloured dots. The Sand Badger (*Meles ankuma*) bears little resemblance to the other Mustelidæ, having a whitish straw-like fundus covered with green dots, the peripheral zone being bright vermilion. But for the more prolific vascularisation it might be taken for that of one of the Felidæ, resembling somewhat the Siamese Cat.

The Canadian Skunk (*Mephitis mephitis*) differs entirely from any of the other Carnivora. The disc is white and cup-shaped without any trace of vessels, whilst six branches arise at the extreme edge of the disc. Opaque nerve fibres radiate from the disc as they do in the Suricate and the Cynictis, forming exceptions to all the other Carnivores. The fundus is of a pale canary-yellow, changing to a dirty mottled drab near the lower margin of the disc. The Tapetum lucidum in this animal is of a much less decided character than in the other Carnivores. But for some differences in the vascularisation, the fundus of the Skunk resembles that of the Flying Squirrels, more particularly *Pteromys magnificus*. Besides this resemblance to one of the Rodents, the Canadian Skunk has several other points in common with that lower order. The eyes protrude beyond the hemisphere; there is no Membrana nictitans, and the refraction shows a high degree of hypermetropia (viz., 5 D), all of which peculiarities are common in the Rodents.

6. *Procyonidæ*.—The American Raccoon (*P. lotor*) has points of resemblance with the Mustelidæ as well as with the Bears. The fundus of the Bassaricyon (*B. alleni*)

resembles that of the Cape Hunting Dog and the Hyænas, except that the violet peripheral and intermediate green zones are considerably lighter in colour. The Kinkajou (*Cercoleptes caudivolvulus*) has a red peripheral zone with a yellowish-green tapetum, with yellow and green dots and streaks and a cup-shaped disc, thus somewhat resembling the Sand Badger. The Ringtailed Coati (*Nasua rufa*) has a brown peripheral area and a bright green tapetum with yellowish patches, an appearance common to all the Bears. The disc is round in all the Procyonidæ, with the exception of the Racoon. The Membrana nictitans of the latter is vestigial as in ourselves, whilst in the Kinkajou it is well developed, and forms with the conjunctiva a sort of loose bag which contracts over the cornea; an arrangement which we shall find in some of the other animals, which, like the Kinkajou, have the power of withdrawing their eyes into the socket. This is still more marked in the Bears and common to a number of the lower Mammals. The Coati, like the Bears, has a Membrana nictitans, which it only uses when sleepy. The resemblance of the Racoon to the Polecat and of the Coati to the Bears, as well as the fact that all through the Mustelidæ, Procyonidæ, and Ursidæ we find the crystalline appearance of the pigment in the fundus, and the concentric arrangement of the lens fibres already referred to, shows that, with the exception of the Canadian Skunk, the classification according to the eye agrees with that of GADOW which I am following.

7. *Ursidæ*.—The Syrian (*Ursus syriacus*), the Black (*Ursus americanus*), the Malay (*U. malayanus*), and the Sloth Bear (*Ursinus malurus*) have practically the same fundus; a central area covered with yellow patches and a purple or purple-brown densely-pigmented peripheral area. In the Black Bear and the Sloth Bear, orange pigment is distributed on the border line between the two zones, and in the Malay Bear the peripheral pigment extends into the green in the form of light purple patches. The discs are all round and more or less cupped. The pupils are round in all except *Ursus americanus*, in which it is vertically oval, dilating to a full circle. The Bears have a Membrana nictitans which only comes forward when they are sleepy. *Ursinus malurus* rolls its eyes constantly backwards and outwards with an extremely rapid movement every few seconds, withdrawing them at the same time into the sockets in the same way as the Rhinoceros does. This movement enables the animal to sweep the horizon without moving its head.

V. UNGULATA. (Plates 12–17.)

In examining the Ungulates, I was greatly struck by the fact that, according to the Fundus oculi, they can be classed into two large divisions. The Artiodactyla, which form the first section, have numerous large retinal vessels, whilst the other Ungulata have either a few fine vessels restricted to the vicinity of the disc, or a fundus devoid of all trace of retinal vessels.

The pupil is horizontally oval, except in the Elephant, Tapir, and Rhinoceros, where

it is circular. The iris is hardly sensitive to mydriatics, but contracts well to strong light. As a rule the iris shows two distinct layers, a number of Ungulates having either pigmented excrescences on the border of the iris, or a special development of tissue from the superficial layer. In either case the object is to shield the very large pupil against glare. In the Hyracidæ it is developed into a special organ (see pages 27, 57, and 59, and also Plate 29). As regards refraction I could detect no myopia; nearly all the animals I examined were emmetropic or slightly hypermetropic, all being more or less astigmatic. All Ungulates have a nictitating membrane, but the extent of movement and the degree to which it is used vary greatly.

Although as a general rule the Ungulates are possessed of a Tapetum lucidum, this is not invariably the case. As far as can be judged with the ophthalmoscope the Camelidæ have not got a tapetum, and I have been able to convince myself by anatomical as well as ophthalmoscopic examination that the Suidæ do not possess one either. The Suidæ have a transparent choroid similar to our own, and this seems to be also the case in the Camelidæ. If we regard the Tapetum lucidum as an opacity of the choroid both with and without structural colour, then no doubt Rhinoceros, Elephas, and Hyrax are possessed of a tapetum, but the dull appearance of the fundus forms a striking contrast to the brilliant hues found in the other Ungulates. Moreover, those Ungulates which have a characteristic Tapetum lucidum have also a Tapetum nigrum, or at least a densely pigmented peripheral zone, while the Rhinoceros, the Elephants, and Hyrax show no such differentiation. In order to see exactly where the difference lies, the examination of freshly enucleated eyes is necessary.

A. *Artiodactyla*.

Throughout this sub-order the eye is comparatively very large, the pupil is horizontally oval, and the retina has an elaborate and highly developed vascular supply.

(a) *Selenodonta (Ruminants)*.

The highest Ruminants show some resemblances in colour to the Carnivora, but the shape of the disc and the vascularisation of the retina are distinctly peculiar. First, with the exception of some domestic animals, it will be observed the disc is horizontally oval, whilst in all cases the vessels are highly developed and of large calibre. Secondly, the whole of the fundus above the disc is supplied entirely by a single very large and prominent trunk, which runs vertically upwards. From this, horizontal branches run outwards at regular intervals, giving off fine branches which pass downwards, parallel to the parent trunk. The Goats alone form an exception, the branches spreading obliquely from the main trunk. This peculiarity of the vascularisation forms a marked distinction between the Goats and the Sheep. Fine capillaries supply a specially sensitive area, which forms a broad horizontal

streak just above the disc. From the two main trunks, which pass obliquely downwards from the disc, minute vessels and capillaries ascend to reach this special area from below. By this arrangement of vessels the sensitive area is practically unobscured. The Selenodonta, with the exception of the Camelidæ, have a well-marked Tapetum lucidum and Tapetum nigrum.

1. *Bovidæ*.—The fundus is divided into three zones similar to what we have found in the Carnivora—a peripheral purple-brown zone with gaps showing the underlying green, which is the predominant colour over the rest of the fundus; an intermediate zone which is yellow, spotted with green dots all over, and a central area distinctly yellow. This is the case in the Zebu or Indian Ox (*Bos Indicus*), in the British Wild Ox (*Bos taurus*), and also, generally speaking, in the domestic Cow, although here, as in all cases of domesticity, considerable variations occur in different individuals. The Sheep (*Ovis*) closely resembles the Ox as far as the vessels and the disc are concerned, the only difference being the colour of the fundus, which is of a pale slaty-green with tiny orange stellate dots. The peripheral zone is purple-brown as in the Ox, only more mossy, but without the gaps of green. These mossy pigment patches extend over the fundus to a greater degree in old than in young animals; in some cases they may even be found scattered over the entire central area.

The Goats (*Capra*) differ somewhat from the Ox and Sheep. The peripheral zone is very much the same, although it encroaches more on the central zone, resembling in that respect some of the Cervidæ. The wild Goat differs in colour from the domestic Goat, the wild animal having a pale greenish-blue fundus, while the domestic Goat varies with every individual, being often of a bright lavender colour. Instead of the minute dots, which are scattered over the fundus in the Ox and Sheep, the Goat has large bright orange spots surrounded by a yellow border which all appear joined to each other by minute processes. In many cases in both Sheep and Goats the pigment towards the Ora serrata, which partially determines the colour of the fundus in the Ungulates, ceases entirely, not in a regular manner, but showing an uneven rugged edge, so that near the margin of the visual field we obtain an unobscured view of the underlying structurally coloured opaque choroid, which appears as a bright greenish-blue sheen, like mother-of-pearl, devoid of all traces of pigment. (Compare the chapter on the nature of the Tapetum lucidum of the Ungulates, page 40.)

2. *Cervidæ*.—The colour of the fundus of the Cervidæ is similar to that of the Bovidæ, and they have the distribution of vessels characteristic of the Ruminants. The disc, however, is very peculiar. Its shape is, roughly speaking, horizontally oval, but much more extended laterally in proportion to its width than in any other group of animals, except certain of the Rodents. In the Hog Deer (*Cervus porcinus*) it appears to consist of three separate discs placed side by side and fused together, each having its main artery and vein springing from the centre. The

colour is pink, and covered with a coarse pigment network as in *Cynictis*. The disc of the Reindeer (*Rangifer tarandus*) follows much the same plan, but the pigment network is less marked. Opaque nerve fibres radiate brush-like from the ends and top of the disc. The Dorcas Gazelle (*Gazella dorcas*) has a long oval simple disc covered with pigment network, but the opaque nerve fibres are less marked. The retinal vessels arise from three sources as in the Hog Deer, the two lateral trunks spread irregularly over the pigment zone below the disc, while the great main arterial trunk ascends vertically through the green zone, and is distributed in the characteristic way.

In all the Cervidæ examined I have noticed a white fibrous band, extending from the central trunk at its entrance in the disc to the posterior capsule of the lens (fig. 1, *a* and *b*, Plate 28). This phylogenetically important organ will be discussed in the chapter dealing with vestigial relics and congenital defects (see p. 53).

3. *Camelidæ*.—An examination of several species of the Dromedary (*Camelus dromedarius*), the Bactrian Camel (*Camelus bactrianus*), and the Llama (*Llama peruviana*) showed no essential individual differences, the Dromedary being practically indistinguishable with the Camel. None of the Camelidæ have any peripheral zone, the fundus being of a uniform colour. These are also the only Ungulates in which any choroidal vessels can be seen—a feature peculiar to red or brownish-red fundi. The Camel has a brownish-red fundus slightly stippled with dark grey dots everywhere. The disc is round, depressed below the surrounding level, and the arteries and veins, which are both of a bright scarlet, are arranged in the way we noticed in all the other Ruminants. Opaque nerve fibres radiate horizontally and downwards from the disc, while a broad zone, free from blood-vessels, with opaque nerve fibres and stippling, extends as a horizontal streak immediately above the disc. The Llama has a very large slightly oval disc, but the distribution of vessels is the same as in the Camel. The fundus is of a brilliant magenta, covered with deep red choroidal vessels and stippled everywhere below the disc with dark red dots. There are no opaque nerve fibres, but the special sensitive area immediately above the disc forms a horizontal band nearly devoid of blood vessels, as in the Camel. As already observed, the Camelidæ have no Tapetum lucidum.

4. *Tragulidæ*. Chevrotain (*Tragulus javanicus*).—The disc and the distribution of the vessels in this animal closely resemble those of the Cervidæ, except that the disc is still more densely pigmented and perfectly oval, and the vessels all arise from the centre of the disc. The fundus above the disc is a pale yellow-green, dotted everywhere at regular intervals with large stellate brown dots. The peripheral zone consists of an agglomeration of violet-brown pigment spots, giving it a mossy appearance. There are no opaque nerve fibres, but there is a well-marked, bloodless, sensitive area.

The Chevrotain possesses a peculiarity otherwise met with in the Leporidæ only, viz., that the retinal vessels stand out above the surface of the retina in such a manner as to cast broad shadows on to the brilliant green background. To focus

these vessels sharply, I required a difference of four dioptries as compared with the dots on the background, thus indicating a difference of level of 1.25 millimetres.

(b) *Bunodonta*.

1. *Hippopotamida*.—The only Hippopotamus which allowed me to approach him sufficiently near for examination suffered from opacities of the cornea. I could, however, discern retinal blood vessels, and the fundus seemed of uniform colour. The orbit forms an exceedingly prominent tubercle on a level with the ear. The eyes are very far apart, forming parallel lines with the ears. The range of vision of the eyes is extensive owing to their turret-like position, which stand above the water when the whole of its body, except the back and the head, is submerged. The eye is surrounded by a wide area of pink, unpigmented skin. The eyelids form a complete fleshy ring round the eye instead of two separate lids. The sclerotic is of a pale grey-pink colour. The pupil is very small horizontally, pointed oval, and contracts with light to a horizontal slit. Only traces of eyelashes are present. The nictitans is well developed and lies in loose folds, but it never extends beyond halfway across the eye. The animal cleans its eye by bringing both lids together over the globe, which at the same time retracts into the orbit, but never moves the eye upwards and outwards as does the Rhinoceros.

2. *Suida*.—The Pigs differ entirely from the Ruminants, resembling rather the Suricate and the Cynictis. The general colour of the fundus of the Wild Boar is a purplish-grey, coarsely stippled, a colour only met with in some of the Monkeys and the above-named Carnivora. The disc is large and horizontally oval, and a number of arteries and veins radiate from its centre. The veins are exceptionally large, being five or six times that of the corresponding arteries. Innumerable opaque nerve fibres radiate from the disc. There are no zones, the colour being the same all over the fundus, nor is there any tapetum or any differentiated area devoid of blood-vessels.

B. *Perissodactyla*.

The Perissodactyla have fundi devoid of retinal vessels. The Rhinoceros shows a much more primitive fundus than the other Perissodactyla, more so than either Tapirus or Equus, and even Elephas and Hyrax.

1. *Rhinocerotida*.—There is absolutely nothing to be seen in the fundus of the Rhinoceros but a large circular white disc in the centre of a violet-brown field covered with a faint network of coarse stippling.

The Rhinoceroses have small bright twinkling eyes. This "twinkle" is due to a rapid oblique movement of the eye outwards and slightly upwards, a movement which the animal performs every few seconds. This occurred in all the species examined. This movement may be for the purpose of protection, to enable them to look around without the trouble of turning their large, massive heads. It also seems in some

measure to replace our "winking." The eye is placed so as to have an uninterrupted view forwards and laterally. The skin round the eye forms large irregular folds, the outermost being about 5 inches across. The two lower folds form a right angle, while the upper fold forms a portion of a circle.

The pupil is round, 9 millimetres in diameter, surrounded by a dark brown iris. The cornea, on the other hand, is not round, but formed of two intersecting arcs of circles nearly corresponding to the angles at the canthi. A well-formed nictitans is present, but although it is freely moved half across the eye, especially when the animal gets sleepy, it never flashes across the whole eye as in the Horse.

2. *Equidæ*.—The Horse, BURCHELL'S Zebra, and the Wild Ass (*Equus taniopus*) have a fundus divided into two zones. The peripheral zone is violet-brown and densely pigmented, as we have seen in the Bovidæ, Cervidæ, and Tragulidæ; the central zone, which lies immediately above the disc, is entirely stippled with purple-brown stellate dots on a coloured ground. In the Horse and Zebra, the groundwork is a mixture of yellow and green, whilst in the Wild Ass it is a mixture of yellow and bluish-green. The disc is oval and pink, and numerous fine capillaries can be seen at the edge of the disc and only traceable for a short distance. Opaque nerve fibres are also present. The Horse closely resembles the Zebra, except that the colour of the fundus varies individually, its typical colour being olive-green with a dark brown circumferential zone. All the Equidæ have a well-developed Membrana nictitans, which they use freely. The pigmented prominences at the edge of the iris, known as the Corpus nigrum, are more highly developed in the wild animals than in the tame ones.

3. *Tapiridæ*.—The Brazilian Tapir (*Tapirus americanus*), being a night animal, has a bright golden-yellow fundus stippled with orange-red dots and with an orange-red peripheral zone. There are only a few tiny blood-vessels, which are restricted to the edge of the circular chalky-white disc.

C. *Proboscidæ*.

1. *Elephantidæ*.—Both the Indian and African Elephants have a yellow-ochre fundus marked with more or less bacillus-like brown patches, which markings are much more prominent and numerous in older than in younger animals.

The disc is round and of a greyish-white colour. A few capillaries can be traced over the edge from the central depression. The pupil is circular, and the pink fleshy nictitans, although well developed, is used but little.

D. *Hyracoidæ*.

The fundi of both *Hyrax dorsalis* and *H. capensis* are practically alike and resemble those of the Elephants. The fundus, which is a pale reddish-brown, is only lightly stippled, and shows a few traces of choroidal vessels. The disc is pale pink,

and has a few minute vessels which radiate from near the centre, and in some cases a short way over the fundus.

The Hyrax has a peculiar contrivance, which consists of a small spade-like prolongation of the external (superficial) layer of the iris, which has its origin about 2 millimetres above the pupillary margin. This special organ, which I propose to term the *Umbraculum*, and which is pictured on Plate 29, is highly contractile, and its surface is inclined away from the rest of the iris in an oblique direction forwards and downwards towards the cornea, which it almost touches when fully extended. At each side of the insertion of the umbraculum is a horizontal slit in the iris proper, which is evidently necessary in order to allow of its complete contraction out of the way of the pupil. Strong light causes the animal to extend this umbraculum, and at the same time to partly close the pupil, the object being evidently the same as when we screen our eyes with our hand when facing the sun. We can assume by analogy that the prolongation of the iris found in a number of the Ungulates, including the pigmentary excrescences known in the Horse as the "Corpus nigrum," serve a like purpose. The Corpus nigrum, however, differs from all the other iridic prolongations in being a simple hypertrophy of the internal or pigment layer of the iris, the iris fibres themselves not entering into it. (See Plate 29.)

VI. SIRENIA. VII. CETACEA.

Ophthalmoscopic examination was restricted to the eyes of a Porpoise about an hour after death. The general background was then of a bluish-slate colour. The disc is comparatively small; the arteries and veins, each seven in number, radiate from it at regular intervals, the arteries dividing dichotomously, but not the veins. The skin encroaches over the eyeball so as to cover it all but the cornea, giving the appearance of a buttonhole punched out of the skin and the globe being pushed against it from behind. There are consequently no eyelids, and eyelashes are absent, and there is no trace of a nictitating membrane. The cornea is flattened in a horizontal plane, as in the Seal, and indicates a similar high degree of astigmatism. No doubt the Cetaceans have a similar contrivance to the Seal, enabling them to see both in air and water; in fact I found, as in the Seal, an extremely thick lens having an anterior spherical and a posterior parabolic surface, with a very highly developed ciliary muscle.

VIII. RODENTIA. (Plates 17-22.)

With the exception of the red and white Flying Squirrel (*Pteromys magnificus*), the fundus of which bears some resemblance to that of the Skunk, and the Spotted Cavy (*Cælogenys paca*), which latter has a fundus not unlike that of the Tapir, the Rodents show no sign of a Tapetum lucidum. They all have fundi which are uniform in colour, showing various degrees of transparency. The vascularisation differs

enormously in the various sub-orders, ranging from complete absence to the most prolific distribution of vessels. The disc likewise shows a wide range of differentiation, comprising both the largest as well as the smallest disc found in any class of Mammals. In fact, there is a greater variety of type in this order than in any other.

Throughout the Rodents the pupil is circular both when dilated and contracted, the only exceptions being the Marmots, the Ground Squirrel, the Coipu and Capybara, which have a slightly oval pupil. All the wild Rodents show a marked degree of hypermetropia, which, however, tends to disappear in captivity. This explains why those who have examined domestic Rabbits and Guinea-pigs have recorded such varied results. The domestic Rabbits exhibit all degrees of refraction and astigmatism, whereas the common wild Hare (*Lepus europæus*) has a considerable degree of hypermetropia. All Rodents have the power of retracting the eye into the orbit, the lids closing as the eye is withdrawn into the socket. The nictitating membrane is in all rudimentary, as in Man. The cornea is a perfect hemisphere, and extends in most cases to the equator of the globe.

The crystalline lens in the great majority of the Rodents appears to be made up of concentric circles when viewed through the ophthalmoscope, which renders it very difficult to examine the details of the fundus. The ophthalmoscopic appearance of the fundus confirms the view now held by HÆCKEL, GADOW, and others, that the Rodents must be placed very low down among the Placentalia.

A. *Myomorpha*.

The fundus in this sub-order is red or greyish-pink, except in the Black Rat (*Mus rattus*), in which it is whitish-grey, the Albino variety having a pure white fundus. The disc is usually very small, and the vascularisation prolific and symmetrical, the veins and arteries radiating at regular intervals from the central trunk, like the rays of a Starfish. Opaque nerve fibres are invariably seen around the disc. The pupil is round and contracts to a pin's head.

In all the members of the Myoxidæ a peculiar white cord is seen passing from the centre of the disc close to the main vascular trunk, through the vitreous body as far as the posterior capsule of the lens, near which it may be seen to bifurcate, each terminal being apparently inserted into the margin of the lens capsule. Sometimes this cord is seen to be highly pigmented at its origin, the pigment being spread out over the area which corresponds to the disc, but I could not be sure whether the cord arose from the disc itself or from the main trunk of the central vessels. This cord, running from the disc to the lens, is similar in appearance to that in the Cervidæ; besides this cord, I have often noticed a short, blind, sausage-shaped artery projecting into the vitreous as a bud from the main trunk, and which often may be seen pulsating. Perhaps this should be considered as the obliterated hyaline artery, but it is quite distinct from the above-mentioned cord, and sometimes the two may be seen side by side.

1. *Dipodidæ*.—The Egyptian Jerboa (*Dipus ægyptius*) and the Indian Jerboa (*Alactaya indica*) have all the characteristics we have just described common to all the Myomorpha, a pink or brownish-grey fundus and ill-defined disc, from the centre of which retinal vessels branch out in all directions. At their origin the retinal vessels come forward so as to form a raised double arch standing out above the disc. Around the disc opaque nerve fibres radiate, and the choroidal vessels are more or less visible. The cord which runs from the disc to the lens is densely pigmented at its origin (fig. 3, *a* and *b*, Plate 28).

2. *Geomyidæ*.—The Cape Pouched Rat (*Saccostomus campestris*) and the American variety (*Geomys americanus*) closely resemble each other, and present an appearance partaking of the characters of the Dipodidæ and the Muridæ, thus confirming GADOW'S classification.

3. *Muridæ*.—The fundus of the Muridæ resembles that of the Dipodidæ, except that the disc is reduced to a mere point and obscured by the central trunk, giving the appearance as if the arteria centralis retinæ was hardly surrounded by any nerve tissue. The optic nerve of these animals which I have examined after enucleation is scarcely the size of a cotton thread. The main vessels radiate in straight lines at regular intervals without bifurcating, giving the vascularisation a star-shaped appearance, a point in which they differ markedly from the Dipodidæ, in which the vessels each divide into two or three branches close to the disc.

The Black Rat has a light grey fundus, in which no trace of choroidal vessels can be seen, whilst the Albino variety of the same species has a perfectly white fundus, on which choroidal vessels can be seen as worm-like streaks.

4. *Myoxidæ*.—The two Dormice differ considerably. The Oak Dormouse (*Myoxus dryas*) resembles the Muridæ, except that some choroidal vessels can be seen as long red streaks in the background, whilst the Garden Dormouse (*Myoxus quercinus*) has a larger disc, and the fundus is entirely covered with a dense network of thick choroidal vessels, which cause it to resemble the Chinchillidæ but for the characteristic vascularisation common to all the Myomorpha.

B. *Sciuromorpha*.

The Sciuromorpha present great varieties, and include some of the most curious appearances to be found in any animal. The first point which strikes one is that the American Beaver (*Castor canadensis*) does not in any way resemble the other Sciuromorpha with which it is usually classed, but has a fundus resembling that of the Viscacha, the Chinchilla, and, more still, the Hydrochærus Capybara.

The next point is the great difference which the Flying Squirrels (*Pteromys* and *Sciuropterus*) present as compared with the other Sciuridæ, which again differ materially from one another both as regards the shape of the disc and the vascularisation of the retina.

The lens of the Squirrels is nearly spherical and the pupil invariably round.

1. *Castoridae*.—Judging from the appearance of the fundus alone, the Beavers should be placed between the Chinchillidæ and the Cavidæ. In the Canadian Beaver (*Castor canadensis*) the disc is circular and white, having a deeply pigmented papillary projection in its centre (fig. 8, Plate 28). Around the latter two or three minute capillaries can be seen, but otherwise all retinal blood vessels are absent. The fundus is pale brownish-red, and entirely covered with a network of choroidal vessels. No opaque nerve fibres are present. The eyes, moreover, are remarkably small considering the size of the animal. The similarity between the Castor and the Viscacha and Capybara is very striking.

2. *Sciuridae*.—The Flying Squirrels differ entirely from the true Squirrels and Marmots.

Pteromys magnificus somewhat resembles the Skunk in the colour of the two zones. The fundus is golden-yellow covered with brown stellate dots, similar in appearance to those found in the Galagos. The disc is white and depressed, so that the fundus might be taken for that of a Carnivore were it not that the abundant vascularisation reminds one of that of some of the Rodents. *Sciuropterus volucella* has a similarly depressed white disc, but the fundus is uniformly deep scarlet, covered with small black streaks, there being evidently no Tapetum lucidum, not even of a primitive kind, as innumerable choroidal vessels are to be seen.

The Marmots (*Arctomys Marmotta* and *Synomys ludovicianus*) and the Squirrels, other than those above mentioned, such as *Sciurus ludovicianus*, *Sciurus variegatus*, and *S. vulgaris*, have an elongated disc which extends as a narrow band, club-shaped at the ends, across the field, occupying in the Marmots about one-half of the entire retina. This long disc is both relatively and absolutely of a greater area than that of any other animal I have examined. The disc of the Marmots and some of the Squirrels have quite four times the area of the disc of an adult Elephant. From this long narrow disc the retinal vessels run upwards and downwards as broad red parallel lines, a few vessels radiating from the club-shaped ends of the disc, giving the entire vascular arrangements the appearance of a centipede. The disc is white and depressed below the fundus, so that the vessels curl over the edge. Innumerable opaque nerve fibres run parallel to the retinal vessels, like the teeth of a fine comb. The general colour of the fundus is pink, with a tint of grey due to the opaque nerve fibres. The disc is always above the visual axis, and in several cases I noticed in the axis of vision a portion of the fundus free of retinal vessels. In the Ground Squirrel (*Xerus setosus*) the entire portion of the fundus above the disc is very dark and with very little reflex, so that few details can be discerned. The Indian Palm Squirrel (*Sciurus palmarum*) seems to stand midway between the Flying Squirrels and the true Squirrels. The colour of the fundus is the same as that of the true Squirrels—a pale pink, rendered grey by innumerable opaque nerve fibres, choroidal vessels being visible as in all. The disc is circular and cup-shaped, both the disc and the vascularisation

resembling that of the Flying Squirrels. From the centre of the disc a white cord runs forward towards the lens (fig. 9, Plate 28).

C. *Hystricomorpha*.

The fundus of the Hystricomorpha shows no retinal vessels, but in most cases a number of fine capillaries emanating from the arteria centralis retinae can be seen in the disc, which is always round and white and nearly as large as that of Man. In most animals of this sub-order other than the Hystricidæ (Porcupines) a pecten-like prominence, consisting of blood-vessels and pigment cells, can be seen protruding from the centre of the disc into the vitreous.

The Hystricomorpha, with the exception of the Porcupines (Hystricidæ), have strikingly prominent choroidal vessels, and their fundus resembles that of the Marsupials. In the Hystricidæ, on the other hand, the choroidal vessels cannot be clearly seen, the fundus bearing a striking likeness to that of the Edentata.

1. *Chinchillidæ*.—Chinchilla (*Chinchilla lanigera*) and the Viscacha (*Lagostomus trichodactylus*) show only a small trace of a "pecten" in the centre of a round white disc, in which a few capillaries can be seen. The fundus is devoid of retinal vessels, but exhibits a dense network of prominent choroidal vessels on a buff or slaty-grey background. The disc is chalky-white, with some fine capillaries emanating from the centre, but only to its margin.

2. *Cavidæ*.—The Common Guinea-pig (*Cavia porcellus*) has a fundus similar to that of the Chinchillidæ, except that the opaque nerve fibres in the vicinity of the disc are more marked. I could not see any opaque nerve fibres in *Chinchilla lanigera*, although I saw some in the Viscacha (*Lagostomus trichodactylus*). Differences are to be found in the numerous varieties of Guinea-pigs, as they are domestic animals, although in so primitive an eye the differences are not so marked as in domestic animals of the higher orders. The Capybara (*Hydrochærus capybara*) has a fundus resembling that of the Chinchillidæ and, as already remarked, it resembles also that of the Canadian Beaver. The resemblance which the Chinchillidæ, the Castoridæ, and these Cavidæ bear to the Marsupials is very marked, and we shall find this to be still more the case with the Dasyproctidæ. The Spotted Cavy (*Cælogenys paca*), however, differs materially from all the other Hystricomorpha, having a fundus in which no choroidal vessels can be seen, but two distinct zones—one golden-yellow in the centre, the other red peripherally—point to the existence of a Tapetum lucidum.

3. *Octodontidæ*.—*Myopotamus Coypu* has an exceedingly primitive fundus, of a type intermediate between that of the Hystricidæ and the Dasyproctidæ. In the centre of the disc is a basket-like vascular protuberance similar to that of the *Perameles lagotis*. (See fig. 15, Plate 28.)

4. *Dasyproctidæ*.—The Agoutis are particularly interesting, all having the pecten-like vascular protuberance, which is more developed and characteristic than in any of

the other Hystricomorpha (figs. 18, 19, 20, Plate 28). The disc of the various species is round with minute arteries; opaque nerve fibres are more or less marked, and the fundus entirely covered with choroidal vessels on a grey-black or buff ground. The Golden Agouti (*Dasyprocta agouti*) has such a dense network of fine choroidal vessels that it gives the fundus a red appearance, whilst in AZARA'S Agouti (*Dasyprocta Azaræ*) we find a grey fundus with the choroidal vessels much less marked. The resemblance between the Rodents and the Marsupials is most apparent in the Dasyproctidæ.

5. *Hystricidæ*.—The Porcupines have a fundus devoid of retinal vessels, and a round disc, which is white in the Hairy Porcupine (*Sphingurus villosus*), and bluish-grey in the Brazilian Porcupine (*Sphingurus prehensilis*). The latter has a vermilion fundus, with orange streaks, probably obscured choroidal vessels, whilst the Hairy Porcupine (*Sphingurus villosus*) has a vermilion fundus covered with large lake-coloured dots, no choroidal vessels being visible. Neither of these Porcupines show any trace of capillaries in the disc, nor any trace of a "pecten," the disc being entirely uniform as in the Edentata.

D. *Lagomorpha*.

Leporida.—The Rabbits have a deep vermilion-red fundus, and the Hares an almost lake-coloured fundus, but in other respects they are similar. A round-oval white disc is to be seen considerably above the visual axis. From this disc large retinal vessels branch out right and left in a horizontal plane, and the area they occupy is covered by bundles of completely opaque nerve fibres, forming a pair of broad white feather-like streaks, which part at the disc. The fact that all the retinal vessels run entirely in these bundles, which are all above the line of vision, points to an admirable contrivance of nature by which their inherent opacity affords no obstacle to the animal's vision.

In the lighter-coloured Rabbits choroidal vessels can be seen. In the Albinos, the dense choroidal vascularisation is visible, as also the places where the vessels enter the choroid through the sclerotic.

The Leporidæ, judging from the eye alone, ought to be placed between the Sciuromorpha and the Hystricomorpha, as the eye is no doubt less developed than that of the Squirrels, whilst the presence of retinal vessels shows it to be of a higher type than that of the Hystricomorpha, which resemble the Marsupials in all families except the Porcupines, which approach the Edentata.

IX. EDENTATA. (Plate 23.)

The fundus of the Edentata is of the most rudimentary kind. But for some hardly perceptible stippling the fundus is uniform in colour, a large round white disc being all that can be discerned. In some animals a few minute capillaries occur

near the centre of the disc. It was exceedingly difficult to examine that of the Edentata, as evidently their sensitive area lies in close proximity to it. Whenever the light from the ophthalmoscope was focussed on the nasal side of the disc the animals winced and closed their lids, and their distress was evident. I noticed the same effect when examining the Echidna's eye. In the Edentata, as in the Porcupines, the pupil is exceedingly small, dilating markedly under atropine. The Edentata are able to retract their eyes much more than the Rodents, the retraction being, however, apparently less due to the action of the choanoid muscle than to the pressure exerted by the lids. These appear to push the eye back, as the retraction does not take place when the lids are forcibly held open and the cornea is irritated with a brush. At the same time that the eye is pushed back into the socket the globe rotates backwards towards the petrous bone.

1. *Dasypodidæ*.—The Hairy Armadillo (*Dasypus villosus*) has a uniform reddish-brown fundus with a round chalky-white disc, in which no trace of vessels can be seen. The disc is situated above and slightly posterior to the axis. There is a dark grey spot in the centre of the disc, but I could not determine whether it was the shadow of a pit or a pigmented protuberance, since the unequal refraction of the lens common to all these primitive Mammals makes it exceedingly difficult to ascertain details. The eyelids are well formed. The animal winks every few seconds, the eye receding each time, while the lids bend inwards in the direction of the apex of the socket, instead of the upper lid sliding down over the eye as in ourselves. The lower lid is very small, highly pigmented with black, and covered with vertical and horizontal creases. This movement of the eye also exists in the Echidna. There is no trace of a nictitating membrane.

2. *Myrmecophagidæ*.—Great Anteater (*Myrmecophaga jubata*). The fundus closely resembles that of the Armadillo, being of a brownish-red tint, uniform all over, except for a faint streaky mottling. Around the centre of the chalk-white round disc seven minute capillaries can be seen. The disc is two disc breadths above and slightly behind the axis. The rhythmic retraction and rolling of the eye is the same as in the Armadillo, but, strange to say, this animal has a well-developed nictitating membrane. The pupil is round, diameter 3 millimetres, dilating to 6 millimetres under atropine.

3. *Bradypodidæ*.—The three-toed Sloth (*Bradypus tridactylus*) has a fundus closely resembling that of the Armadillo. No trace of vessels can be seen. The nictitating membrane is wanting.

X. MARSUPIALIA. (Plates 23-26.)

All the Marsupials which I have examined, with the exception of the carnivorous and nocturnal Tasmanian Devil (*Dasyurus ursinus*) and the Virginian Opossum (*Didelphys virginiana*), show a complete absence of retinal vessels, whilst with the sole exception of the Squirrel-like Phalanger (*Belideus sciureus*) and the Black

Phalanger (*Phalangista vulgaris*) the choroidal vessels were in all cases very prominent, standing out as vermilion streaks on a brown or grey, and frequently almost black, background. With the exception of the two above-mentioned Phalangiers, the Diprotodontia closely resemble the Hystricomorpha, excepting the Hystricidæ (Porcupines). In the Diprotodontia we find the vestigial pecten—the sauropsidan vestigial relic noticed in the Hystricomorpha, and particularly in the Dasyproctidæ. The only other Marsupial in which I have found such a pecten was the Rabbit-eared Perameles (*Perameles lagotis*). All the Marsupials have circular discs, and in most cases the disc is covered with fine capillaries or a fine vascular network, which projects like a dome-shaped cushion above it. In almost every instance, opaque nerve fibres radiate from the disc as in the Rodents. All Marsupials have circular pupils and an active Membrana nictitans, whilst the Didelphyidæ have eyes resembling those of the Carnivores, and therefore eyes much higher in development than any of the other Marsupials and any of the Rodents; the Peramelidæ seem to me to possess the lowest type of eye among the Marsupials, so that it is difficult to make a comparison between the Diprotodontia and the Polyprotodontia. Classed according to their eyes only, the Didelphyidæ, and possibly also the Dasyuridæ, would form a separate sub-order, highest among the Marsupials.

A. *Diprotodontia*.

1. *Phascolomyidæ*.—The Wombat (*Phascolomys Wombat*) has the characteristic fundus of the Diprotodontia above described. The eyes are small, the pupils are large and circular; the nictitans is well developed and advances very slowly, about a third across the cornea. Its only use appears to be to protect the eye from light and injury, and not to clear the cornea from dust, &c., as the cornea is insensible to touch. The light from the ophthalmoscope had an immediate hypnotic effect on the animal, so that it was necessary to awaken it every few minutes.

2. *Macropodidæ*.—The fundus of the Kangaroos bears a striking resemblance to that of the Agoutis. It is devoid of retinal vessels, grey-brown in colour, with numerous prominent choroidal vessels. The circular disc is covered with a vascular network in the Short-tailed Wallaby (*Halmaturus brachyurus*), BENNET'S Tree Kangaroo (*Dendrolagus inustus*), and both the Black-faced Kangaroo (*Macropus melanops*), and the Red Kangaroo (*Macropus rufus*); whilst the Brush-tailed Wallaby (*Petrogale penicillata*) and the Rufous Rat Kangaroo (*Hypsiprymnus rufescens*) have fine capillaries covering the disc and emanating from the centre. The Red Kangaroo has the further peculiarity of a pigmented cord running from the disc to the lens as in some of the Rodents. The Rufous Rat Kangaroo has a well-marked vestigial pecten, while the Black-faced Kangaroo has at the edge of the disc a white bladder-like protuberance.

3. *Phalangistidæ*.—The Phalangiers resemble the other Diprotodontia, inasmuch as they all are devoid of retinal vessels, the round discs being covered with capillaries or a

cushion-like network of vessels. The choroidal vessels are markedly prominent in the Flying Phalanger (*Petaurus sciureus*), and they can be distinctly seen in the Black Phalanger (*Phalangista vulgaris*), but not in the Squirrel-like Phalanger (*Belideus sciureus*). This last-mentioned animal has a brown-pink fundus covered all over with large black dots, while that of the Black Phalanger is creamy-white covered with vermilion dots, the periphery being entirely covered with innumerable dark brown pigment patches. All the Phalangers have a fleshy Membrana nictitans.

B. *Polyprotodontia*.

1. *Didelphyidæ*.—The Virginian Opossum (*Didelphys virginiana*) forms an exception, inasmuch as it is the only Marsupial with a fundus divided into two distinct zones showing all the characteristics of a Tapetum lucidum. The central zone is of the brilliant golden-yellow, peculiar to nocturnal animals, the peripheral area greyish-black with interstices through which the same golden-yellow shines. This animal and the Tasmanian Devil (*Dasyurus ursinus*) are the only Marsupials with retinal vessels. In the Virginian Opossum these arise from the central artery, the vascularisation and the disc resembling that of the Jerboa (*Dipus alactaya*), the same peculiar arch-like arrangement of the vessels being present. This Opossum has another peculiarity, it has no Membrana nictitans, but a peculiar contrivance takes its place in the form of two folds of conjunctival tissue, which arising from either canthus meet in the middle line, thus closing up the eye altogether, at the same time squeezing the eye backwards into the socket. These two folds by their junction thus enclose the cornea as it were in a loose double bag, giving it the appearance of a large œdematous fatty tumour. The animal can protrude or retract its eye by means of these folds at pleasure.

The lens shows the characteristic concentric circles which we have met with in many of the Rodents as well as in the Edentata.

2. *Dasyuridæ*.—The Ursine Dasyure or Tasmanian Devil (*Dasyurus ursinus*) has a reddish-brown fundus with a bluish-grey slightly cupped disc, from which retinal vessels branch out, no choroidal vessels being visible. The opaque nerve fibres in the vicinity of the disc are marked, but not to the same degree as in the next family.

3. *Peramelidæ*.—The Bandicoots examined have prominent choroidal vessels. The Short-nosed Bandicoot (*P. obesula*) somewhat resembles the Kangaroos; fine capillaries radiate over the chalk-white disc. The lens shows the characteristic concentric rings. The eye retracts into the socket, and rolls backwards when touched, and at the same time the Membrana nictitans flashes over.

Perameles lagotis has a similar fundus, except that a large area around the disc is densely covered with opaque nerve fibres, forming a large and very beautiful aster. At the centre of the disc is a well-marked vascular vestigial pecten, shaped like a wickerwork basket. The animal can retract the eye enormously until it is sunk below the rim of the orbit; at other times more than half the eye protrudes. When

the eye retracts, the lids close together at the same time, and the nictitans is drawn half across; at other times the latter is barely visible (2 millimetres only being seen). The nictitans and the lids seem to act together by the same nervous impulse, for I noticed when I forcibly separated the lids the nictitans receded into the inner angle, and when I closed them the fold advanced half across the cornea, which was as far as it could go. The pupils are round, both when dilated and contracted. The iris is a rich dark brown. No fibres were visible, but it showed traces of circular ridges overlaid by a thick coating of dark brown pigment. Innumerable pores, quite visible to the naked eye, are scattered over the front surface of the iris. The free border of the iris is covered at regular intervals all round the edge with a large number of minute tufts of brown pigment like tiny Corpora nigra, which act as a screen when the pupil contracts.

The eyes are more lateral in direction than in any other Mammal, with the exception of some Rodents, being only 15° from the horizontal (*i.e.*, from a line drawn through the orbits).

XI. MONOTREMATA. (Plate 26.)

Through the kindness of some friends in Australia I succeeded in obtaining several living Echidnas, and, after numerous fruitless attempts, ultimately succeeded in examining the fundus, which was of a uniform lavender colour with a chalky-white vertical oval disc, neither retinal nor choroidal vessels being discernible. The fundus thus closely resembles that of some of the birds, but there is no trace of a "pecten." The pupil is circular.

The eye retracts, being squeezed back into the socket by the lids, and rolls inwards, the action being rhythmic, and in every respect similar to that which we find in the Edentata and the Porcupines. The lens has the same concentric circles as in all the lower Rodents, the Edentata, and the Marsupials. There is no visible trace of a nictitating membrane.

PART II.

I. THE COLOUR OF THE FUNDUS OCULI AND THE TAPETUM LUCIDUM.

Anyone who peruses the first part of this paper and examines the illustrations must be struck above all by the diversity of colour, suggesting, before any other, the question: What is the colour of the Fundus oculi due to?

The vermilion-red colour of the fundus of Man, as well as that of the Rabbit and Guinea-pig, has been ascribed by many to the colour of the blood in the choroidal vessels, and by others again to the colouring matter in the retinal epithelial layer.* The brilliant colours observed in the fundi of the domestic Ungulates and Carnivores

* See LORING, 'Textbook of Ophthalmoscopy,' vol. 1, p. 48.

were attributed to the existence of a special choroidal structure, to which the name of *Tapetum lucidum* was given. A difference having been found to exist between the tapetum of the Carnivores and that of the Ungulates, the former was termed* the *Tapetum cellulosum* and the latter the *Tapetum fibrosum*. According to our text-books the colour in our own eyes is due to the choroidal vessels shining through the epithelial layer of the retina, whilst the colour in those animals which have a *Tapetum lucidum* is said to be entirely due to the reflection from this modified choroidal layer.

This explanation is not satisfactory, and I have heard grave doubts as to its correctness expressed by some of our most eminent ophthalmologists; moreover, an examination of the accompanying illustrations will suffice to justify my hesitation to accept the views generally held.

The deep chocolate colour of the Negro and of the Anthropoid Apes might still be explained by the red of the choroidal vessels shining through the pigment layer of the retina, whilst absence of the retinal pigment might be held to account for the visibility of the choroidal vessels in the Albino. The fact, however, that in all the Monkeys lower than the Anthropoid Apes we meet with visible choroidal vessels, except when the animal is of exceptionally dark pigmentation, seems to call for some other explanation. If the choroidal vessels can be seen because the retinal pigment is deficient, their vision ought to be defective as in the Albino, and not perfect, as it evidently is. Nor can I see that the appearance which we meet with in the Bats and Insectivora, in the Suricate and the Cynictis among the Carnivora, and in the Suidæ and Camelidæ among the Ungulata, or the appearance of the fundus in the Rodents and Marsupials, none of which have a tapetum, can be explained in any way on the assumption that the colour is due to the choroidal vessels shining through the retinal pigment layer.

It likewise seems difficult to accept the axiom that all those varied colours which we meet with in the Carnivores and Ungulates are due to the inherent colour of the choroidal *Tapetum lucidum*.

Before recording the observations which I undertook to elucidate the question and the results obtained, it is necessary for me to refer to the structure of the epithelial layer of the retina, and of the choroid, both of which I have found to contribute largely to the colour of the fundus.

As to the retinal pigment layer, I must draw attention to a paper, entitled "Observations on the Macula Lutea," which I published in the 'Archives of Ophthalmology' for 1895. I there pointed out that in Man the retinal epithelial layer consists of a gelatinous mass of united hexagonal cells, in which pigment granules are distributed in a symmetrical manner, and that internally to this gelatinous layer we find a dense layer of acicular pigment crystals. These two distinct kinds of retinal pigment, the granular and acicular, differ further, inasmuch

* BRÜCKE, 'Müller's Archiv,' 1845, p. 387.

as the former, embedded in the gelatinous portion of the retina, are incapable of movement, whilst the acicular crystals are capable of movement under the influence of light.

I have since found the same two kinds of pigment in all mammalian eyes which I have examined. It requires an oil-immersion lens with a high ocular to distinguish clearly between them.

It is from the careful investigations made by Dr. HUBERT SATTLER, an account of which appeared in VON GRAEFFE'S 'Archiv für Ophthalmologie' for 1876, vol. 22, pp. 1-100, that nearly all our text-books take their data regarding the histology of the choroid, and the nature of the two kinds of tapetum. As I shall have to refer to the minute structure of the choroid, his description is here briefly summarised.

Taking the layers of the choroid from the retinal or internal surface to the sclerotic, we have :—

1. The Membrane of BRUCH (Lamina vitrea or Glassy Membrane)—a homogeneous layer except for its external surface, which under high magnification shows a network of fibre-like lines, and includes irregular or polygonal spaces.
2. The capillary layer or Choriocapillaris.
3. A continuous membrane, or sub-capillary epithelial layer resembling the endothelial lining of the small veins.

It is this layer which constitutes the Tapetum cellulosum of the Carnivores.

4. Several layers of intensely fine wavy elastic fibres quite free from pigment cells. In these layers we find the small arteries, and the majority of the middle-sized veins.

This is the part which in the Ungulates constitutes the Tapetum fibrosum.

5. The endothelial expansion.
6. A large elastic tissue network containing numerous pigmented branched cells, known as fusca cells.
7. The branches of the large choroidal vessels lying between the last layer and a second similar network (8), this portion of the choroid being permeated by innumerable fusca cells, and occupying at least three-fourths of the entire thickness of the choroid.
8. The elastic network also densely pigmented, referred to above, and resembling the sixth layer.
9. The Lamina suprachoroidea.

After this comes a lymph space, and then the densely pigmented Membrana fusca of the sclerotic.

This fusca layer must not be confounded with the fusca cells which permeate almost the entirety of the choroid.

The fundus in a healthy enucleated human eye appears slaty or brownish-grey, but by concentrated light it shows the same bright vermilion colour as that seen by the

ophthalmoscope. When the vitreous is carefully removed the colour remains the same. When the retina is removed the colour of the fundus is unchanged by diffused light, but with concentrated light, although still red, it is of a duller and browner red than the vermilion colour previously seen. If a piece of the chòroid with the internal (retinal) surface uppermost is then freed of retinal pigment and spread on a slide, it shows with reflected light the reddish-brown colour once more, and we perceive at once by means of the microscope that this is due to reflection from the fusca cells which permeate the choroid. Evidently the ground colour observed by the ophthalmoscope in ourselves and the animals which have no Tapetum lucidum must be ascribed to light reflected by the fusca cells which permeate the choroid, modified by the retinal pigment and the visual purple or rhodopsin contained in the retina. The retinal pigment itself appears brownish-red by reflected light; with transmitted light it is transparent. High magnification reveals two kinds of pigment, granular and acicular. The retina, including the hexagonal pigment layer and the pigment crystal layer, which lies internal to it, is evidently transparent in the same sense as a sheet of red glass. The membrane of BRUCH is also transparent, and it is the fusca cells which first arrest the light. The choroidal pigment obscures to a greater or lesser degree the choroidal capillaries and vessels.

Generally speaking, all fundi which show a red, reddish-brown, chocolate, or slaty colour with that peculiar translucent lustre which we notice in Man, owe their colour mainly to the reflection produced by the pigment cells of the choroid (fusca cells).

The Lorides, Nycticebus, and Galagos, as well as all the Carnivora which I have examined, except the Suricate and the Cynictis, have a Tapetum cellulosum. As we have seen, SATTLER considers this tapetum as due to a modification of the endothelial membrane or subcapillary epithelial layer situated immediately exterior to the chorio-capillaris. If we open the eye of any of the Carnivores and remove the lens and vitreous and then the retina, the latter shows the same salmon colour as in ourselves, bleaching rapidly like ours when exposed to light. The fundus, devoid of retina, but having the retinal pigment still adhering to the choroid, shows the brilliant colours previously observed with the ophthalmoscope, which, however, fade rapidly when exposed to light, especially to daylight. If prior to their fading all that lies on the membrane of BRUCH is rapidly brushed away with a camel-hair pencil, the whole of the colour is likewise removed, the choroid presenting the appearance of an untanned opaque leather of a dirty-white washed-out colour. If what has adhered to the brush is placed on a slide and examined microscopically, it is seen to consist merely of the retinal pigment together with fragments of the hexagonal cells. The acicular pigment crystals, which are of the same shape as those found in the human eye, appear by reflected light, of the same colours which we observed with the ophthalmoscope before enucleation, and with concentrated light when examining the choroid before brushing them off. Even with high powers the microscope shows no trace of the capillaries of the choroid, which seems very remarkable if the opacity is confined to

the layer immediately external to the choriocapillaris, unless it be that the membrane of BRUCH is opaque in these animals.

The opaque layer is very thin, as can be seen by teasing it with needles, when the densely pigmented vascular underlying structure appears wherever the opaque portion is torn away.

In animals which have a dark brown, purple, or reddish peripheral zone, the bright coloured acicular pigment and the opaque membrane only occupy the central zones. In the peripheral zone, the inner layers of the choroid are transparent as in ourselves, and the colour is due to the reflection from the fusca pigment cells. That is why choroidal vessels can never be seen over the central areas, but are frequently noticeable in the peripheral zone, which, in contradistinction to the Tapetum lucidum, has been termed the Tapetum nigrum. To see the colour of the peripheral zone in the choroid when laid bare, light must be concentrated upon it, otherwise it appears slaty.

In the Ungulates the case is different ; there also, the peripheral area, wherever seen with the ophthalmoscope to be red, reddish-brown, chocolate, or slate, resembles that of the Primates, inasmuch as the colour is due to reflection from the choroidal pigment, the internal layers being transparent. The acicular crystals removed from the central area, viz., the Tapetum lucidum, have a colour as in the Carnivores, but not the colour which we observe with the ophthalmoscope, and once the retinal pigment has been well brushed away, we see that the opaque Tapetum lucidum remains beautifully coloured. The coloured retinal pigment bleaches by exposure to light, but the tapetum of the choroid, if kept moist or immersed in a weak (5 per cent.) formol solution, will retain its colour indefinitely.

In most Ungulates which I have examined this opaque coloured portion is of a brilliant blue ; in many, the central area is of a bright bluish-green.

Therefore, whilst in the Carnivores (other than the Cynictis and the Suricate), as well as in the Galagos, the colour in the central areas is due exclusively to the retinal pigment, modified probably to some extent by the retinal visual purple, in the Artiodactyls (other than the Suidæ and Camelidæ) as well as in the Equidæ, the colour of the central area is due to the coloured retinal acicular pigment, lying on a highly glistening and beautifully coloured opaque choroid ; thus the dark green fundus of the Horse is due to yellowish acicular crystals lying on a structurally blue background, the deep brown of the peripheral area being explained by the colour of the choroidal pigment, the layer which is opaque over the central area being there transparent. The pale greenish-blue or lavender colour in the Goat, the bluish-green, and yellow zones of the Ox and the Cervidæ, are all combinations of coloured retinal acicular pigment with an opaque choroid, structurally blue or green, as a background.

In the Bats, and in the Rhinoceros and the Proboscidæ, the colour may be due to reflection from the retinal pigment, without any underlying structural colour, and a

similar condition obtains in the Hystricidæ and the Edentata. I come to this conclusion because the fundi of these animals do not show the brilliancy of the Carnivores and the Ungulates, but the appearance points to an opaque choroid. In the Bats the colour is more of a buff than a golden-yellow, and more of a dull red than a brilliant scarlet in the Hystricidæ, whilst the Elephants and the Hyracidæ have a dull straw-coloured fundus. In the Edentata we again meet with this dull chalky appearance, which makes the red appear brick-like and half-toned.

According to SATTLE, the Cetaceans have a tapetum resembling that of the Ungulates. Among the Rodents, the Flying Squirrels evidently have a tapetum, but for want of material I have not been able to examine its nature.

The Marsupials (except *Petaurus*, which seems to have a *Tapetum lucidum*) have all transparent retinal pigment and transparent choroids free of choroidal pigment, and that is why we see the choroidal vessels so distinctly delineated on the black background of the limiting membranes of the choroid and sclerotic.

It is very remarkable that the stellate dots and similar markings, although ascribed by SATTLE to choroidal capillaries, have nearly always the same colour as the peripheral zone.

Evidently a considerable amount of further research is needed to clear up many points connected with the structure of the choroid and the nature of the retinal pigment, before we can explain in a satisfactory manner the great variety of colours and the different degrees of transparency which we observe in the *Fundus oculi*. The importance of this from a physiological point of view must be self-evident.

As to the actual colours seen in the *Fundus oculi*, almost every shade of colour is to be found; but if we classify them without taking gradation into account, and merely consider the predominant colours, neglecting the peripheral colours in animals with differentiated areas, we can distinguish three main types:—

1st. *The Red Type*, including every shade of red, chocolate, and brown-grey. To this belong Man and all the Primates, with the exception of the Galagos; some of the Insectivora, the Suricate, and *Cynictis* among the Carnivores; the Camelidæ, Suidæ, Rhinoceros, and Hyracoidea among the Ungulates; all the Rodents with the exception of *Pteromys* (Red and White Flying Squirrel) and the Spotted Cavy; the Edentata, the Marsupials—with the exception of the Virginian Opossum—and *Echidna*.

2nd. *The Yellow Type*, including all shades of yellow and orange. To this belong the Galagos among the Primates; the Chiroptera, the Felidæ, and some Mustelidæ among the Carnivores; the Tapir and Elephants among the Ungulates. The above-mentioned Flying Squirrel and Spotted Cavy among the Rodents.

3rd. *The Green and Yellow-green Type*.—To this belong all the Carnivores, with the exception of those mentioned, and all the Selenodonta, with the exception of the Goats and Camels.

All the animals which I have examined may be considered as capable of being

classified under one of these three heads. It will be noticed that the red end of the spectrum is the commonest, next the orange and yellow, and then the green; in other words, the colours become rarer in proportion to their refrangibility. In no case do we see a uniform blue or violet fundus, although a deep blue peripheral zone is to be met with in the Grey Mongoose (*Herpestes griseus*), a lilac fundus in the domestic Goat, narrow purple intermediate zones among the Foxes and Jackals, and scattered isolated blue patches among the domestic Cats.

Concerning the occurrence of a Tapetum, it is obvious that it must be preceded by a more primitive condition, and the T. cellulolum and T. fibrosum represent two divergent analogous types, both lying, as already described, in different layers of the choroid. It is therefore advisable to distinguish a third kind, viz., T. obscurum, in those fundi in which the choroid has an opaque inner layer, but which is of a dull lustreless colour. Such a fundus does not require a dark peripheral zone to limit or absorb the reflections, and it is therefore uniformly coloured. The T. obscurum is the forerunner of the T. fibrosum. It occurs in the Rhinoceros, Hyrax, and Elephant, as well as in the Hystricidæ and Castoridæ. Again, the incipient stage of the T. cellulolum may be termed T. primitivum; it occurs in some of the Carnivora and various Rodents, but according to SATTLER it is represented (although not yet acting as a tapetum) in all Mammals by the first or subcapillary layer. It becomes a tapetum as soon as it is composed of several layers.

II. VASCULARISATION OF THE RETINA.

The references to the vascularisation of the retina, which can be found in the extensive literature on the subject, are almost invariably restricted to detailed descriptions, while no attempt has been made to give a comprehensive and coherent account of the phylogenetic development of this vascularisation. GEGENBAUR,* for instance, restricts his account to the following sentences:—

“A special retinal vascularisation begins with the Mammalia; but these vessels are not derived from those which perforate the optic nerve and have entered it on the occasion of the formation of the corpus vitreum; they are derived from the posterior ciliary arteries, which (Pigs, Ruminants) thereupon have secondarily become connected with those central optic vessels. The distribution or spreading (*sic*) development of these retinal vessels remains at several stages in the various Mammals. In the Horse they are restricted to the neighbourhood of the optic disc, leaving the greater part of the retina without vessels. In the Rabbit they follow only the radiating bundles of the optic nerve. In the Guinea-pig likewise only part of the retina is vascularised.”

The supply of the retina is effected in various ways:—

I. INDIRECT SUPPLY, by means of osmosis from the vessels of neighbouring parts.

* ‘Vergleich. Anat. der Wirbelthiere,’ 1898, p. 941.

A. *Hyaloid Supply*.—Here we have to distinguish again between two categories :—

(a) The Corpus vitreum is nourished by a processus falciformis, the hyaloid vessels lying well inside the Corpus vitreum (*e.g.*, Elasmobranchs).

(b) The hyaloid vessels spread over the surface of the corpus vitreum, being consequently in the immediate vicinity of the retina (*e.g.*, holosteous and many teleosteous fishes), and it is significant that this surface distribution occurs in Teleostei amongst those which are devoid of a processus falciformis. Hereto belong also the Amphibia,* and most of those Reptiles (*e.g.*, Snakes) which are devoid of a pecten. The Mammalia take up an intermediate position. Their hyaloid vessels are restricted, with some notable exceptions, to the foetal period ; but these are both surface vessels and a central vessel, namely, the Arteria hyaloida (in a restricted sense) which, passing through the corpus vitreum, goes to the posterior surface of the lens ; in this respect it is at least analogous to the falciform process.

B. *Choroidal Supply*.—This is probably the chief supply of the retina in those animals which possess a well-developed pecten (most Sauropsida), but are devoid of superficial hyaloid vessels. This choroidal supply by osmosis is also with certainty demonstrated in the Mammalia for at least part of the thickness of the retina.

II. DIRECT SUPPLY. A. *From Superficial Hyaloid Vessels*.—This is known to be the case where the hyaloid vessels are directly continued into the retina, where they produce two vascular layers.

B. *From Special Retinal Vessels, culminating in the Arteria centralis*.—This mode is restricted to the Mammalia and certain Snakes. At least I have found several such retinal vessels in specimens of Boa and Python examined ophthalmoscopically.

It is obvious that these two main categories of the sources of blood supply are not, or rather *were not*, always exclusive of each other. The oldest, the hyaloid supply, is in the Mammalia superseded by the special retinal vessels, which themselves, in a roundabout way, are derived from those of the choroidal plexus. Of course ultimately all those vessels, including those of the falciform process and of the pecten, are branches of the Arteria ophthalmica interna ; the hyaloid arteries as well as the choroidal plexus have entered the eye-cup together with the mesodermal tissue. It is worthy of note that, excepting in the vicinity of the Ora serrata, no direct vascular supply of the retina is known to be effected by the choroidal vessels themselves ; so far as their share in the retinal supply is concerned it is practically effected entirely by osmosis.

Restricting ourselves now to the Mammalia, we have the following stages of the gradual development of special retinal vessels, and since, as we shall see, these stages

* In some cases only the large vessels have a surface distribution ; the capillaries and smaller vessels lie *between* the bundles of the nerve-fibre layer of the retina, as can be well seen in the eye of the American Bull Frog with the ophthalmoscope

are exhibited throughout life by groups of Mammals which represent ascending lines from the lower to the higher orders and families, these stages themselves are of phylogenetic value.

I. *Anangiotic Type*.—*Animals in which the Ophthalmoscope reveals no Traces of Retinal Vessels*. Since, in the adult, there are no superficial hyaloid vessels spreading over the Corpus vitreum, the retinal supply is entirely dependent upon osmosis from either the Corpus vitreum or from the choroid, always of course with the possible addition of lymphatic supply in the sheaths of the nerve bundles or fibres themselves. Such *anangiotic* vessel-less eyes (to use LEUCHART'S term) are those of Echidna, Perameles lagotis, Dasypus, Hystrix, Castor, Chinchilla, Myopotamus, Pteropus, Rhinoceros; *i.e.*, in representatives of the lowest mammalian orders, namely, Monotremes, Marsupials, Edentata, and Rodentia, besides a Perissodactyl Ungulate and Chiroptera, to which latter further reference will be made later on.

II. *Pseudangiotic Type*.—*Retinal vessels are scarce in numbers, very short, and minute*. They emanate from the optic disc, and extend only as far as the disc or a short distance beyond it. This is the case chiefly in Hyrax, Elephas, Tapirus, Equus, Myrmecophaga, Phalangista, Belideus, Petaurus, Perameles obesula, Hypsiprymnus Dendrolagus, Capybara, Cœlogenys, Cavia; *i.e.*, summarised, in the majority of the Marsupials, Perissodactyls, Edentata, and Rodentia. In some of these animals, notably in Myrmecophaga and Capybara, these vessels are so minute and short that they might almost as well be put into the first group. They are in fact intermediate between, or transitional from, the anangiotic to the angiotic stage, and may be called *pseudangiotic*.

III. *Angiotic Type*.—*The retinal vessels are of varying calibre*. They emanate from numerous trunks situated at or near the periphery of the disc, and spread over the greater portion of the retina. This is the case in most of the Carnivora, most typically in the Felidæ, Viverridæ, Mephitis, Meles, Ursidæ, also amongst Rodents the Sciuridæ, Leporidæ, and Myoxidæ. The two latter are in so far intermediate between the second and third group, as the vessels extend only over a small portion of the retina, being in the Leporidæ restricted to the peculiar transverse expansion of the white fibres of the optic nerve. Amongst the Carnivora, Nasua (one of the Procyonidæ), Lutra, and *Herpestes nepalensis* approach the next or *Euangiotic* type.

IV. *Euangiotic Type*.—*The retinal vessels form a complete system*. They emanate chiefly from the centre of the optic disc, there being, besides smaller more peripheral vessels, one or more typical arteriæ and venæ centrales. This is the case in some of the Myomorpha, a few Marsupials, *e.g.*, Didelphys and Dasypus, Erinaceus and Talpa, in some Viverridæ, in the Canidæ, Hyænidæ, the Artiodactyl Ungulates, and all the Primates. In the latter the vessels are most centralised, while in the others, especially in the Artiodactyls, there are still many smaller and peripheral vessels, besides the principal arteries and veins.

Intermediate stages are, of course by no means uncommon. The four types can be

taken only as representing the main features. Further examination shows that almost every one of the main groups of Mammals has representatives of two or more of these four chief types; in other words, some of the genera, and even species, have remained at a lower level than that which has been reached by others. This shows plainly that the vascularisation of the retina by special vessels has not been inherited by Mammals as a class, but that it has been developed independently in the various main groups. This is well exemplified by that large assembly of Ungulata in the widest sense, beginning with *Elephas* and *Hyrax* and the *Perissodactyls*, and ending with the *Ruminants*, which are the most highly developed of all the *Ungulata*. The *Marsupials* and the *Rodents* show a similar parallelism.

We see clearly that the special retinal vascularisation begins with many minute and short vessels which enter upon the inner surface of the retina in the periphery of the disc; they are, in fact, continuations of the vessels of the sheaths of the optic nerve. Whilst these new vessels increase in size and numbers, they assume a more and more central position, becoming more deeply embedded within the nerve and its disc, until some of them appear as typical central vessels, and their more outward companions disappear from the surface.

Some animals, *e.g.*, the *Cervidæ*, have multiple discs with a central vessel for each; and in most of the *Sciuromorpha*, which have an enormously elongated disc, an immense number of large trunk vessels emanate in parallel lines like the teeth of a comb.

The manner in which the retinal vessels enter the eye has been studied by VOSSIUS, and the manner in which the larger arteries spread out from the disc to join the veins, and their course, has been described by LANGENBACHER in *Man*, the *Cow*, *Deer*, *Goat*, *Sheep*, *Pig*, *Dog*, *Cat*, *Horse*, *Mole*, *Rabbit*, *Guinea-pig*, and *Rat*. HESSE investigated the *Rat*, WILHELM HIS the *Rabbit*. The most elaborate paper is by BRUNS,* and this contains also a list of the papers of other authors. They all deal almost exclusively with the so-called domesticated animals.

As a rule the veins and arteries are clearly distinguishable by a difference of coloration as well as of size; moreover the larger vessels usually show a distinct median whitish line, more marked in the arteries than in the veins. All the *Myomorpha* have this streak exaggerated in the arteries, in some to such an extent that the arteries appear as pure white streaks without a trace of red, whilst the veins retain their lake colour. In some few animals I have found it impossible to distinguish between the veins and arteries, all the vessels having the same diameter and the same vermilion colour by which we recognise arteries. I have found this to be the case in the *Seal*, the *Skunk*, and the true *Squirrels*. In the *Hedgehog* and the *Mole*, and possibly in some of the other *Insectivora*, the arteries run from the disc as very minute vessels, losing themselves almost immediately in the substance of the retina, while the veins are large and well developed, and extend to the *Ora serrata*.

* "Vergleichende Anatom. Studien ueber das Blutgefässsystem der Netzhaut," 'Zeitsch. für Vergl. Augenheilk.,' vol. 8, p. 77.

The number of arteries and veins and their distribution varies through such wide limits, and frequently to such an extent in the same order, that I have so far not been able to establish any definite rule. I have noticed that in all the Simiæ, except Man, the vessels run a nearly straight course, and the branches usually stand at 45° to the main trunks. In Man they run a more wavy course, and the branches come off in an irregular manner. The Artiodactyla have a characteristic vascularisation. The central artery and vein each divides out into three main trunks, one passing with its companion vein straight upwards for some distance before giving off a number of horizontal branches, which again give off branches which pass vertically downwards to disappear at the sensitive area. The other two pass obliquely downwards and outwards and downwards and inwards, sending off minute twigs towards the sensitive area from below.

In the Myomorpha and Sciuromorpha the vascularisation is very prolific. In the former the arteries and veins, of which there are seven or eight of each, run in a strikingly straight course at equal angles, resembling the rays of a Starfish.

The actual mode of supply of the retinal layers by the special retinal vessels has been studied by SCHNELLER* in an elaborate series of investigations. He has summed up his conclusions as follows :—

1. The pigment epithelial layer of the retina is only nourished by the choriocapillaris.
2. The rods and cones are chiefly nourished by the choriocapillaris, but in a very slight degree by the retinal vessels.
3. In the same way the outer nuclear layer receives its supply, but to a more marked degree, from the retinal vessels (capillaries).
4. The remaining layers of the retina are nourished by the retinal vessels alone. The external layers of the retina are nourished by osmosis, the choriocapillaris acting merely in a vicarious manner for the retinal vessels.

The important fact is that the retina is nourished from two sources, the outer layers still by the choroid, the inner exclusively by the special retinal vessels. In this respect I quite agree with SCHNELLER; only with regard to the actual extent of the vessels into the retina I have to make an additional statement. In Man and a number of other Primates (*Troglodytes niger*, *Cercopithecus mona*, *Macacus rhesus*, *Cynocephalus hamadryas*, *Galago maholi*), as well as in some of the Ungulates (Horse, Sheep, and Ox), Carnivores (Dogs and Cats), and Rodents (Rats, Mice, Rabbits, and Guinea-pigs), all the retinæ of which I have examined microscopically, I have found invariably that no blood-vessels are observable external to, *i.e.*, beyond, the outer molecular layer. The large vessels lie exclusively in the nerve fibre layer, and the ganglion cell layer. Immediately the inner molecular layer is passed we come to a

* 'Zeitschrift für Vergl. Augenheilkunde,' vol. 8, p. 95.

region in which only capillaries and fine vessels occur, and this region again is strictly limited by the outer molecular layer, beyond which no vessels or capillaries can be seen. *In other words, the inner molecular layer is a barrier to the larger vessels; the outer molecular layer a barrier to capillaries, the latter being found between the two molecular layers.* Beyond the outer molecular layer the retinal vascularisation ceases, and evidently these external parts depend for nourishment upon osmotic action from the choroid through the membrane of BRUCH.

The fact pointed out by LANGENBACHER that the retinal vessels of the Rabbit lie internal to the Membrana limitans interna, as in the Amphibia, holds good for all the Leporidae, and causes the vessels to appear to the ophthalmoscope as raised ridges, which cast a distinct shadow. As far as my observations have gone, the Chevrotain is the only animal outside this family which has these retinal vessels similarly raised.

We have now to consider the question, in connection with the contents of the next chapter (III.), whether there are any traces left in the Mammalia which are indicative of a pre-mammalian stage of retinal supply, besides that of the embryonic occurrence of the superficial and the central hyaloid vessels. It is well known that in the human eye, in contradistinction to any other part of the body, the several branches of the retinal arteries do not anastomose with each other (and the same holds good with regard to the veins), excepting a few minute branches near the periphery. In a few rare cases anastomoses have been observed, both between branches of the retinal vessels and between the vessels of the retinal and choroidal systems, but this is quite abnormal. Now I find that those Mammals which have a complete vascularisation follow the same rule, as regards absence of anastomoses of the arteries as well as the veins. But in some of those Mammals which have no retinal circulation, the vessels being restricted absolutely to the area of the disc, I have found a dense anastomosed network which forms a termination to what appears at first sight to be an elaborately developed Arteria centralis. Exceptional as such a behaviour of retinal vessels would be, it had to be put down simply as a curious exception until further extended ophthalmoscopic research revealed the occurrence of such a central meshwork side by side with the occurrence of minute independent vessels radiating from the peripheral portions of the disc (*Macropus melanopus*, *Halmaturus brachyurus*, *Phascalomys*, *Dasyprocta isthmica*, *D. azarae*, and *D. agouti*), or both systems of vessels were connected with each other (*Belideus* and *Petaurus*). The mystery was explained by the Marsupials *Perameles lagotis* and *Hypsiprymnus rufescens*, and the Rodent *Myopotamus coypu*, which all being analogous, so far as the retina is concerned, possess an unmistakable pecten. In the Kangaroo this organ is typically developed and extends to the length of almost the diameter of the disc, directly into the corpus vitreum. The same applies to *Perameles lagotis*, except that the organ is less conical and is composed of a wider meshwork of loops without a special cone or supporting body. In the Coypu the organ is rather broad, forming a complicated basketwork of vessels, which hangs or falls over sideways. In every case it starts from a narrow

base at the centre of the disc. Smaller traces of such vessels reduced to low and small cushions of more or less mossy appearance occur in the Chinchilla and in *Cœlogenys*. Now it is of the greatest importance for our attempt to understand the true meaning of the conglomeration of vessels, that in a few cases they occur side by side with a hollow cone, for instance in *Castor* and *Cavia*. This hollow cone itself is easily understood. It is the remnant of CLOQUET'S canal, or rather the walls of this canal, which served as the support or core of the central hyaloid artery, and both together, especially during foetal life, when extending to the lens, are the homologue of that organ which appears in certain fishes as the falciform process. Both falciform process and hyaloid artery differentiate into capillaries only at the free end near the lens, the nourishment of which is their principal object. This falciform process after the loss of the hyaloid artery often persists in Mammals, in the shape of a dense fibrous cord of rather larger size in *Cervus porcinus*, apparently also in *Alactaya*, and in *Muridæ* and *Myoxidæ*. It has been observed as such abnormally in Man. In others it takes the form of a hollow cone or trumpet. This is the condition originally described by CLOQUET, and observed occasionally in Man, in Giraffus, *Castor*, *Cavia*, *Pteropus*, very long with multiple base in *Sciurus palmarum*, sometimes swollen out into the shape of a bladder-like bag in the Ox; or the cone itself has disappeared, and the spot whence it sprung is sunk in and appears as the funnel-shaped "area Martegiani" (as in *Bos*, *Elephas*, and *Capybara*); lastly, the supporting cone, *i.e.*, the wall of CLOQUET'S canal, has disappeared, but the hyaloid artery remains as a short pulsating vessel springing from the main trunk just after it pierces the disc. This has been observed in Man, and I saw it in a specimen of *Castor*. Wherever this hyaloid artery occurs it is not accompanied by a returning vein. It is obvious that this hyaloid artery and its supporting cone cannot be the same as that conglomeration or basketwork or cushion of vessels observed in some Mammalia, which we have homologised with the pecten of the Sauropsida. To call it a pecten or "comb," even in its fullest development, as in *Hypsiprymnus*, is of course not strictly correct, since it possesses none of the folds characteristic of the avian pecten; but this is immaterial, since *Apteryx mantelli* possesses a pecten destitute of folds, but which, notwithstanding, is undoubtedly a functionally active organ, and in every other respect well developed. Again, its counterpart in the Reptilia (where it is often called, or at least likened to, the *processus falciformis*) consists either of an elongated vascular plexus extending right through the *Corpus vitreum* towards the lens, or it is much shorter and forms a few folds (*Iguana*), or it is reduced to a small conical basketwork process which contains a core (*Chamæleo*), (compare *Hypsiprymnus*); or it is reduced to a low pigmented patch, containing only minute vessels as in the *Crocodyles* (compare the appearance of this with that in the *Dasyproctidæ*). The existence of the core central in position is important. It is the remnant of the same supporting structure, including CLOQUET'S canal and the strands of the falciform process which has become surrounded, bespun by the artery and returning vein, which forms the vascular

meshwork of the pecten. This is in reality a detached portion of the choroidal plexus which has got into the secondary eye-cup to nourish the Corpus vitreum; but it receives its vessels from those of the sheaths of the optic nerve, and is now, at least in Birds, shut off from the choroid and retina proper by the optic disc. In the Mammalia this same basketwork of vessels (arterial and a returning vein) does not always surround the Cloquet cone, it lies free, aside of it; and when the Cloquet canal (a remnant of the falciform process itself) is reduced or lost, there naturally the "pecten" extends as a free, unsupported basketwork into the vitreous body.

To sum up, the vessels of the falciform process of Fishes and the central "hyaloid" artery, wherever this occurs, are essentially the same. The falciform process and the pecten, although both have found their way into the Corpus vitreum through the choroidal fissure as extensions of the choroid, are analogous and not homologous structures. In Reptiles and Birds the hyaloid artery is superseded by a new development, viz., the Pectinal system. In some of the lower Mammalia both systems actually occur side by side, but both are rendered unnecessary by the development of a third system of supply, viz., special retinal vessels, which ultimately culminate in the possession of an arteria and vena centralis retinae.

It is beyond the scope of this paper to investigate the question as to whether the Amphibia ever possessed the pectinal supply, or whether they have lost it. Possibly they, as well as the equally small-eyed Dipnoi, have lost the falciform process and pecten, and the same applies to the likewise small-eyed and nocturnal Echidna, the only representative of Monotremes I have had an opportunity of examining. The absence of even a trace of a pecten in the Echidna does not militate against its having been inherited by the Mammals from their Reptilian ancestry. It is a frequent mistake to assume that, since the Monotremes are the lowest living Mammals, they must therefore be the most primitive in *every* respect. In reality they are highly specialised, and in some cases have lost every trace of low condition. This is shown, for instance, by the under-jaw of the Echidna, the auditory ossicles, the teeth, and—coming back to whence we started—the eye, which is extremely small and reduced by nocturnal burrowing life.

The occurrence of a pecten-like structure in the eyes of two of the lowest Mammalian Orders, viz., the Marsupials and Rodents, is another band between the Mammalia and Reptilia.

III. REVERSIONS OF TYPE AND VESTIGIAL RELICS.

Every ophthalmologist who examines the illustrations of the Fundus oculi of the Mammalia appended to this paper, will surely be struck by the fact that some of the normal conditions observable in certain animals closely resemble those which we find in Man as congenital defects. If it be remembered that congenital ocular defects

occur most frequently in those persons who exhibit other signs of abnormal development, such as webbed feet or hands, the absence or increase of digits, the non-closure of various foetal clefts, supernumerary nipples, and the like, the fact above stated will be admitted as some justification for considering congenital defects as reversions of type.

Of course, not every congenital defect of the eye is a reversion, if thereby be understood development arrested at a stage which is truly ancestral to the animal which exhibits the defect in question. In the cases we have to deal with, "ancestral" is to mean descent within reasonable limits. A cleft palate in Man is of course a case of arrested development, but it is no more ancestral than the occurrence of webbed feet, for the simple reason that there is no normal Mammal in which the palatal bones do not meet in the median line. It would be rash to confound that which is normal in a Lizard with what in a Mammal is obviously a malformation.

Abnormalities of the human eye have, of course, been frequently recorded, and it is especially STEPHENSON* who has tried to explain several of the cases to be mentioned presently as reversions of type to the anatomical structure of the lower vertebrates.

The commonest and widest known instance of a vestigial relic, a true case of reversion if unusually developed, is the *Membrana nictitans*.

1. *Membrana nictitans* is reduced, as a rule, in Man to the *Plica semi-lunaris*. Recently I have found a case of an obvious nictitans in a youth, which was capable of slight movement and extended in crescent form nearly as far as the cornea.

FLOWER and LYDEKKER† have the following sentence:—

"In almost all Mammals below the Primates, except the Cetacea, a nictitating membrane or third eyelid is placed at the inner corner of the eyeball, and works horizontally across the front of the ball within the true lids. Its action is instantaneous, being apparently for the purpose of cleaning the front of the transparent cornea, a function unnecessary in animals whose eyes are habitually bathed in water, and which in Man and his nearest allies is performed by winking the true eyelids."

The above statement requires considerable modification. A fully-developed nictitating membrane, active enough to sweep the whole cornea, exists *only* in the *Ungulata*, and not even throughout this Order, since the Suidæ and Chevrotains, although possessing a nictitans moderately developed, rarely use it, and then it is not active. Throughout the Carnivora and Marsupials it is much less developed and usually passive, whilst throughout the Primates, Chiroptera, Insectivora, Rodents, and Edentates it is still more reduced and, with rare exceptions, entirely without movement. The reduction *in situ* within the order Primates is gradual, the nictitans being

* 'Medical Press,' Oct., 1893.

† 'Mammals, Living and Extinct,' p. 73. London, 1891.

slightly less reduced in the Lemurs than in the true Monkeys, and in the latter less than in Man. Only one of the Monkeys (*Macacus speciosus*) is exceptional, in that its nictitans is capable of slight movement. Lastly, the nictitans is entirely wanting in the marine Mammals, Sirenia and Cetacea.

In some animals in which the nictitans has become useless and truly vestigial, another protective contrivance has been developed in its stead. The eyes can be retracted into their sockets (as also in various other Mammals by the *Musc. retractor bulbi*), and, as further protective, there are two folds of conjunctival tissue which come forward from both canthi to meet in the middle line in front of the cornea like a loose bag, as the eye retracts. This is the case chiefly in the Edentata, Marsupials, and Monotremes.

Now considering that there is no land Mammal which does not wink the true eyelids, or else rotates and retracts the eyes and thereby cleans the corneal surface, these eyelids must be sufficient for this purpose, and this is especially obvious since the majority of Mammals are devoid of functional nictitating membranes. Even the Ungulata, in which the membrane is by far the most developed and active, blink freely. Consequently the primary use of this third lid, viz., that of cleaning the corneal surface, is lost within the class of the Mammalia, and its preservation in the Ungulata calls for a special explanation.

Now the Ungulata alone are those which "graze" in the proper sense of the word. They poke their heads down into the long and sharp grass, while they are notoriously those which have most need of being on the alert for the Carnivores, their natural enemies; in fact, they have to keep their eyes open all the time, and these are, in addition, rather large. The fully developed nictitans protects the cornea from injury, and sweeps with great rapidity over it and back again into its concealed position.* That the primary object of this third lid is that of sweeping is obvious enough. It exists fully developed in all the lower classes of vertebrates, from Elasmobranchs and Amphibia through the Reptiles and Birds, with a few special exceptions, e.g., Snakes, where it is lost for obvious reasons. In none of the lower vertebrata are the true eyelids capable of rapid movement; the upper lid remains stationary, while the lower alone moves upwards. This is even the case in Birds, and it is only in the Mammalia that instantaneous shutting and opening, or blinking, has been developed.

2. *The retractor muscle* of the eyebulb is of frequent occurrence, notably in Marsupials, Edentates, Rodents, and Ungulates, i.e., chiefly in the lower orders. Vestiges of such muscles in Monkeys have already been recorded by OWEN.

3. *Opaque Nerve Fibres*.—The most common occurrence as a normal condition in other animals of that which in ourselves is regarded as a congenital defect, is a diminished transparency of the nerve fibre layer as it radiates from the disc. A slight

* The fact that the Ant-eater alone among the Edentata (which I have examined) possesses a well developed nictitans would lend support to the above view, for if its habits be considered it is obvious that its eyes especially require protection from ants and grit.

degree of opacity is met with in the Negroes and all dark-haired races, and in a number of Simiæ, and we find semi-transparent nerve fibres distributed throughout all the Orders. Opaque nerve fibres are most marked in some of the Rodents, more particularly in the Leporidæ and in some of the Marsupials, such, for instance, as the *Perameles lagotis*, in which the fibres are actually opaque and not merely semi-transparent.

All stages of partial and even total opacity of the nerve fibres, extending over areas which vary enormously, occur congenitally in Man; sometimes this does not affect vision, but more frequently, and always in the opaque forms, gives rise to blind areas, known as scotomata, over the regions of the visual field affected. As a rule these opaque fibres start from the disc; in all other cases they invariably follow the course of a main arterial trunk; this is also the case normally in other Mammals.

4. *Physiological Cup and Congenital Discoloration of the Disc.*—Another congenital anomaly which very frequently occurs in Man is known as the physiological cup, which, however, never interferes with vision. This is a form of excavation of the optic disc, often very deep and of chalky whiteness, but limited, as a rule, to the central portion of the disc, the margin retaining its colour, and being on a level with the rest of the fundus. The retinal trunks curl over the edge of this depressed cup to reach the retina, and in rare cases no central artery can be seen. The margin of the disc, which remains normal, varies in width and extent, and in some few cases the cup has been observed to occupy the entire area of the disc. But for the margin, the physiological cup can easily be mistaken for that depression of the disc characteristic of glaucoma, a disease due to increase of tension of the globe. In the disc thus altered by disease the retinal vessels likewise curl over the edge of the disc; and the central artery, though present, is on a lower level.

An appearance similar to the physiological cup, presenting a striking resemblance to the glaucomatous one, occurs as a normal condition in all the Felidæ and a considerable number of the other Carnivora, and we also meet with it in the Flying Squirrels and some of the other Rodents. In all these animals the central vascular trunk is absent, being replaced by a number of large vessels which run between the optic nerve and its sheath, curling over the edge of the depressed disc to spread in various directions towards the periphery.

In the Bears we have an arrangement of vessels which closely resembles a condition which has been described and depicted by J. B. LAWFOORD* as occurring congenitally in Man.

Lastly, under this head we may mention both the white and grey discs, which occur normally in a number of animals widely separated in classification, such as the Skunk, Rhinoceros, Porcupine, Armadillo, and Echidna. The same appearance is found in Man as a congenital abnormality with normal vision. It is called white or grey atrophy of the disc; wrongly so, as it ought to be referred to as "discoloration," the

* 'Trans. of the Ophthalmological Society,' vol. 15, Plate 8.

word "atrophy" being applicable only to the similar appearances due to a disease of the optic nerve which entails blindness.

Frequently the grey or white congenitally discoloured disc in Man is surrounded by a complete or partial black or coloured ring, such as we meet with in a large number of animals.

The visibility of the cribriform fascia which occurs in the Suricate and some of the Ungulates is often found strongly marked in Man as a congenital condition. It does not impair vision.

Lastly, we meet in Man with a disc normal in all respects, save that there is a deep central well-like depression with nearly vertical sides, looking grey by the shadow it causes. This condition occurs normally in the Elephants and in some of the Rodents.

5. *Structures protruding from the Disc into the Corpus vitreum.*

A. *Persistent Hyaloid Artery.*—This congenital defect, which in ourselves is known as the persistent hyaloid artery, is found almost invariably in imperfectly developed eyes (microphthalmos), and very often in triplets and in twins,* in which latter cases the defect disappears about a week after birth. In the lower animals it occurs normally, not only in the Cow, as already pointed out by BRUNS, and notably by HEINRICH MÜLLER, but in *all* the Ruminants and a large number of Rodents. I have found this relic in Man and the Primates occurring in three distinct forms, all of which are rudimentary. The first (see fig. 4, Plate 27) is a short pulsating cœcal vessel filled with blood, which springs from the Arteria centralis retinae, as described by HANNOVER,† BRUNS,‡ LIEBREICH,§ HIRSCHBERG,|| and a number of other writers. The second (fig. 3, Plate 27) is a hollow trumpet-shaped tube, first described by CLOQUET, and known as the Canalis Cloqueti; its base is attached to the disc, and it is free from blood.¶ A third form (figs. 1 and 2, Plate 27) consists of a white dense fibrous cord, which also arises from the disc and terminates either free in the vitreous, or is attached by two or three threads to the posterior capsule of the lens. All three forms have been fully described by various authors.

B. *Vestiges of a Pecten.*—The typically developed pecten of the Sauropsida consists essentially of a vascular network, a basement membrane, and secreting cells, the latter being densely pigmented and thickly covered with black pigment granules. Structurally it presents essentially the same features which we find in the ciliary processes of the choroid, and there cannot be any doubt that its function is similar

* See SCHÖBL and ALT, "Diseases of the Retina," in NORRIS and OLIVER'S 'System of Diseases of the Eye,' vol. 3, p. 420, which contains an admirable account of these and other anomalies and foetal relics.

† 'Das Auge,' 1853.

‡ BRUNS, 'Zeitschrift vergleich. Anat.,' vol 6, p. 77.

§ LIEBREICH, 'Klin. Monatsblätter,' p. 259.

|| 'Centralblatt,' p. 360.

¶ See a remarkable example of this in ALT'S Monograph, Plate 3, p. 422.

to the ciliary processes, viz., to secrete a fluid for the nourishment of the vitreous and neighbouring structures. Its plicated form, so typical in Birds, is a contrivance to provide for a greater secreting surface, as is the case in the ciliary processes of all Mammals.* This plication of the pecten is not, however, an essential characteristic, since the same organ exists in many Reptiles and in some Lizards as a very long vascularised bundle or basketwork stretching far into the vitreous body; in others it is pear- or button-shaped, and short, as in the Chameleons. According to OWEN,† the Apteryx is remarkable as being the only Bird devoid of a pecten, and T. J. PARKER‡ makes the same observation, but adds that he has discovered it in the embryo Bird as a conical pigmented prominence arising from the optic disc 1–2 millimetres in length. This is the only reference to and description of this organ in Apteryx. I have examined ophthalmoscopically an adult living specimen of *Apteryx mantelli*, and find that it possesses a well-developed pecten (fig. 21, Plate 28). Its base is trumpet-shaped, and covers almost the whole of the disc, the margins being moss-like. The process extends nearly as far as the lens in the form of a thick, densely-pigmented brown-black cone without plications. It is quite as large in proportion to the eye as that of many other Birds (*e.g.*, Sparrow, Penguin, Crane). It is a functionally active organ in its most primitive form, and resembles, only much more developed, the pecten which PARKER saw in the embryo. It occupies an intermediate position between the vestigial pectens of various Mammals presently to be described (see especially fig. 20, Plate 28) and the fully developed plicated pecten in Birds.

Rare cases have been described in Man in which vessels have been seen protruding into the vitreous from the arteria centralis or its branches, and also vascular remnants covered with pigment, but the authors have not attempted to explain this occurrence (see Plate 27).

In some of the Rodents, more especially in all the Agoutis, a conical or button-shaped pigmented vascular rudimentary pecten is seen protruding from the centre of the disc into the vitreous, bearing a close resemblance to that seen in the Reptiles (figs. 18, 19, 20, Plate 28). In a number of Marsupials, vascular protuberances from the disc into the vitreous occur in different forms. Thus in the Macropodidæ (figs. 11, 12, 13, and 14) we find a large vascular cushion-shaped protuberance resembling the thalamus of a daisy, and in the Rabbit-eared Perameles (fig. 17) and Rat Kangaroo (fig. 16) we meet with a delicate vascular basketwork resembling that of Chamæleo, while similar forms occur in a number of other Marsupials in a less pronounced degree.

6. *Colobomata*.—Extra-papillary colobomata do not usually occur in animals, but I

* TREACHER COLLINS demonstrated microscopically and experimentally the glandular function of the ciliary processes ('The Pathology of the Eye,' Lectures R. C. S., 1896.)

† "The eye presents a remarkable deviation from the construction which characterises the feathered class, in the total absence of the pecten or marsupium." OWEN, 'Zool. Soc. Trans.,' vol 2, p. 257.

‡ 'Roy. Soc. Proc.,' vol. 42, 1892, p. 397, and Plate 17,

have noticed them in some cases as abnormalities among the domestic animals, especially in the Horse and Pig. The papillary coloboma (FUCHS' Coloboma), on the other hand, due to incomplete closing up of the choroid around the disc, a congenital defect frequent in Man, has its analogy in the white or coloured scleral ring which we normally meet with in a large number of animals.

7. *Retinitis pigmentosa*.—Some observations which I have made in regard to Retinitis pigmentosa, a disease which has been recognised as being of congenital origin,* may prove of interest. It seems generally recognised that Retinitis pigmentosa consists of a peculiar change in the pigment layer of the retina, which commences in the region of the Ora serrata. The pigment gradually invades the retina, spreading insidiously and concentrically over it towards the macula. There where this disturbance of the pigment occurs, which forms so striking an appearance with the ophthalmoscope, the sight disappears concurrently with it, so that the extent of the invasion marks the limit of the visual field.

I have noticed in certain night animals, more particularly in the Galagos and Lorides, a heaping-up of pigment all around the periphery, which, seen with the ophthalmoscope, greatly resembles Retinitis pigmentosa. Exposing a Galago to daylight for some months, I found it to go quite blind; the invasion of the pigment could clearly be seen to advance concentrically towards the posterior pole, as I have seen the disease spread in Man. It is a well-known fact that Bears frequently become blind in captivity, owing to their being too much exposed to light.

Although in cases of Retinitis pigmentosa both day-blindness and night-blindness occur, I thought that these observations on night animals pointed to the possibility of arresting the insidious progress of the disease, of which blindness is the invariable termination, by shielding the eyes from the most active rays of daylight. A few attempts to do this by the use of spectrum-blue goggles—glasses which only transmit the centre of the spectrum, viz., the blue, green, and a portion of the yellow rays—have given encouraging results, and I am therefore persevering in that direction.

8. *Visible Choroidal Vessels and Stippled Choroid*.—It is frequently the case that, when in the human eye the choroidal vessels can be seen with the ophthalmoscope, sight is not normal over the area where these vessels can be discerned. Usually a fundus in which choroidal vessels are visible is not of the normal vermilion colour, but is either orange-pink in light-haired people, or of a dull reddish-brown in the others. In an orange-pink fundus the space between the visible choroidal vessels is somewhat paler and less orange than the rest of the fundus. In reddish-brown fundi the spaces between the choroidal vessels are of various shades of reddish-grey and occasionally dark grey, or nearly black. These extreme cases have been described as Choroiditis, but I think that in many cases they are not due to disease, but to a congenital defect, since sometimes vision is unimpaired. In no case are choroidal

* SCHÖBL and ALT'S Summary in NORRIS and OLIVER'S 'Diseases of the Eye,' vol. 3.

vessels visible over the macula area, not even in Albinos, although they appear very obvious around its margin. All these appearances find their simplest explanation in different degrees of pigmentation of the vascular layers of the choroid. In the most extreme cases the retinal pigment seems to be discoloured and the choroidal pigment absent, so that the black pigment of the Memb. suprachoroidea and the Memb. fusca of the sclerotic can be seen. The pigment of these layers, shining through the sparsely pigmented choroid, accounts for the reddish-greys of different densities observed in other cases. These congenital defects are reversions of type, as already in the Hylobates (the Gibbons) we meet with visible choroidal vessels, and these occur in all the other Simiæ except those that have very dark skins.

In a number of other Orders visible choroidal vessels occur, they being most marked in the Macropodidæ and some of the other Marsupials, which present the appearance of red choroidal vessels on dark grey or black grounds observable in the most extreme cases of the analogous congenital defect in Man.

The stippled appearance which occurs in the Feline Douroucouli and in the Lemurs, is also occasionally met with in Man, frequently accompanied by visible choroidal vessels, and by a greater or less impairment of vision.

9. *Ectropion of the Uvea.*—Dr. STEPHENSON* has given an exhaustive account of the ectropion of the uvea in Man. He concludes :—

“It appears then that ectropion of the uvea may show itself under three forms :—

“1. Nipple-like projections on the pupillary margin.

“2. Pigmented particles lying free in the anterior chamber, and

“3. Cysts formed by the degeneration of such particles.

“It is a matter of common knowledge that anatomical features constant in the lower animals from time to time re-assert themselves in Man.”

Then he mentions, concerning the eye, the opaque nerve fibres, and the persistent hyaloid vessels :—

“Lastly, ectropion of the uvea is a condition natural to the eye of the Horse and allied animals, and when occurring in Man must be regarded as a reversion in type to the anatomical structure of vertebrates lower in the scale of creation.”

I cannot follow him to this extent. As to the nipple-shaped projections from the pupillary margin, which occur as a congenital ectropion of the uvea in Man, they are found normally along the upper and lower margins of the iris in the Horse, and in a large number of other Ungulates (see Plate 29), and they exist to a marked degree around the circumference of the pupil in the Marsupial *Perameles lagotis*. Where such features occur normally, they probably serve a distinct physiological purpose, and I think that such uveal and iridic projections are an additional con-

* ‘Medical Press,’ October 1893.

trivance for protecting the eye against glare. They occur normally in those animals whose horizontally oval pupils contract imperfectly to light, and Hyrax possesses an appendage to the iris of definite shape and structure, and peculiarly active, as already described in Part I., p. 22, and depicted in Plate 29.

A further analogy is the flap of the iris of the Skates, which can be drawn down like a blind to shut the pupil. But all these are scattered cases, although they may have had a wider distribution in the Mammalia; and considering that no normal ectropia occur in the Simiæ or in the Lemurs, we are not justified in looking upon congenital cases in Man as due to ancestral analogy, which of course is no explanation, but it is certain that not every congenital hypertrophy is ancestral.

IV. THE SHAPE AND COLOUR OF THE OPTIC DISC.

In the majority of Mammals the disc is circular, but even within the various orders we meet with certain exceptions. All the Primates, Chiroptera, and Insectivora, Edentata and Marsupials have circular discs. Among the Carnivora we find many exceptions, *e.g.*, Cynictis has a horizontally oval disc, whilst in the Wolf, Jackal, and Foxes we find it lozenge or kidney-shaped. The disc is horizontally oval in most of the Artiodactyls, as well as in all the Equidæ, but we find it circular in the Goat, Camel, Llama, Tapir, Rhinoceros, Elephant, and Hyrax.

The disc lies either on a level with the retina, or is sunk below it, forming a kind of cup, a feature almost entirely confined to the Carnivora and Flying Squirrels. The horizontally oval disc is usually single, but it may consist of two or three lobes, a peculiarity exclusively confined to the Cervidæ. The Sciruidæ are alone in having two entirely distinct forms of disc. The first, which includes the greater number of species, consists of a long thin tape-like disc often club-shaped at the ends, stretched horizontally across the fundus, and considerably above the axis of vision. This reaches its greatest development in the Marmots and Spermophilus, in which it extends to nearly half the width of the eyeball. The second form, which exists in *Sciurus palmarum* and the Flying Squirrels, is circular and depressed below the level of the retina. Lastly, unique among Mammals, and reminding one of certain Birds and Reptiles, is the long vertically oval disc of the Monotreme Echidna. In some few cases the disc is covered with pigment (Cervidæ, Tragula, Cynictis), and it is frequently surrounded by a ring, black in the Primates and green in the Carnivora. In Man and all the Simiæ, the disc is rosy pink or red, while in the Galagos it is black or green.

In the Lemurs, Bats, Rodents, Edentates, Marsupials, and Echidna it is chalky-white, resembling in colour the pathological condition known as White Atrophy.

It is red or pink in all Artiodactyls, excepting Tragula, in which latter the disc is white, but covered with a dense brown moss-like network of pigment. In the Perissodactyla, Hyracidæ, and Elephantidæ the disc is invariably white or cream

coloured, the only exception being the Equidæ, which have red discs with central patches of deeper colour. In the Hedgehog and Mole the disc is bright red.

The greatest diversity of colour prevails in the Carnivora, viz., grey, brown, red, and various shades of buff and white. In the Seal the disc is brown-pink, surrounded by a green ring.

These colours are obviously not due to the capillaries on or below the surface of the disc, to which the pink colour of the human disc is generally attributed. Even with regard to Man it is difficult to accept this explanation. It has never been suggested that the atrophy of the disc coincides with the atrophy of the capillaries, which alone would account for the disappearance of the colour if the usual explanation were correct. Further, when the human disc is viewed ophthalmoscopically by reflected sunlight, the pink disc always appears buff or serum-coloured. The presence of capillaries would still less account for the black or green discs of the Galagos, or the great diversity of colour seen in the discs of the Carnivora.

V. THE SHAPE OF THE PUPIL.

The shape of the pupil in the various orders of Mammalia may be tabulated as follows, in order to save tedious repetition :—

Circular pupils dilating and contracting to a circle :

All the Simiæ.

Chiroptera.

Insectivora.

Most Carnivora, viz. :

Most large Felidæ.

Viverridæ (exc. Cynictis).

Canidæ (exc. Raccoon-like Dog, Lycaon, and Foxes).

Procyonidæ (exc. Herpestes).

Hyænidæ (exc. H. Striata).

Ursidæ (exc. Melursus).

Some Ungulates, viz. :

Elephas, Tapirus, Rhinoceros.

Nearly all Rodents (exc. Coipu, Capybara, some Sciuridæ, Marmots, and Cavidæ).

Edentata.

Marsupials.

Echidna.

Slightly vertically oval pupils :

Lemures and Galagos, Foxes, Raccoon-like Dog, Lycaon, Hyæna Striata,
Melursus, Coypu, Capybara, Spotted Cavy.

Vertical slit-like pupils dilating to a true circle or nearly so :

All remaining Felidæ.
Pinnipedia.

Horizontally oval pupils :

Cynictis, Herpestes.
All Artiodactyls, Equidæ, Hyracidæ, Cetacea, and Sirenia.
Marmots, Viscacha, and a few Sciuridæ.

It will be seen that the pupils of the Cetaceans are horizontally oval, having thus the opposite direction to that of the Pinnipedia.

This fact is possibly indicative of relationship of the Cetacea with the Ungulata, proved sufficiently on other grounds, while the Seals agree with what occurs in the other sub-orders of the Carnivora.

I have found that horizontally oval pupils do not act to mydriatics, myotics, or light with anything like the same rapidity that we find to be the case with vertically oval or round pupils in all the orders other than the Ungulates. The pupils of the latter, whether round or oval, are all remarkably insensitive to light, drugs, or accommodation as compared with most of the other Mammals; nevertheless the pupil of every Mammal is affected by a solution of atropin, at first becoming slightly *contracted* and afterwards *dilating* to its fullest extent.

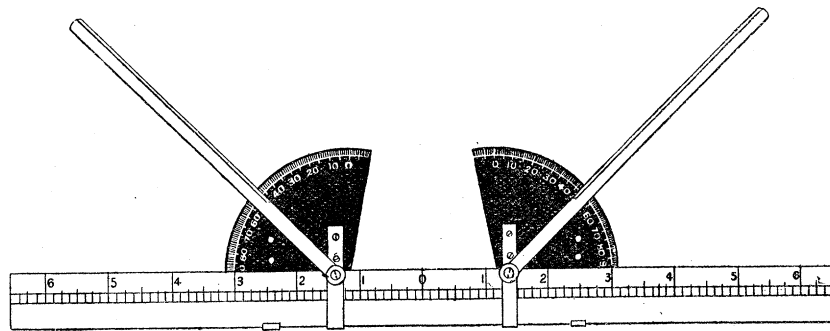
Among the Ungulata we find a number of animals which have pigmented excrescences arising from the upper, and to a lesser extent from the lower, border of the iris, in some cases forming a distinct and symmetrically designed structure, the purpose of which is obviously to diminish the vertical diameter of the pupil, and thus screen the otherwise abnormally large pupil from glare. (See Plate 29.) Reference to this has already been made in the first part of this paper (page 27), as well as under the head of vestigial relics (Part II., Chapter III.).

The shape of the pupil and that of the disc seem to concord to some extent, but the agreement is not such as to warrant the elaboration of a definite rule, except in the case of the Ungulates, where it seems to hold good to a greater extent than in any other order.

It may be added that, unlike the Birds and Reptiles among which we find irides of the most brilliant colour and of every hue, the Mammalia, with the exception of Man, the domestic Cats, some Dogs, and Albinos, have invariably irides of some shade of brown or orange.

VI. DIVERGENCE OF THE OPTIC AXES.

As already remarked, whenever I examined the eyes of an animal, I measured the divergence of the optic axes by means of a special instrument I devised for the purpose. This instrument, shown in the following figure, consists of a bar, on which two graduated quadrants slide, each carrying a movable indicator revolving on it. In order to measure the divergence of an animal's eyes, the instrument was placed on its head immediately above and parallel to the plane passing through the centres of the two eyes. The quadrants were moved so that the pivots of the indicators lay in the optic axes of the eyes. The indicators were then rotated until they lay along the axes, and the degrees read off on each side. The mean between the two readings was taken, and the number of degrees thus obtained indicated the deviation from the median line, or in other words, from parallel vision. If the indicators stood at right angles to the median line (*i.e.*, the line drawn through the vertebral column) the divergence would equal 90° ; if parallel to the median line, the divergence would equal 0° .

GONIOMETER $\frac{1}{3}$ natural size

As already pointed out, the Simiæ, viz., Man and the true Monkeys, alone have the power of convergence, and they alone have parallel vision when the eyes are in a state of rest. No other Mammal in a wild state can converge, but I have seen domestic Cats and Dogs which have been taught, by repeatedly holding food near their eyes, to converge to some extent.

The diagram on Plate 30 shows the chief results obtained. On the left hand will be found the range of divergence between the various members of the orders taken as a whole, whilst on the right details as to families and genera are given. It will be seen from this that the higher the order, the nearer the axis approaches parallel vision, although the range in each is considerable, and each one to some extent overlaps the other. The extensive range observable in the Rodents is in harmony with the great divergence of type in the fundus of that order.

In the Chiroptera, Edentata, and Monotremes, the material examined was necessarily limited.

It seems surprising that Echidna should rank so high in the list of divergences, having only 25° . There can be no doubt that divergence of the optic axes, combined with a large cornea, is a great source of protection to the animals by the increased range of vision it gives them. In Man, who has a medium-sized cornea, the extreme lateral range of vision for the two eyes together is equal to about 165° , and for very bright objects, such as an incandescent light, 175° to 180° . Now in the Hare, Squirrel, and Octodon, which have a divergence of from 80° to 85° for each eye, the field of view must at the very least embrace considerably more than double this latter angle, owing to the very large size of the cornea. I have estimated for the Hare the angle to embrace not less than 190° for each eye, the fields overlapping not only in front but even slightly behind. From experiments made on Squirrels I have proved that they can see an object approaching immediately behind them when the eyes are in the position of rest.

VII. REFRACTION.

When examining the eyes of various animals I have in every case where possible made careful observations of the refraction of the eyes, both by means of retinoscopy and by the direct method with the ophthalmoscope. As it would be wearisome to give the data concerning the refraction of each animal, I shall limit myself to the statement of the general results arrived at.

If we eliminate domestic animals, in which the refraction varies over considerable limits in all directions of error, we find that throughout the Mammalia, with a few notable exceptions, vision is hypermetropic. Myopia is exceedingly rare among animals in a wild state, but it is frequently met with, both with and without astigmatism, among domesticated animals, especially Guinea-pigs, Rabbits, and other Rodents kept in confinement in small hutches. The only other animals in which I have met with it as a persistent character, occurring in every species examined, are those of the genus *Cynocephalus* (Mandrils and Baboons) among the Primates, and the Seals and Sea Lions among the Carnivora. Occasionally I have met with myopia in other animals (*e.g.*, Sooty Mangabey, Syrian Bear, Cape Zorilla, Golden Agouti, Wild Ass, Llama, Dorcas Gazelle, &c.); but as in many cases it may have been accidental and not characteristic of the species, any inference is impossible.

A slight degree of hypermetropia, *i.e.*, under 1 Diopter, may be said to be the rule throughout the higher Mammalia, whilst higher hypermetropia, *i.e.*, 2 D. to 5 D., is found in the wild species of the Rodents, the Edentata, and the Marsupials. *Simple emmetropia is rarely met with; indeed I very much doubt whether it is compatible with sight of a high degree of perfection.* From examination of the vision among a large number of native youths from the Upper and Lower Congo, the Nile Valley, and the Niger Territory, I found that every one with vision beyond the usual standard of $\frac{6}{6}$ or $\frac{6}{5}$ was hypermetropic to at least $\cdot 5$ to $\cdot 75$ Diopter (manifest), an

amount closely corresponding with that found in the great majority of the Primates and Carnivores.

Astigmatism in a small degree, *i.e.*, between .50 D. and 1 D., likewise occurs sporadically throughout the orders; the Simiæ, a number of the Carnivores, and Rodents being practically free from it. On the other hand, it occurs almost universally in the domestic animals, and throughout the Ungulata, the Cetacea, and all Mammals below them.

The eyes of amphibious and marine Mammals are adapted for vision under water in two ways. In the first class, which comprise all the fresh-water amphibious Mammals (*e.g.*, Otter, Beaver, Water Rat), the eye resembles in its refractive power that of strongly hypermetropic land Mammals; but in order to compensate for the loss of the refractive power of the cornea when the eye is submerged, the ciliary muscle is immensely developed, and the accommodative power proportionately increased.

In the eyes of the common Otter (*Lutra vulgaris*), which I carefully measured, I found the astigmatism *nil*, and the manifest hypermetropia 4.5 D.

In the second class, *viz.*, the marine Mammals, not only is the ciliary muscle greatly developed, but there is always a large area of the cornea which is flattened in the horizontal meridian, producing an extraordinary degree of astigmatism. According to MATTHIESEN,* who has examined the different species of Whales common to the Arctic coast of Norway, they all possess corneal astigmatism of between 4 and 4.5 Diopters.

In other marine Mammals, such as the Otariidæ and Phocidæ, I found astigmatism invariably present, as in the Whales, but to a still more marked degree. The common Seal (*Phoca vitulina*) and the Sea Lion (*Otaria jubata*) both have a myopic refraction of 4 Diopters in the vertical meridian and 13 D. in the horizontal meridian, the difference of 9 D. being an amount of astigmatism practically unknown in Man. The pupil of these animals contracts to a narrow vertical stenopæic slit which entirely corrects this difference.

VIII. BINOCULAR VISION.

With the exception of a paper by R. BERLIN,† no attempt has been made to decide whether animals really have binocular vision. He concludes that binocular vision exists because of the faculty of judging distances. This alone would hardly be sufficient evidence. Binocular vision is no doubt a complicated reasoning process acquired from experience, as we can infer from the apparent absence of this faculty in children, and we have no evidence that it is absolutely necessary for accurately judging distances, as animals which have lost the sight of one eye do not seem to be

* 'Zeitschr. für Vergl. Augenheilkunde,' vol. 7 (1893), p. 77.

† "Ueber die Schätzung der Entfernungen bei Thieren," 'Zeitschr. für Vergl. Augenheilkunde,' part 7, 1893, p. 1.

any worse off in this respect. It seems as if all Mammals have binocular vision, but that they do not rely entirely on it.

It is a remarkable fact that, if we except Man and the Simiæ, Mammals very rarely move their eyes for the purposes of vision. When they wish to look in any other direction than the primary one, they move their heads instead. This not only places them in a more favourable position as regards attack or defence, but the movement of the head seems a simpler motion than that of the eyes, so that notwithstanding the high development of the ocular muscles, the former motion is alone resorted to until the stage of convergence is reached, and this is co-existent with the macula. The macula is a peculiar highly-specialised modification of a minute portion of the retina, situated almost exactly in the optical axis and line of direct vision. Ophthalmoscopic examination has proved that Man and all the Simiæ *without exception* possess a macula and a circumscribed macula area (the space bounded by the reflex ring, *vide* Plates 1, 2, and 3), and they are not to be found in *any* other Mammals. Moreover, Man and the Simiæ alone are capable of convergence. It is therefore obvious that since the angle of acute vision only subtends 4° to 5° for each eye, binocular vision for near distances can only be obtained by convergence. From the Lemurs downwards in all the other Mammals, except Simiæ, habitual convergence ceases, and the macula is absent, but in its stead we find a larger *sensitive area*. It is in most cases impossible to depict this area even roughly by means of the ophthalmoscope, since, except in the Ruminants and Carnivora, there is never any alteration in the colour of the fundus, or marked absence of retinal vessels to serve as guides in locating it. CHIEVITZ* examined the eyes of some twenty Mammals, and SLONAKER† has studied others, so that we know the occurrence or absence and extent of the sensitive area in upwards of fifty different Mammals belonging chiefly to the Simiæ, and the more common Ungulates, Rodents, and Carnivores. This list I have been able to supplement by a number of exotic forms.

The Simiæ all have a clearly-defined macula and usually a well-marked circular reflex ring, limiting the macula area, and containing in its centre the foveal pit.

In the Prosimiæ we have on the outer side of the disc, in the position which the macula occupies in the Simiæ, a portion of the retina devoid of vessels. Although this region is of the same colour as the rest of the fundus, the absence of vessels points to its being a sensitive area, larger in extent than the macula region. Where the sensitive area can be in the Bats I am not able to say; nor have I any clue as to where it may be in the Insectivora, although in them there are portions of the retina which are devoid of blood vessels. Among the Carnivora, the Seal, the Suricate, and the Cynictis show no indication of a sensitive area, but in all the other Carnivora the central sensitive area is distinguished by a distinct difference of colour, mostly a dazzling golden-yellow, and by a striking absence of vessels over a distinct zone which

* "Ueber das Vorkommen der Area Centralis Retinæ," 'Archiv für Anatomie,' 1891.

† "Comparative Study of the Area of Acute Vision in Vertebrates," 'Journ. Morph.,' 1897.

lies just above the disc and on the posterior (outer) side of the axis of vision. CHIEVITZ, by microscopic sections, has located the sensitive area of the Seal, the Cat, the Badger, the Marten, and the Dog, as a small round patch immediately posterior (*i.e.*, external) to the optic disc, while in the Common Fox he locates it in the angle formed below the disc by the two descending main vessels. Among the Ungulates, the Suidæ have a sensitive area diagonally across the fundus. This zone, devoid of vessels and discernible with the ophthalmoscope, corresponds to that determined microscopically by CHIEVITZ. In the Selenodonta the sensitive area is well marked on both sides of the disc and immediately above it, bisected by the main ascending artery and vein. In the Cavicornia other than Capra, and in all the Cervicornia, the sensitive area has a distinct "rosy" glow; whilst in Capra, the Camelidæ, and the Tragulidæ, the sensitive area is well marked by the absence of vessels, but there is no distinctive colour. In Capra, I find the area more or less round, and not stratiform as in the other Selenodonta. In the Perissodactyla and the Proboscidæ, no trace of a sensitive area can be seen. According to CHIEVITZ, the sensitive area in the Equidæ forms a broad horizontal band immediately above the disc and peripheral zone. In the Rodents, other than the Leporidæ and the Sciuridæ, we have no indication of a sensitive area. In these two families it extends right across the fundus immediately below the disc. In the Leporidæ we find an absence of vessels over the sensitive area. In the Sciuridæ the sensitive area could be located only by the photophobia, caused by concentrating the light on this particular region, and the increased brightness of the reflex. Photophobia only gives some indication of the sensitive area in the Insectivora and the Edentata, the Marsupials, and the Monotremata, in which it seems to be situated very near the disc, and to be very limited in extent. The distress of the Insectivora and Edentata when I directed the light from the ophthalmoscope close to the disc was especially marked.

To sum up: Sensitive areas of restricted dimensions, omitting those cases in which the area is limited to a macula, exist in the Carnivora, in which order the divergence is not great. In the Ungulates, Rodents, Edentates, and Marsupials, where we find great divergence of axes, large corneæ, and nearly spherical lenses, the sensitive areas are larger, and probably the degree of difference in perception over such areas, compared with the more peripheral parts, is but little marked. This leads to the consideration whether binocular vision is possible without convergence, even in animals with a great divergence of the optic axes. The great extent of their sensitive areas, the shape of the often large pupil—especially the horizontally oval pupil—and the refraction, favour this hypothesis. Hereto comes another fact which I have observed, *viz.*, that the cornea is much larger in those animals which have a divergence of more than 50° or 60° . In addition, these animals have nearly spherical lenses. Evidently these latter facts are of much greater importance than the size of the pupil, as we know by analogy with a camera, that the size of the stop does not affect the field or angle of view, which is solely dependent on the shape of the lenses in the combina-

tion, and their proximity to each other, and to the diaphragm. It is evident that the increased size of the cornea will allow rays of much greater obliquity to be refracted into the eye, and a spherical lens will diminish the distortion produced by the focus of those oblique rays, and that all the more, since the image is received upon a surface nearly equidistant from the nodal points. In our eye, possessing only a small angle of acute vision, a blurred image produced at a point near the periphery is of no consequence, but in the case of those animals which have a widely extended sensitive area and need to see all round them, a sharp focus for peripheral rays is of much greater importance.

IX. PHYSIOLOGICAL CONSIDERATIONS.

It is obviously beyond the scope of this paper to attempt any theory of vision or of colour perception, or even to see to what extent the facts which we have recorded can be brought into harmony with existing views. It will not be possible to do more than call attention, and that only in a very cursory manner, to some few among many points which have specially impressed me in the course of this work.

In referring to a number of our text-books I have been struck with the difference between the explanation given for the ophthalmoscopic appearance and the descriptions of the eye which underlie the theories of vision. In the first instance we are told that the ophthalmoscopic image is due to reflection from the choroid and its vessels, whilst on the other hand we are told that the impinging light is absorbed by the black opaque epithelial layer of the retina. Now it seems to me that reflections from the choroid can only be seen if the epithelial layer is transparent, or at least translucent; and if this is so, the light is not absorbed by the epithelial layer, but we see by reflected and not by incident light, unless it be that both play a part in vision. In the last edition of HELMHOLTZ'S 'Physiologische Optik' the view is expressed that we see both by incident and reflected light; and, according to BRÜCKE, the reflection has the effect, that the light which has struck the sensitive elements of the retina by impinging on them, strikes and affects them again on its return, at least in those eyes, he says, which possess a Tapetum lucidum. Now we have seen that in eyes which have no tapetum, the membrane of BRUCH and the internal layers of the choroid are transparent, and that the epithelial layer is very translucent. We have seen that in eyes which have a Tapetum cellulosum, the inner layers of the choroid are opaque and colourless, the colour being exclusively due to the translucent epithelial pigment crystals. Lastly, we have found that the Tapetum fibrosum consists of certain layers within the choroid which are structurally coloured, the colour being to some extent modified by translucent coloured epithelial crystals. I venture to think that these facts must be taken into consideration in forming any theory of vision or colour perception.

Having had occasion to study the work of LIPPMANN on colour photography, I could not help being struck by the similarity of his device and the conditions which

I found in the eye. He obtained negatives in natural colours by placing a reflecting mirror or mercury trough behind, and in direct contact with the sensitive film of the plate, thus reflecting the light which had passed through the translucent film on to the particles of silver bromide, the colour effect being obtained by interference. In the eye the light seems to pass through the translucent retina (which may be compared to the sensitive film) and to be reflected back by the choroid, or by the Tapetum lucidum, through the sensitive nerve terminals of the retina (which are analogous to the particles of silver haloid). If we venture to carry our analogy still further, we may presume that we owe our colour-sense to interference also. The difference between LIPPMANN'S method and that of Nature, however, is that in the latter the reflecting surface is always coloured, and reflects incident light of different wave-lengths unequally. In ourselves red and orange are reflected to a greater extent than the other colours, and they are certainly the colours we see furthest and best.

Now we have seen that we do not meet with blue or violet in the Fundus oculi except in small patches, but only with the less refrangible colours. In the Bird the pigmented oil globules of the cones are likewise red, yellow, or green, and never blue or violet. The blue structural choroid of the Tapetum fibrosum is always tempered by the overlying retinal pigment, so that in the Ungulates which have this tapetum we do not get blue or violet fundi, with the sole exception of Capra, and even then it is mixed with red or green, so that the fundus is mauve or greenish-blue.

The fact that a very large number of nocturnal animals have golden-yellow, or gold and green, fundi, and that we find green fundi in the Carnivores which prowl at dusk, seems well worth consideration, especially as it is well known, that after nightfall, or in very dim light, all colours lose their distinctiveness and appear uniform, with the exception of yellow and orange.

I am not able myself to bring the colours I have found in the Fundus oculi in harmony with the three-colour theory, although possibly some relation may be found on further investigation.

The existence of a dark peripheral area, a so-called Tapetum nigrum, wherever we have a highly-reflecting Tapetum lucidum, seems to point to the necessity of preventing reflection beyond a certain area in order to avoid blurred images. I very much doubt whether any sight exists over the area of the Tapetum nigrum, especially as the latter never occurs in animals having a high degree of divergence, which is indispensable to a great range of vision.

The specially sensitive area in the animals having a tapetum is invariably found in the central zone, which may have the function of a greatly extended macula.

X. INFLUENCE OF DOMESTICATION.

The eye is no exception to the rule, that domestication greatly increases variability. The colour of the Fundus oculi of the domesticated races differs not only from that of

the wild species, from which these races are supposed to be derived, but the colour varies also individually, an occurrence almost unknown in wild specimens. In the Ungulata, notably the Horse, Ass, Mule, and Cow, the variation is far less marked than in the Carnivora. In the Carnivora, with their dull grey Tapetum cellulosum, the colour of the fundus depends entirely upon the retinal pigment, and this colour is easily susceptible to variation by domestication and interbreeding, whilst in the Ungulata the colour of the fundus is mainly determined by the Tapetum fibrosum which, being choroidal, remains practically unchanged, the altered retinal pigment determining but a slight change of hue.

The Dog shows the greatest amount of variation, in conformity with the almost endless races into which this pliable genus (or perhaps several genera, *i.e.*, Wolves, Foxes, and Jackals) has been modified by domestication and artificial selection. The tabulation of the ophthalmoscopic results, based upon a large number of Dogs, with due regard to their individual pedigrees, might enable us to obtain a reliable guide as to the purity of the breed of any given example.

NICOLAS and FROMAGET* have classed the ophthalmoscopic colour of the Fundus oculi of the Horse according to the colour of the coat of the animal, but their results would probably be more conclusive if the examination were undertaken from the standpoint of racial difference.

The influence of domestication, which is merely forced life under new—often unnatural—surroundings and conditions, is also well indicated by the frequent occurrence of myopia and astigmatism, which we find most prevalent in the Horse, and most marked in the Rabbit, especially if we compare the latter with the high degree of hypermetropia in the Hare. This myopic condition probably receives its explanation in the small dark hutches in which these Rodents are generally confined. Myopia is almost unknown in wild animals, but it occurs in wild specimens which have long been kept in captivity.

XI. THE OPHTHALMOSCOPIC APPEARANCE OF THE FUNDUS OCULI AS BEARING ON CLASSIFICATION.

HAECKEL, in his 'Systematic Phylogenesis,'† remarks that the organisation and development of the eye in the vertebrates is, so far as their phylogenesis is concerned, of very limited interest. With the material at his disposal he could not have come to any other conclusion. Comparative ophthalmology is recent, and no attempt has yet been made to arrange the facts hitherto ascertained with a view to generalisation, and of testing their taxonomic and phylogenetic value. I hope that the observations

* 'Ophtalmoscopie Vétérinaire.' Paris, 1898.

† *Vide* 'Systematische Phylogenie der Wirbelthiere,' ERNST HAECKEL. Berlin, 1895, p. 127.

and conclusions recorded in this paper may serve as a first step in that direction, and that although incomplete they may prove useful.

I am fully aware that no sound classification can be based upon one single organ, but it is also certain that this is the only way in which the taxonomic value of any organ—in our case the eye—can be tested. Comparison with standard classifications will reveal discrepancies, and these will then have to be sifted and accounted for.

The striking concordance which I have found between an attempted arrangement of the Mammalia according to the Fundus oculi, and the most modern classification, renders it worth while to consider the points of difference between them.

Anyone who peruses the first part of this paper and examines the illustrations will, I am sure, agree with me, that the results obtained afford yet another striking testimony in support of the theory of evolution, and the existence of ancestral forms from which the various branches have differentiated.

The leading features presented by the Fundus oculi are : First, the vascularisation. Accordingly, the Mammalia can be grouped into Anangioida, *i.e.*, without vessels, and Angioida, *i.e.*, with retinal vessels, together with an intermediate group, which I propose calling Pseudangioida. Secondly, the existence or absence of a tapetum. Those which have a tapetum can be divided into those having a Tapetum primitivum ; those having a Tapetum cellulosum ; and, lastly, those which have a Tapetum fibrosum.

It is quite understandable and supported by evidence that ancestral, say reptilian, features inherited by the Mammalia as a class, should get lost within some of the various orders of the Mammalia. But it is far less likely that features developed within the class of the Mammalia should get lost. Consequently it is almost absolutely certain that the anangioid disc is primitive wherever we find it, unless indeed there are special reasons which outweigh these considerations. Such seems to apply to the Chiroptera ; although these creatures are so highly specialised, typical Vespertilionidæ occurred already in the Eocene, *i.e.*, at an epoch when the separation into the other main groups or combinations of the present orders had scarcely begun. The eyes of these nocturnal creatures are very small, anangious, and devoid of any traces of higher development, except that they are also without any traces of ancestral vestiges, besides the rather common rudiment of the hyaloid artery.

The following table contains an enumeration of the species examined by myself. They are arranged according to GADOW'S classification, and where differences in the Fundus oculi have been observed to suggest alteration of that classification, these have been underlined :—

PRIMATES.	Simiæ.	Anthropoidæ.	<i>Homo.</i>
			<i>Troglodytes gorilla</i> and <i>T. niger.</i>
			<i>Simia satyrus.</i>
			<i>Hylobates albimanus.</i>

PRIMATES.	Simiæ.	Cercopithecidæ.	<i>Macacus rhesus</i> , <i>M. cynomolgus</i> , <i>M. speciosus</i> , <i>M. sinicus</i> and <i>M. inuus</i> . <i>Cynocephalus porcarius</i> , <i>C. mormon</i> , <i>C. hamadryas</i> and <i>C. flavus</i> . <i>Cercopithecus albigularis</i> , <i>C. diana</i> , <i>C. callitrichus</i> . <i>Cercocebus collaris</i> , <i>C. fuliginosus</i> . <i>Cynopithecus niger</i> .
		Hapalidæ.	<i>Hapale jubata</i> and <i>H. penicillata</i> . <u><i>Chrysothrix sciurea</i></u> .
		Cebidæ.	<i>Lagothrix humboldtii</i> , <i>Ateles ater</i> and <i>A. geoffroyi</i> . <i>Mycetes seniculus</i> . <i>Cebus fatuellus</i> . <i>Nyctipithecus vociferans</i> and <i>N.</i> <i>lemurinus</i> .
	Tarsii.		
	Lemures.	Chiromyidæ.	<i>Chiromys</i> .
		Lemuridæ.	<i>Lemur brunneus</i> , <i>L. coronatus</i> , <i>L.</i> <i>macaco</i> , <i>L. niger</i> , <i>L. variegatus</i> .
		<u>Galagoidæ.</u>	<u><i>Lemur coquereli</i></u> . <i>Nycticebus tardigradus</i> . <i>Loris</i> . <i>Galago garnetti</i> , <i>G. maholi</i> , and <i>G.</i> <i>monterii</i> .
CHIROPTERA.			<i>Pteropus indicus</i> and <i>P. poliocephalus</i> . <i>Vespertilio nattereri</i> .
INSECTIVORA.			<i>Talpa europæa</i> . <i>Erinaceus europæus</i> .
CARNIVORA.	Pinnipedia.		<i>Phoca vitulina</i> . <i>Otaria jubata</i> .
	Fissipedia.	Felidæ.	<i>Felis leo</i> , <i>F. serval</i> , <i>F. caffra</i> , <i>F.</i> <i>domesticus</i> , <i>F. siamensis</i> , <i>F. par-</i> <i>dalis</i> , <i>F. jubatus</i> , <i>F. concolor</i> .
		Viverridæ.	<i>Genetta vulgaris</i> , <i>G. pardina</i> . <i>Paradoxurus typus</i> , <i>P. prehensilis</i> . <i>Herpestes pulverulentus</i> , <i>H. griseus</i> . <i>H. nepalensis</i> . <i>Cynictis penicillata</i> . <i>Suricate tetradactyla</i> .
		Mustelidæ.	<i>Mustela foina</i> , <i>M. putorius</i> . <i>Galictis barbara</i> . <i>Ictonyx zorilla</i> . <i>Meles ankuma</i> , <i>M. capensis</i> . <i>Mephitis mephitica</i> .

CARNIVORA.	Fissipedia.	Mustelidæ.	<i>Lutra vulgaris.</i>		
		Hyænidæ.	<i>Hycena crocuta, H. brunnea, H. striata.</i>		
		Canidæ.	<i>Canis familiaris</i> (very many varieties, e.g., St. Bernard, Poodle, Sky Terrier, Collie, Fox Terrier, Greyhound, Spaniel, Chou-chou, &c.). <i>C. dingo.</i> <i>C. procyonides, C. vulpes.</i> <i>C. lagopus, C. pallipes.</i> <i>C. aureus, C. mesomelas, C. cerdo.</i> <i>C. latrans, C. azaræ.</i> <i>Lycaon pictus.</i>		
		Procyonidæ.	<i>Procyon lotor, ditto albino.</i> <i>Bassaricyon alleni.</i> <i>Cercoleptes caudivolvulus.</i> <i>Nasua rufa.</i>		
		Ursidæ.	<i>Ursus syriacus, U. americanus, U. malayanus, U. ursinus.</i>		
		UNGULATA.	Artiodactyla.	Selenodonta.	<i>Bos indicus, B. taurus.</i> <i>Ovis musimon.</i> <i>Capra hircus, C. dorcas.</i> <i>Cervus porcinus.</i> <i>Rangifer tarandus.</i> <i>Gazella dorcas.</i> <i>Camelus dromedarius, C. bactrianus.</i> <i>Llama peruana.</i> <i>Tragululus javanicus.</i>
				Bunodonta.	<i>Sus scrofa</i> (wild and domestic variety). <i>Hippopotamus amphibius.</i>
Perissodactyla.	Equidæ.			<i>Equus caballus, E. tæniopus, Zebra burchelli.</i>	
	Tapiridæ.			<i>Tapirus americanus.</i>	
	Rhinocerotidæ.			<i>Rhinoceros unicornis.</i>	
	Proboscidæ.			<i>Elephas indicus, E. africanus.</i>	
	Hyracoidæ.			<i>Hyrax dorsalis, H. capensis.</i>	
SIRENIA and CETACEA.					
RODENTIA.	Myomorpha.	Dipodidæ.	<i>Dipus ægyptius.</i> <i>Alactaya indica.</i>		
		Geomyidæ.	<i>Saccostomus campestris.</i> <i>Geomys americanus.</i>		
		Muridæ.	<i>Mus rattus, M. decumanus.</i> <i>Gerbillus pygargus.</i>		

RODENTIA.	Myomorpha.	Myoxidæ.	<i>Myoxus dryas</i> , <i>M. quercinus</i> . <i>Acanthomys cahirinus</i> .
	Sciuromorpha.	Sciuridæ.	<i>Sciurus vulgaris</i> , <i>S. variegatus</i> , <i>S. ludovicianus</i> . <i>Xerus setosus</i> . <i>Arctomys marmotta</i> . <i>Cynomys ludovicianus</i>
		<u>Pteromyidæ.</u>	{ <u><i>Pteromys alborufus</i></u> . <u><i>Sciuropterus volucella</i></u> . <u><i>Sciurus palmarum</i></u> .
		<u>Castoridaæ.</u>	<u><i>Castor canadensis</i></u> .
	Hystricomorpha.	Chinchillidæ.	<i>Chinchilla lanigera</i> . <i>Lagotomus trichodactylus</i> .
		Cavidæ.	<i>Cavia porcinus</i> . <i>Hydrochærus capybara</i> . <i>Cælogenys paca</i> .
		Octodontidæ.	<i>Myopotamus coipu</i> .
		Dasyproctidæ.	<i>Dasyprocta agouti</i> . <i>D. azaræ</i> . <i>D. isthmica</i> .
		Hystricidæ.	<i>Sphingurus prehensilis</i> . <i>S. villosus</i> .
	Lagomorpha.	Leporidæ.	<i>Lepus cuniculus</i> . Do. albino. <i>Lepus europæus</i> .
EDENTATA.		Dasypodidæ.	<i>Dasypus villosus</i> .
		Myrmecophagidæ.	<i>Myrmecophaga jubata</i> .
		Bradypodidæ.	<i>Bradypus tridactylus</i> .
MARSUPIALIA.	Diprotodontia.	Phascolomyidæ.	<i>Phascolomys wombat</i> .
		Macropodidæ.	<i>Dendrolagus inustus</i> . <i>Macropus rufus</i> , <i>M. melanops</i> <i>Petrogale penicillata</i> . <i>Halmaturus brachyurus</i> . <i>Hypsiprymnus rufescens</i>
		Phalangistidæ.	<i>Phalangista vulgaris</i> . <i>P. fuliginosa</i> . <i>Belideus sciurus</i> . <i>Petaurus sciurus</i> .
	Polyprotodontia.	Didelphidæ.	<i>Didelphys virginiana</i> .
		Dasyuridæ.	<i>Dasyurus ursinus</i> .
		Peramelidæ.	<i>Perameles lagotis</i> . <i>P. obesula</i> .
MONOTREMATA.		Echidna.	<i>Echidna hystrix</i> .

Considering that a linear arrangement of the various Mammalian Orders is unnatural, but has of course to be adopted in book-form, and stereometric arrangement being out of the question, I am able to draw attention to only a few points.

The Edentata certainly retain their low position at the bottom of the Placentalia now usually assigned to them, and they also share this low position with some of the Rodentia. The characters of the Fundus oculi are another justification of the low position assigned to this order by HÆCKEL and GADOW. Almost as low, forming thereby a third main branch of the Placentalia, are some of the Ungulata in the wider sense, notably Hyrax, Elephas, and the Perissodactyls, whilst the Artiodactyls stand decidedly higher. It is only surprising that the Bunodont group of the Artiodactyls also assumes a rather high position, lower of course than the Ruminants, but decidedly more advanced than the Perissodactyls. This is perhaps less surprising than it may appear at first sight, if we consider the fossil relations of the Perissodactyls, like the Litopterna and Condylarthra, lead to very primitive conditions.

The cases of disagreement are wonderfully few. They are restricted to the following:—

Chrysothrix leans towards the Arctopithecii, but since its dentition and cranial characters are distinctly Platyrrhine, the aberrant fundus must be due to a case of convergence. I find it necessary to separate the Galagos from the rest of the Lemurs, at least as a sub-family, but preferably as a family.

In the troublesome grouping of the families of the smaller Carnivores it is advisable to establish a separate family, viz., *Cynictidæ*, to include the otherwise Viverrine genera *Cynictis* and *Galictis*, together with *Mephitis*, hitherto placed with the *Mustelidæ*. The *Sciuromorpha* should be divided into *Sciuridæ* and *Pteromyidæ*, and *Castor* should decidedly be removed into the *Hystriomorpha* group, perhaps into the vicinity of the *Octodontidæ*. The *Chiroptera* have already been discussed on page 13, Part I. Among the *Marsupials*, the *Diprotodontia* are decidedly lower than the *Polyprotodontia*, chiefly on account of the high degree of development of the eyes of the *Didelphidæ* and *Dasyuridæ*; and this arrangement is quite justifiable upon other grounds, cf. the *Phalangers* and the *Epanorthidæ*, of which recently a living genus has been discovered. It is very probable that the *Polyprotodontia* and *Diprotodontia* are really two rather divergent groups of equal age, and that notwithstanding the reduction of the lower incisors, the *Diprotodontia*, at least so far as the eye is concerned, assume the lower rank.

Since we meet with genera of the lowest type in several of the main groups of Mammals, along with others of the highest type of retinal vascularisation, and again some without, and others with, the additional relic or specialisation of a tapetum, it follows that the details of the vascularisation and of the tapetum have been developed independently in the various main branches of the *Mammalia*. These characters are of too recent a date to be employed as a clue to the mutual relationships or the convergent descent of the various orders, but they are, like the whole Fundus oculi, an

additional striking illustration of the working of progressive evolution, an example all the more valuable since it illustrates the direct modifying effect of external factors upon a most complicated organ, in the present case the subtle influence of light upon the eye.

DESCRIPTION OF THE PLATES.

N.B.—In order that the coloured drawings should more closely resemble the appearances seen with the ophthalmoscope, it is better to examine them in brilliant artificial light.

PLATE 1.

1. Fundus oculi (left eye) of a dark-haired English girl, *æ*t. 20. The mottled choroidal stroma can be indistinctly seen in the background. Translucent fibres of the optic nerve can be traced a short distance beyond the disc. The circular macula area is sharply defined, and surrounded by a reflex ring. Reflexes which vary with the direction of the entering light, and position of the observer's eyes, can be traced along the vessels.

2. Fundus oculi (left eye) of a Nubian youth, *æ*t. 17. The fundus is of a chocolate colour, and the reflexes are very pronounced, extending over the whole central area. The translucent nerve fibres can also be traced for a much greater distance beyond the disc. The macula is circular and well defined, and surrounded by a brilliant reflex ring. The choroidal vessels are quite invisible.

PLATE 2.

1. Fundus oculi (left eye) of a Chimpanzee. The resemblance between this drawing and that of the Nubian youth is most striking. Beyond the facts that there is less differentiation of colour between the retinal arteries and veins, and that the vessels branch out somewhat straighter, no differences can be detected.

2. Fundus oculi (left eye) of the White-handed Gibbon. The nerve-fibre layer and reflexes are prominent. The macula area is very small. The brown choroidal stroma covered with black dots can be seen outside the central area, where it is obscured by the reflexes. On all sides bifurcating choroidal vessels radiate from the vicinity of the disc, and can be traced to the periphery of the field.

PLATE 3.

1. Fundus oculi (left eye) of a Macaque. The background is without dots, and the choroidal vessels are arranged as in the Gibbon, only they are much fewer in number. The macula resembles that of man.

2. Fundus oculi (left eye) of a Black-eared Marmoset. The fundus is slate-coloured and the choroidal vessels few and interrupted. The macula is peculiar, being very

large and surrounded by a prismatic reflex ring, yellow inside, and bluish-green externally. This peculiarity is also observed in the *Chrysothrix*.

PLATE 4.

1. Fundus oculi (left eye) of a Black-headed Spider-monkey. Though this is a New World monkey its eye closely resembles that of the Macaque, showing that the eye does not admit of any pronounced demarcation between the catarrhine and platyrrhine *Simiæ*.

2. Fundus oculi (right eye) of the Lemurine *Douroucouli*. The macula is present, but the macula ring has disappeared. The whole background is covered with dots, as in the case of the Lemurs, to which this fundus bears a close resemblance, were it not for the presence of a macula and a pink disc.

PLATE 5.

1. Fundus oculi (right eye) of the Common Lemur. The macula, as in all animals below the true monkeys, is entirely wanting; but its apparent position is indicated by the absence of the large retinal vessels and all choroidal vessels over a certain area. The disc, as in all Lemurs, is chalky-white.

2. Fundus oculi of MONTEIRO'S Galago. We have evidently here already a *tapetum lucidum* and a *tapetum nigrum*, similar to those common to the carnivora. The background resembles burnished gold, and can only be feebly imitated in the drawing. If a brilliant light be focussed on it by means of a large lens, it will give a better idea of the original. The golden background is strewn over at regular intervals with stellate dots. The disc is dark grey, approaching black. The entire periphery of the fundus is covered with a dense network of pigment.

PLATE 6.

1. Fundus oculi of the Australian Fruit-bat. The entire fundus is uniform in colour and appearance, and very primitive. The colour is light terra-cotta, uniformly covered with large round dark dots, which viewed with the ophthalmoscope might be taken for deep pits. The disc is circular and greyish-white. There are no vessels of any kind visible, except a single minute capillary in the centre of the disc.

2. Fundus oculi of a Common Hedgehog. The background is uniformly light grey. The disc is small, circular, and pink. From this two sets of vessels proceed, viz., a peripheral set, which emerge from its edge in the form of five branches of minute capillary threads, and a central set, consisting of five large retinal vessels, which radiate to the periphery like the arms of a Starfish. There are no choroidal vessels visible, nor can the arteries be in any way distinguished from the veins.

PLATE 7.

1. Fundus oculi of the Common Seal. The background is of a brilliant pale yellow colour, sprinkled with minute green dots. The disc is pale brownish-red, surrounded by a green border. About a dozen thin vessels curl over its margin, and radiate to the periphery. There is no distinction between arteries and veins.

2. Fundus oculi of the Serval. The three zones common to nearly all the Fissipedia are seen. The innermost zone occupies roughly the third of the area of the circle. It is the area of best vision, and lies around the visual axis. It is light gold in colour and of extreme brilliancy. This golden layer is completely surrounded by an emerald-green layer of variable width, and this again by a dense brown-purple layer, which extends on all sides beyond the periphery of the field to the Ora Serrata. This last layer is probably insensitive to light.

PLATE 8.

1. Fundus oculi of the Common Genetta. The golden central layer is situated much higher up than in the last animal. The intermediate green layer is very thin, and the peripheral layer dark red in colour.

2. Fundus oculi of LEVAILLANT'S Cynictis. The fundus is uniform in colour, possessing no differentiated zones, a peculiarity which distinguishes the Cynictis and the Suricate from all other Carnivora. The disc is horizontally oval and of abnormal size. It is covered with a pigmented reticulum.

PLATE 9.

1. Fundus oculi of the Striped Hyæna. The central golden zone is high up above the disc, as is seen in all species of Hyænas, and the pale green zone is very broad. The peripheral zone is delicate mauve in colour.

2. Fundus oculi of a Jackal. The golden zone is very large, and the green zone correspondingly narrow. It is bordered externally by a narrow violet zone, which fuses with the deep brown-purple peripheral zone. The disc is bright pink and lozenge-shaped, a shape peculiar to the Jackals and Foxes.

PLATE 10.

1. Fundus oculi of the Tayra. The fundus is green, and mottled all over with irregular patches of orange-gold. The peripheral area is of a rich brown colour.

2. Fundus oculi of the Canadian Skunk. A most remarkable fundus. The sensitive area of vision extends from the level of the disc upwards. The peripheral zone is very broad and of a yellow-buff colour, stippled with light brown dots.

PLATE 11.

1. Fundus oculi of the Raccoon. The pale golden-yellow zone is mottled and covered with green dots, while the green zone has a number of rice-shaped yellow spots scattered over the field. The peripheral zone is partly mauve and partly brown in colour.

2. Fundus oculi of a Black Bear. The resemblance to that of the Raccoon is very striking. The yellow zone is absent, and the peripheral zone has no mauve or purple fringe, but uniformly brown, resembling that seen in the outer part of the peripheral zone of the Raccoon. The pigment has a crystalline appearance and is patchy, resembling coarse sugar strewn over the fundus.

PLATE 12.

1. Fundus oculi of the Indian Ox. The fundus is characteristic of nearly all Ruminants. The disc is horizontally oval and very large, with a central circular depression. The main trunks consist of one large pair (artery and vein) which runs straight up from the disc giving off horizontal branches from time to time, and numerous lateral and descending trunks, which ramify over the dark peripheral zone. Just above the disc, and extending in a horizontal manner on either side, is a rose-coloured band, nearly free from large vessels. It is probably the seat of acute vision.

2. Fundus oculi of the Hog Deer. The disc is remarkable, apparently consisting of three separate discs fused together. From the centre of each of these "discs" an arterial trunk proceeds, accompanied by its vein. The semi-opaque nerve fibres are very prominent and coarse, otherwise it resembles the fundus of the Ruminants.

PLATE 13.

Fundus oculi of the Bactrian Camel. The fundus is uniformly chocolate-red in colour, the lower portion appearing paler, owing to the innumerable radiating nerve fibres. The disc is white, circular, and covered with a network of pigment. The main trunk ascends, intertwining with its vein, and gives off oblique and horizontal branches.

PLATE 14.

1. Fundus oculi of the Java Chevrotain. The surface of the disc is entirely masked with dense moss-like pigment, and is surrounded by a green border. The retinal vessels are so much in front of the choroidal background that they cast distinct shadows on it.

2. Fundus oculi of a Wild Boar. The veins and arteries are of immense calibre, and indistinguishable from one another in colour. The fundus is of a uniform slaty-

pink colour without any peripheral zone. Semi-translucent nerve fibres radiate in all directions from the disc. None of the Suidæ possess a tapetum lucidum.

PLATE 15.

1. Fundus oculi of the Indian Rhinoceros. The fundus is mottled and of a uniform brown colour. The disc is chalky-white. No retinal or choroidal vessels are visible anywhere. It is a type of a very primitive fundus.

2. Fundus oculi of BURCHELL'S Zebra. The size and appearance of the disc and the retinal vessels are identical with those in the horse, but the sensitive area of vision is different, consisting of a coarse golden network, the spaces being filled up with pale green. The peripheral area is dense, mottled with light and dark patches of purple.

PLATE 16.

1. Fundus oculi of the American Tapir. Besides the Elephant this is the only Ungulate which possesses a yellow or golden fundus. The peripheral zone is reddish-orange. The disc is white, and the retinal vessels are reduced to a few capillaries which extend across the disc.

2. Fundus oculi of the African Elephant. The fundus is of a uniform pale straw-yellow colour, and covered with an immense number of peculiar irregular or bent brownish rod-like patches. The disc is large, circular, and grey, like a grey atrophied disc in man. The retinal vessels are limited to six or seven minute vessels, which spread a short way beyond the margin of the disc. There is no peripheral zone.

PLATE 17.

1. Fundus of the Dorsal Hyrax. Although the colour of the fundus is different from that of the Elephant, nevertheless it presents many points of resemblance. Both have a uniform background without any peripheral zone, covered with peculiarly shaped patches. Both have a circular grey disc, and a very primitive vascular supply.

2. Fundus oculi of the Indian Alactaya. The vascular supply, as in most of the higher Rodents, is very complete. The translucent nerve fibres are conspicuous, and the disc imperfectly defined. From its centre is a pigmented body, which projects into the vitreous, and from its summit a white fibrous cord passes to the lens.

PLATE 18.

1. Fundus oculi of the British Black Rat. The fundus is uniformly grey in colour. The veins are much larger than the arteries, and both radiate from the centre of the disc like the arms of a Starfish. The main arterial trunks alternate with the veins.

2. Fundus oculi of the Common Squirrel. The disc is of an enormous size for so small an eye. This is, with few exceptions, the case in all the Squirrels. It is placed well above the axis of vision. The retinal vessels are bright scarlet, and remarkable for their size and number, and there is no distinction between arteries and veins.

PLATE 19.

Fundus of the Red and White Flying Squirrel. The central area is of a brilliant golden-yellow, covered over with stellate dots. The circular and radiform distribution of the vessels found in the Flying Squirrels and the Palm Squirrel distinguishes them from the other Squirrels and Marmots.

PLATE 20.

1. Fundus oculi of the Canadian Beaver.
2. Fundus oculi of the Chinchilla. The fundus in each of these animals is almost identical, except that the former has a peculiar conical prominence projecting from the centre of the disc (see Plate 28).

PLATE 21.

1. Fundus oculi of the Guinea-pig. The choroid is covered with a peculiar concentric mottling. The disc is white, irregular in outline, and has also a central conical protuberance. (See Plate 20, fig. 1, and Plate 28.)
2. Fundus oculi of the Central American Agouti. The disc is remarkable, as a vascular and pigmented "pecten" is seen protruding into the vitreous from its centre. A similar pecten, though varying in detail, was seen in all the species of Agouti examined.

PLATE 22.

1. Fundus oculi of the Brazilian Porcupine. The fundus is most primitive, as is found the case in most animals which are specially protected from injury by nature. No peripheral area, and no trace of retinal vessels, exist. (*Cf.* Plate 15, fig. 1, and Plate 23, fig. 1.)
2. Fundus oculi of the common Silver-grey Rabbit. The disc together with its dense brush-like opaque nerve fibres are placed well above the area of best vision, which lies in a horizontal plane intersecting the optic axis. The retinal vessels also lie out of the way of vision, being placed in the centre of the nerve fibre bundles.

PLATE 23.

1. Fundus oculi of the Hairy Armadillo. A very primitive disc closely resembling that of the Porcupine.

2. Fundus oculi of the Wombat. The chocolate background is covered with interrupted varicose choroidal vessels. The disc is pinkish-white, and covered with a capillary network of vessels proceeding from the central artery of the retina. No other retinal vessels are present.

PLATE 24.

1. Fundus oculi of the Rufous Rat-kangaroo. The stroma of the choroid is of a mottled brown colour, covered everywhere with radiating choroidal vessels of uniform calibre, which anastomose in festoon-like fibres around the disc. The disc is yellowish-white in colour, and a peculiar basket-like vascular prominence derived from the arteria centralis passes into the vitreous. (See Plate 26, fig. 1.)

2. Fundus oculi of the Squirrel-like Phalanger. The fundus is reddish-orange, covered with a mottling of red patches; the disc is yellowish-white, partly obscured by a capillary network of vessels. There is no peripheral zone.

PLATE 25.

1. Fundus oculi of the Virginian Opossum. It is remarkable for possessing a golden central zone, which is surrounded by a peripheral zone densely pigmented. It also possesses a grey disc and well-developed retinal vessels.

2. Fundus oculi of the Tasmanian Devil. The fundus is of a deep Indian red colour faintly mottled with pigment. The disc is greyish-white, and the retinal vessels are numerous and large. Semi-opaque fibres are present, one set accompanying the main ascending trunks for some distance.

PLATE 26.

1. Fundus oculi of the Rabbit-eared Perameles. The arrangement of the nerve fibres is exceedingly curious, resembling a white aster. The fibres are not semi-transparent as in most animals, but semi-opaque; although not to such a degree as in the case of the Rabbit and Hare. The arteria centralis retinæ terminates in a basket-like anastomosis of fine vessels, and resembles that seen in the Chameleon, except that the former is destitute of pigment cells or granules.

2. Fundus oculi of the Echidna. The background and the disc resemble that of many of the day-feeding birds, but the disc differs from all birds in being entirely destitute of a pecten. The whole eye is extremely primitive in structure.

PLATE 27. (See pp. 53-54.)

Four drawings of the human Fundus Oculi to illustrate the three main forms of the persistent Hyaloid Artery.

- Fig. 1. The hyaloid artery is seen as a white cord arising by a broad base covering the entire disc and even projecting beyond it in the form of fine fibrous filaments. The distal portion is split up into three cords, which could be seen in contact with the lens capsule. (Drawn from life.) $\times 10$ diam.
- Fig. 2. A similar case, arising from the centre of the disc and projecting to the lens as a single cord. (Drawn from life by the author.)
- Fig. 3. The hyaloid artery free from blood is seen arising by a hollow trumpet-shaped tube from the disc, the tube passing forwards towards the disc to end in a tiny trumpet-shaped mouth affixed to the lens capsule, and known as the *Campanula Halleri*. In this drawing it is lying free in the vitreous. (Copied from a drawing by SCHÖBL, in NORRIS and OLIVER'S 'System of Diseases of the Eye,' vol. 3, p. 422.)
- Fig. 4. The hyaloid artery is in the form of a sausage-shaped cœcal vessel arising from the main trunk of the *Arteria centralis retinae*. It was filled with blood, and pulsated with the trunk vessel. Its closed end projected into the vitreous. (Drawn from life by the author.)

PLATE 28. (See pp. 24 to 54, *passim*.)

Illustrating the primitive and retrograde forms of the Pecten and Hyaloid Artery occurring in the Mammalia.

- Fig. 1. The persistent hyaline artery in the Reindeer.
It is found as a white cord reaching from the disc to the lens, to the capsule of which it is attached by one or more fine threads.
- Fig. 2. A similar cord seen in many of the Rodents.
In this case it ended in a small button or hollow cone (*Campanula Halleri*).
- Fig. 3. The arteries branch out from the main trunk, forming a series of arches above the disc. From the top of this a pigmented process projects into the vitreous, and is continued to the lens as a fine cord (*Jerboa*).
- Fig. 4. A circular depression occupying a third of the diameter of the disc. I found it in all the Elephants examined.
- Fig. 5. A similar depression, but much shallower; repeatedly found in *Bos*.
- Fig. 6. An oat-shaped white process arising from the main trunk and penetrating into the vitreous (*Ovis musimon*).
- Fig. 7. A glistening white fibrous process arising from a broad base from the bloodless disc (*Pteropus*).
- Fig. 8. A white stunted process of fibrous tissue arising from the base of a pit in the centre of the disc of *Castor*.
- Fig. 9. A long stiff fibrous process ending in a club-shaped knob arising from several similar roots attached to the margin of a deep pit (*Sciurus palmarum*).

- Fig. 10. A pointed fibrous process arising from the main trunk (*Gerbillus*).
- Fig. 11. A deeply pigmented black process penetrating the vitreous and arising from the centre of a slightly-elevated cushion covered by innumerable fine blood vessels which cover the disc (*Macropus rufus*).
- This and the remaining illustrations represent various degrees of development of the vestigial pecten.
- Figs. 12, 13, and 14. Similar cushions covered with fine vessels.
- Fig. 15. A basketwork of vessels arising from a depression in the centre of the disc, and partly covering one side of it (*Coipu*).
- Fig. 16. A coarse vascular basketwork arising from the central artery. Numerous arterial twigs ramify over the disc (*Hypsiprymnus rufescens*).
- Fig. 17. A similar network (*Perameles lagotis*).
- Figs. 18, 19, and 20. Protuberances containing all the elements of a true pecten, viz., large pigment cells, pigment granules, basement membrane, and a network of blood-vessels (*Agouti*).
- Fig. 20 shows a pecten formation closely resembling that of the *Apteryx*.
- Fig. 21. A true pecten, but without plications (*Apteryx Mantelli*).

PLATE 29. (See pp. 22, 27, 56-59.)

Types of the Appendages to the Iris occurring in the Ungulates, to illustrate the successive stages from the *Corpus nigrum* seen in the *Equidæ*, to the functionally active *Umbraculum* which exists in the *Hyrax*.

The drawings are all taken from life, and the natural size.

- Fig. 1. The *Corpus nigrum*. A simple hypertrophy of the under or pigment layer of the iris. It is most developed along the upper edge of the pupil (*Equus caballus*).
- Fig. 2. A *Corpus nigrum*, similar in structure, but much thicker and larger (*Equus tæniopus*).
- Fig. 3. Three well-formed symmetrical nodules formed by an outgrowth of both layers of the iris, the pigment being hidden by the upper layer of iris fibres.
- Fig. 4. A similar contrivance, only more highly differentiated. The iris itself projects over the pupil, and is beautifully marked with stripes in the Wild Goat (*Capra dorcas*).
- Figs. 5 and 6. A further elaboration of the two layers of the iris, forming a series of ridges and hollows, which interlock with the lower set when the pupil is fully contracted (*Camelus*, *Llama*).
- Figs. 7 and 8 (*Hyrax*). The most highly developed of all iritic appendages, forming a highly contractile structure, which I have named the "*Umbraculum*," since it shields the eye from glare. It arises 2 millims. from the free edge of the iris

by numerous elastic (muscular?) fibres, which radiate out like a fan to be inserted into a narrow band of fibres which run round the free margin of the umbraculum. On either side of its origin is a horizontal slit. These vary in size as the umbraculum lengthens or shortens. It appears to be under the control of the will, as it moves freely, independently of the amount of light. Its surface is directed obliquely forwards, forming an angle of from 30° — 50° with the vertical, and its apex can be retracted almost out of the way of the pupil, or extended so as to nearly meet the lower border of the iris, or inclined so as to touch the posterior surface of the cornea (see p. 27).

PLATE 30.

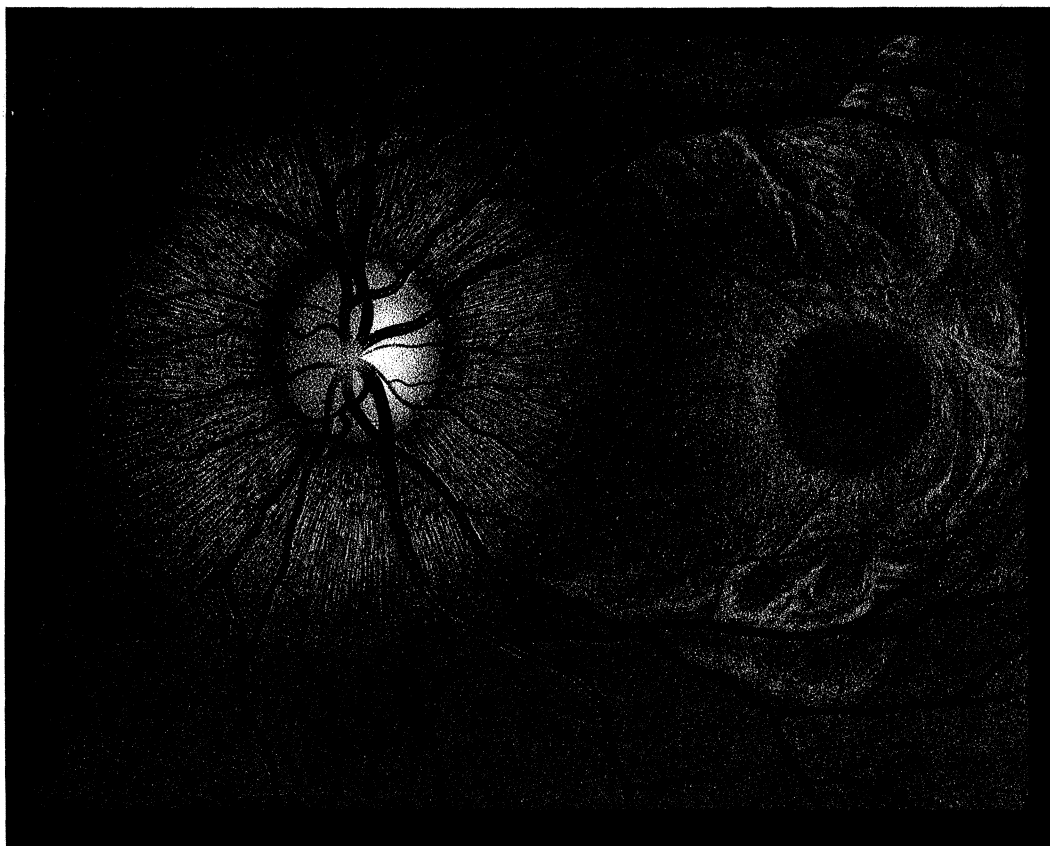
Diagram showing the Divergence of the Optic Axes, referred to in Part II., Chapter VI., p. 60.

A. SIMIAE

I. PRIMATES
a. CATARHINAE

ANTHROPOIDAE

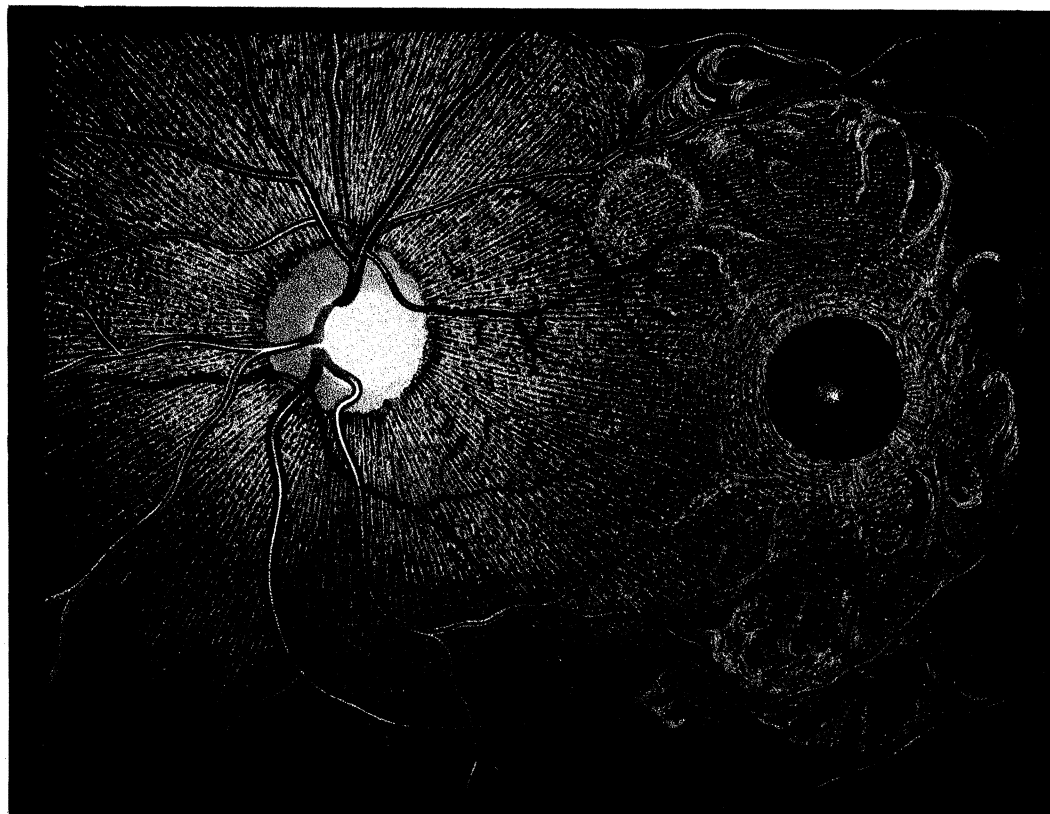
1. HOMO



HOMO.

DARK-HAIRED EUROPEAN.

1. HOMO.



HOMO.

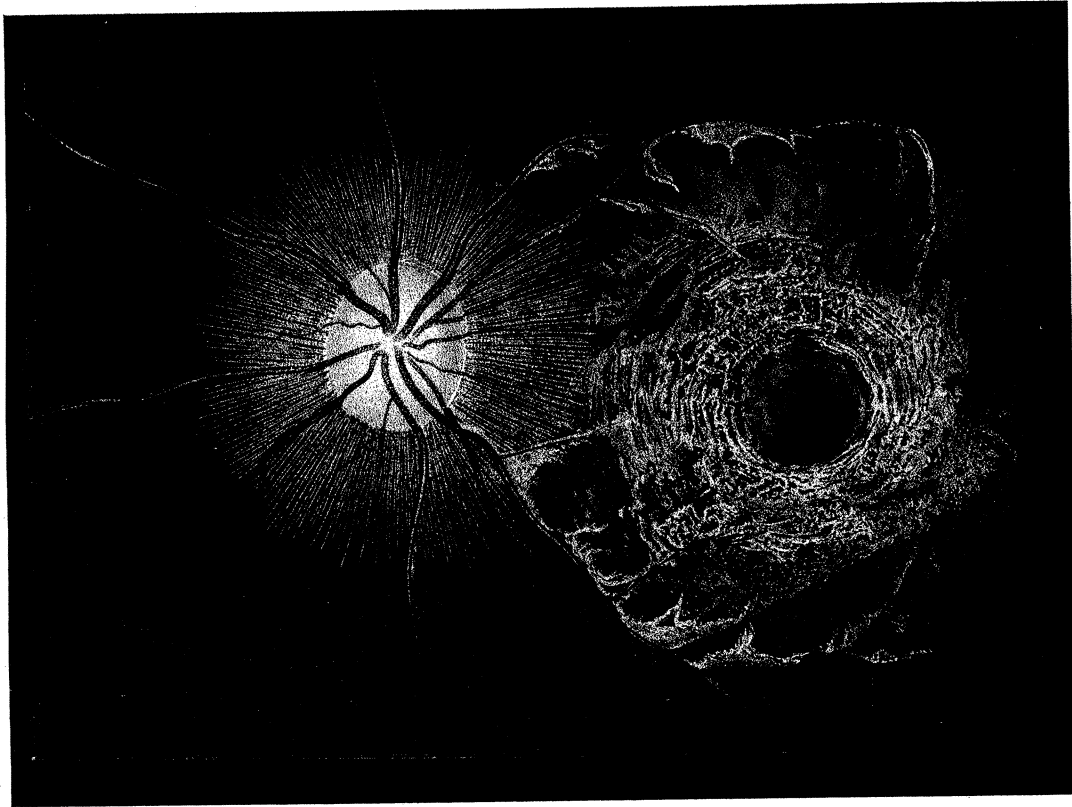
NUBIAN YOUTH.

A. SIMIAE.

1. PRIMATES.
a. CATARHINAE.

ANTHROPOIDAE.

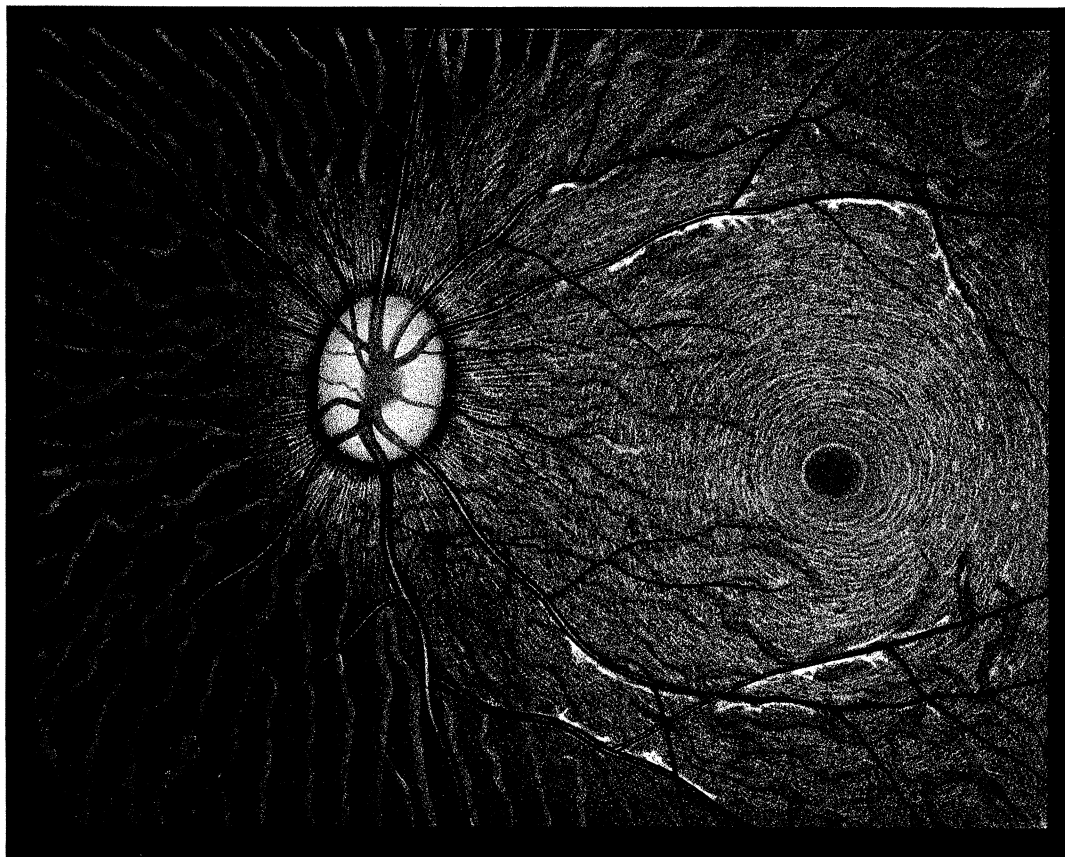
2. TROGLODYTES.



T. NIGER.

CHIMPANZEE.

4. HYLOBATES.



H. ALBIMANUS.

WHITE HANDED GIBBON.

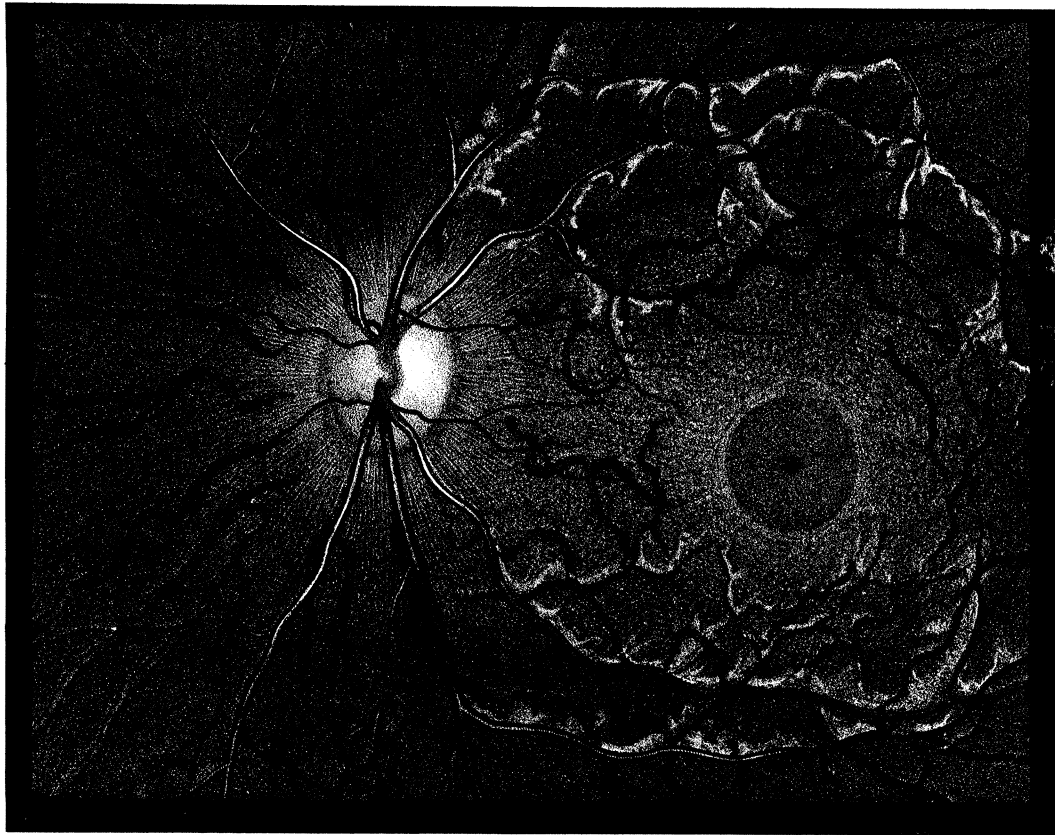
I. PRIMATES.

A. SIMIAE.

a. CATARHINAE.

b. CERCOPITHECIDAE.

1. MACACUS.



M. CYNOMOLGUS.

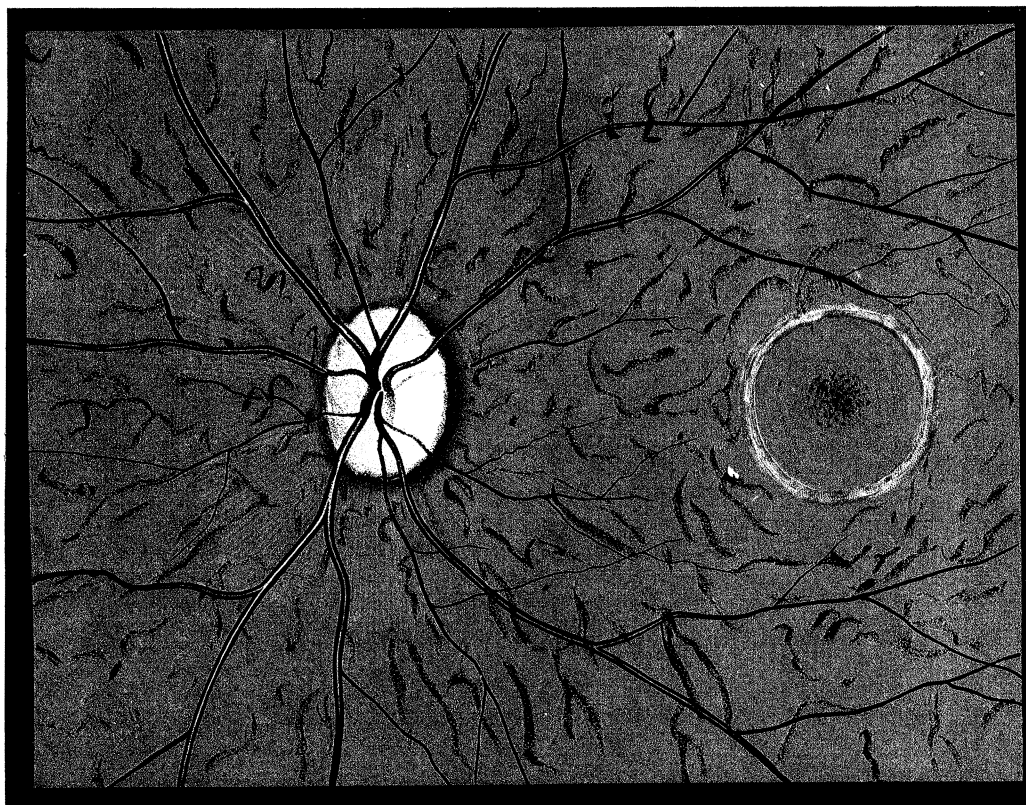
MACAQUE.

A. SIMIAE.

b. ARCTOPITHECI.

HAPALIDAE.

HAPALE.



H. PENICILLATA.

BLACK-EARED MARMOSET.

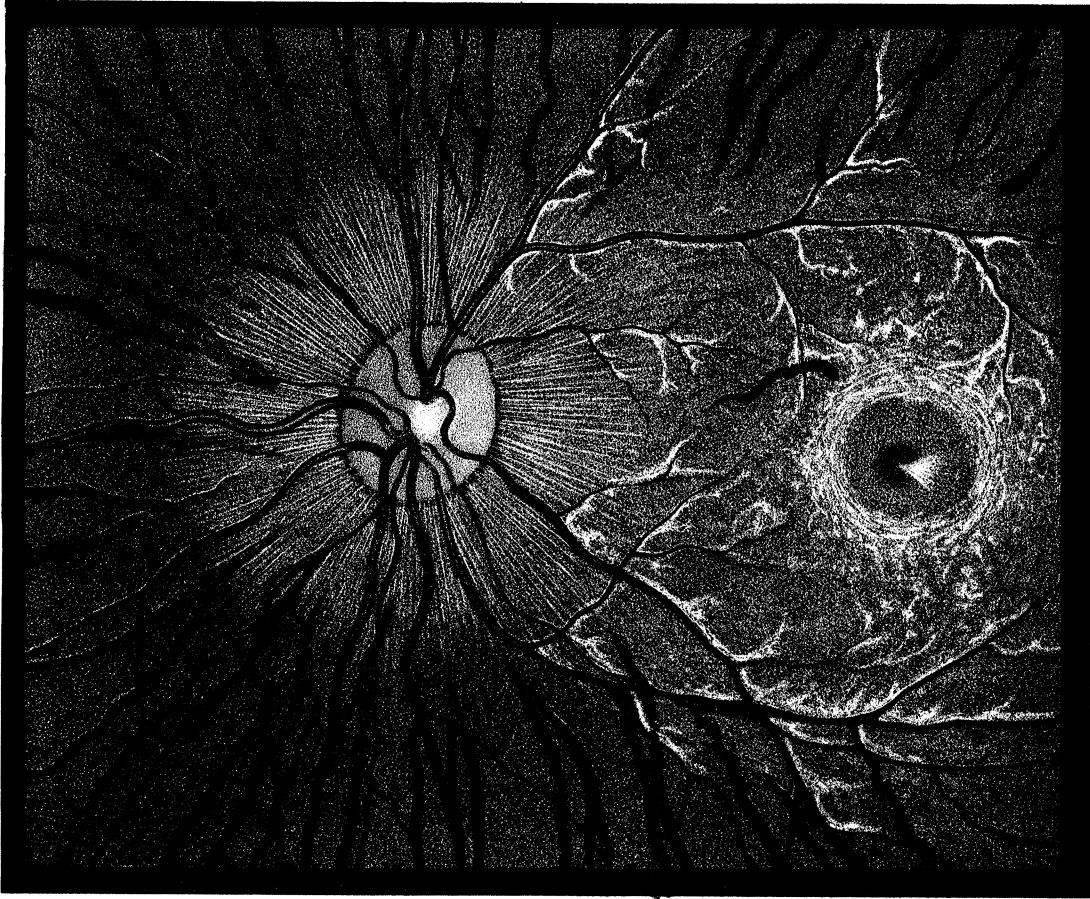
I. PRIMATES.

A. SIMIAE.

c. PLATYRHINAE.

CEBIDAE.

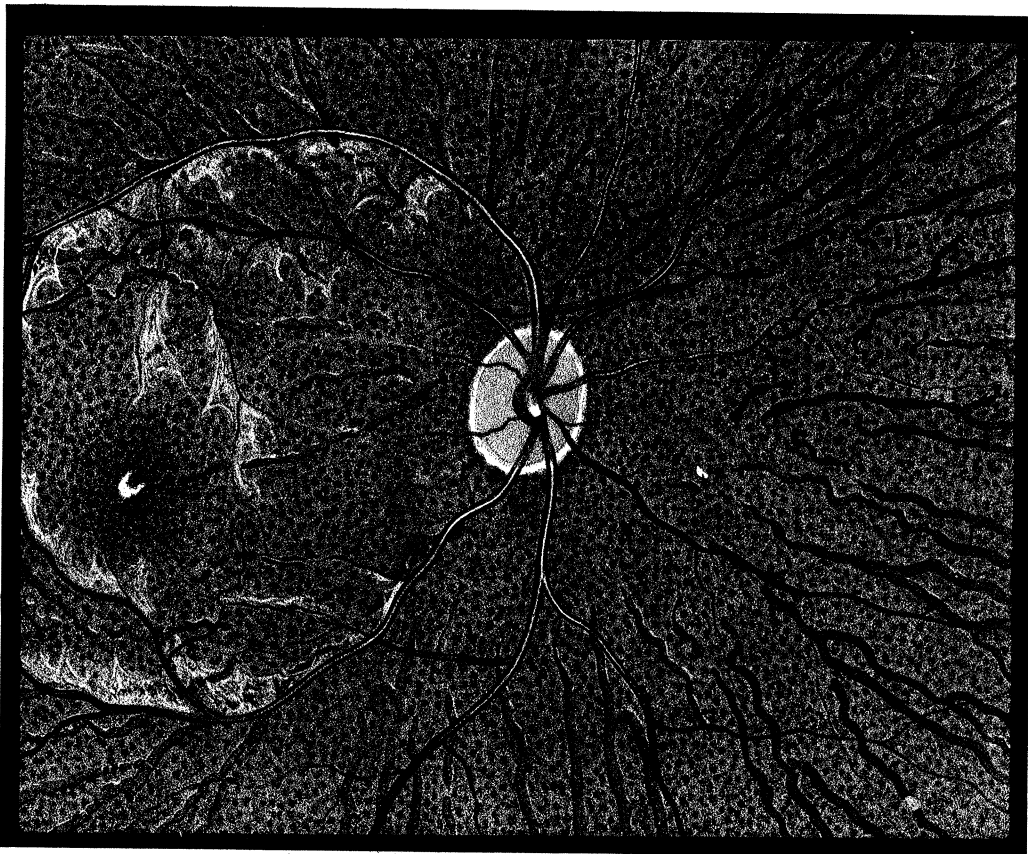3. ATELES.



A. GEOFFROYI.

BLACK HEADED SPIDER-MONKEY.

6. NYCTIPITHECUS.



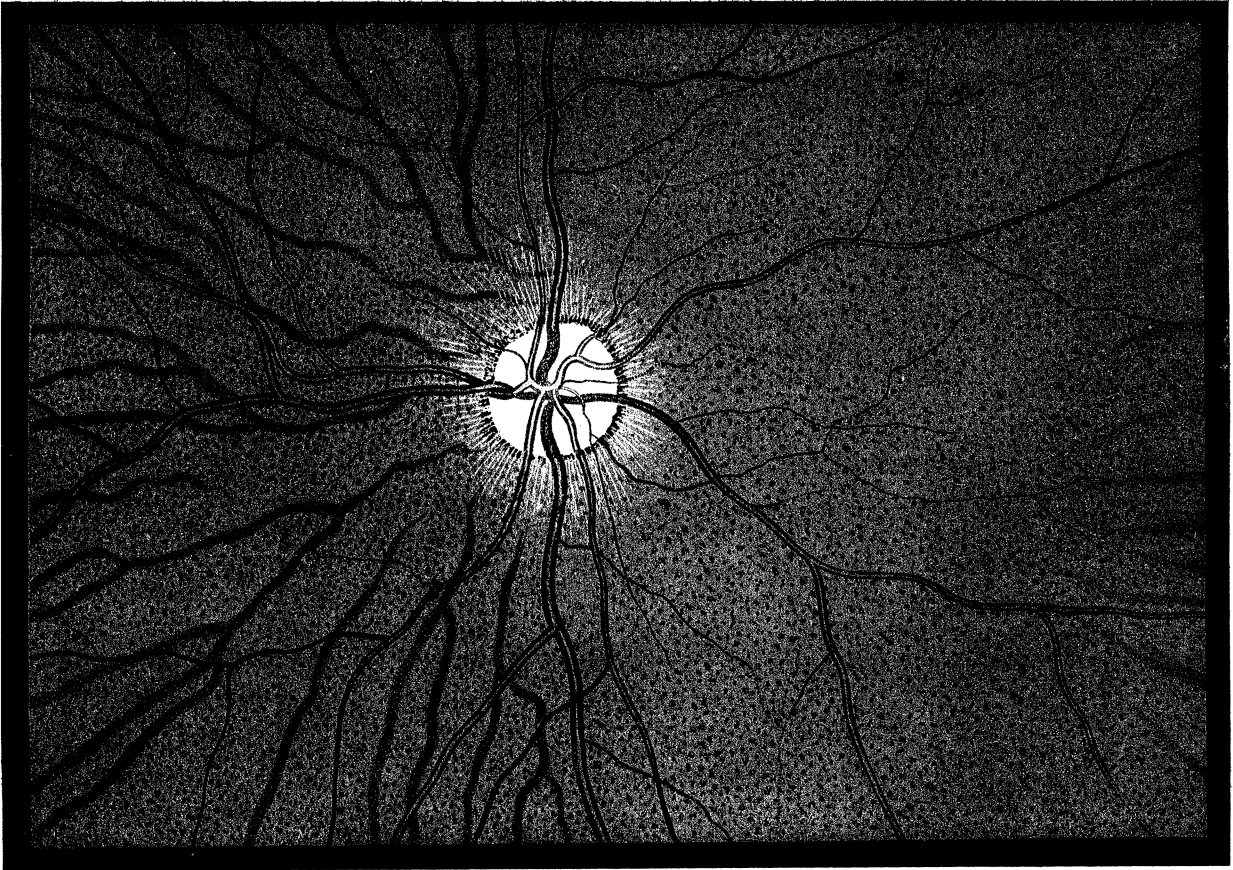
N. LEMURINUS.

LEMURINE DOUROCOULI.

I. PRIMATES.

B. PROSIMIAE.
LEMUR.

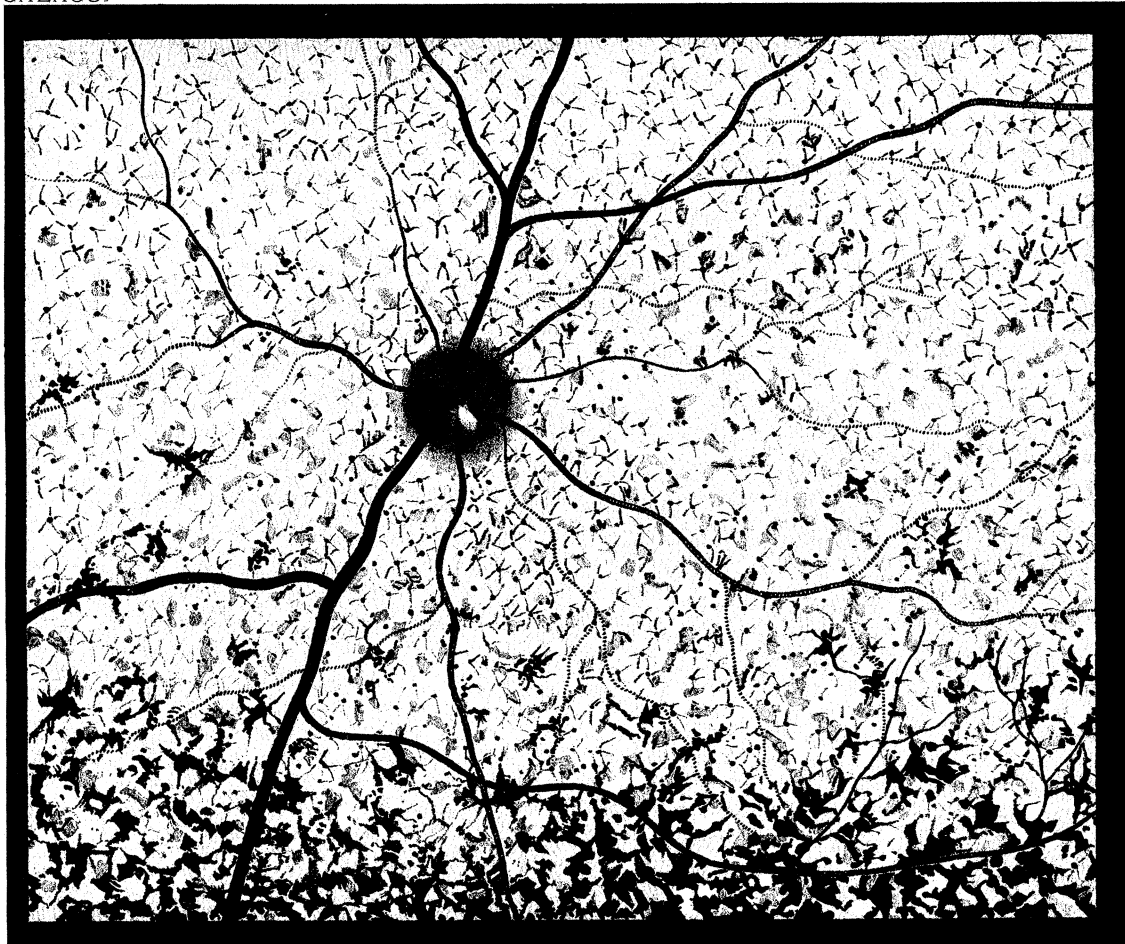
LEMURES.



L. CORONATUS.

CROWN LEMUR.

GALAGO.




G. MONTEIRI.

MONTEIRO'S GALAGO.

II. CHIROPTERA.

PTEROPODIDAE.

PTEROPUS.



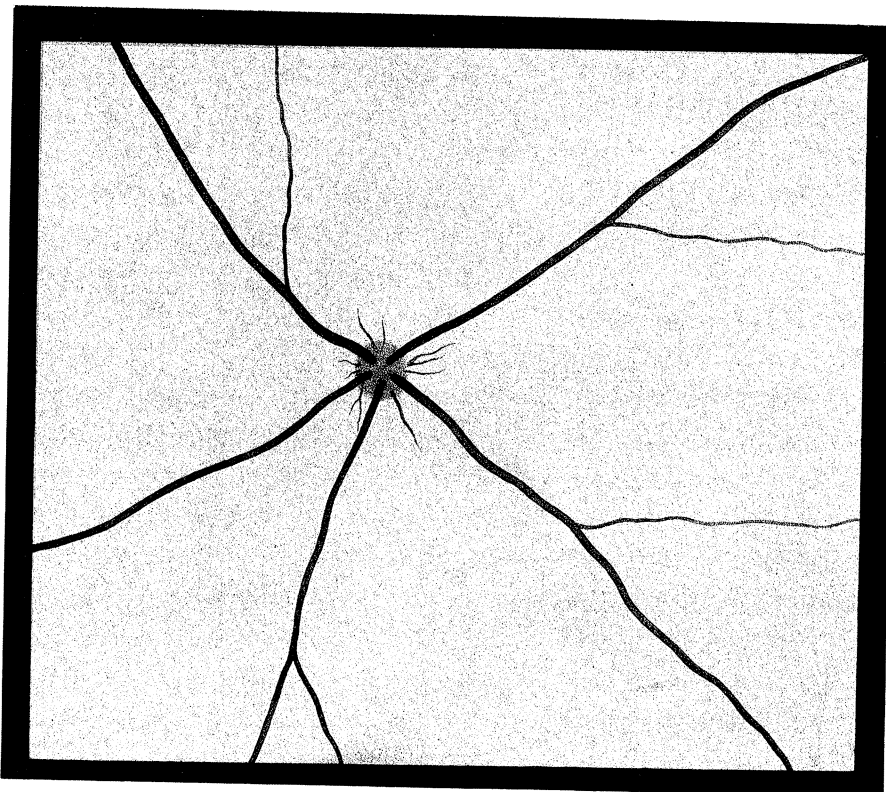
P. POLIOCEPHALUS.

AUSTRALIAN FRUIT-BAT.

III. INSECTIVORA.

SORICIDAE.

ERINACEUS.

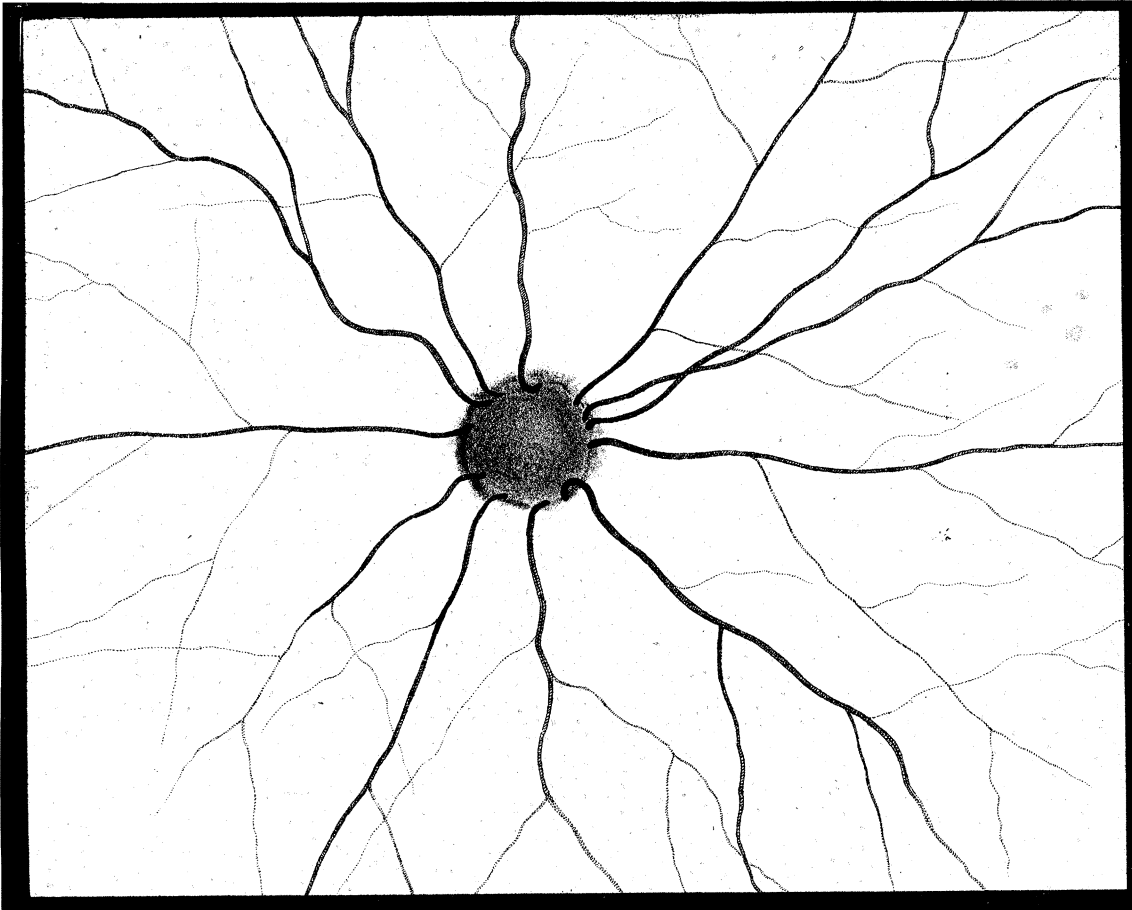


E. EUROPÆUS.

COMMON HEDGEHOG.

A. PINNIPEDIA.
PHOCA.

PHOCIDAE.

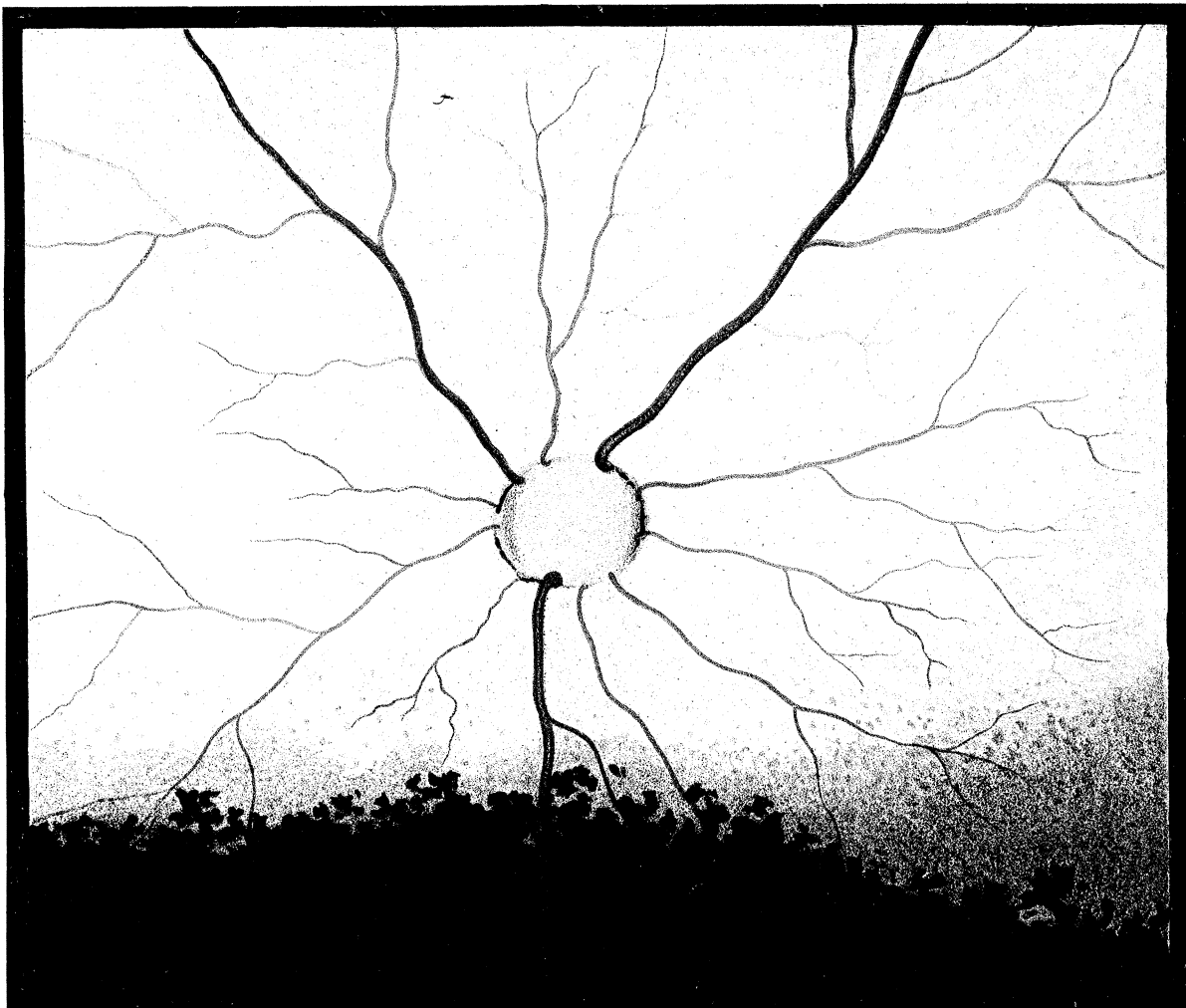

P. VITULINA.

THE COMMON SEAL.

B. FISSIPEDIA.
FELIS.

I. FELIDAE.



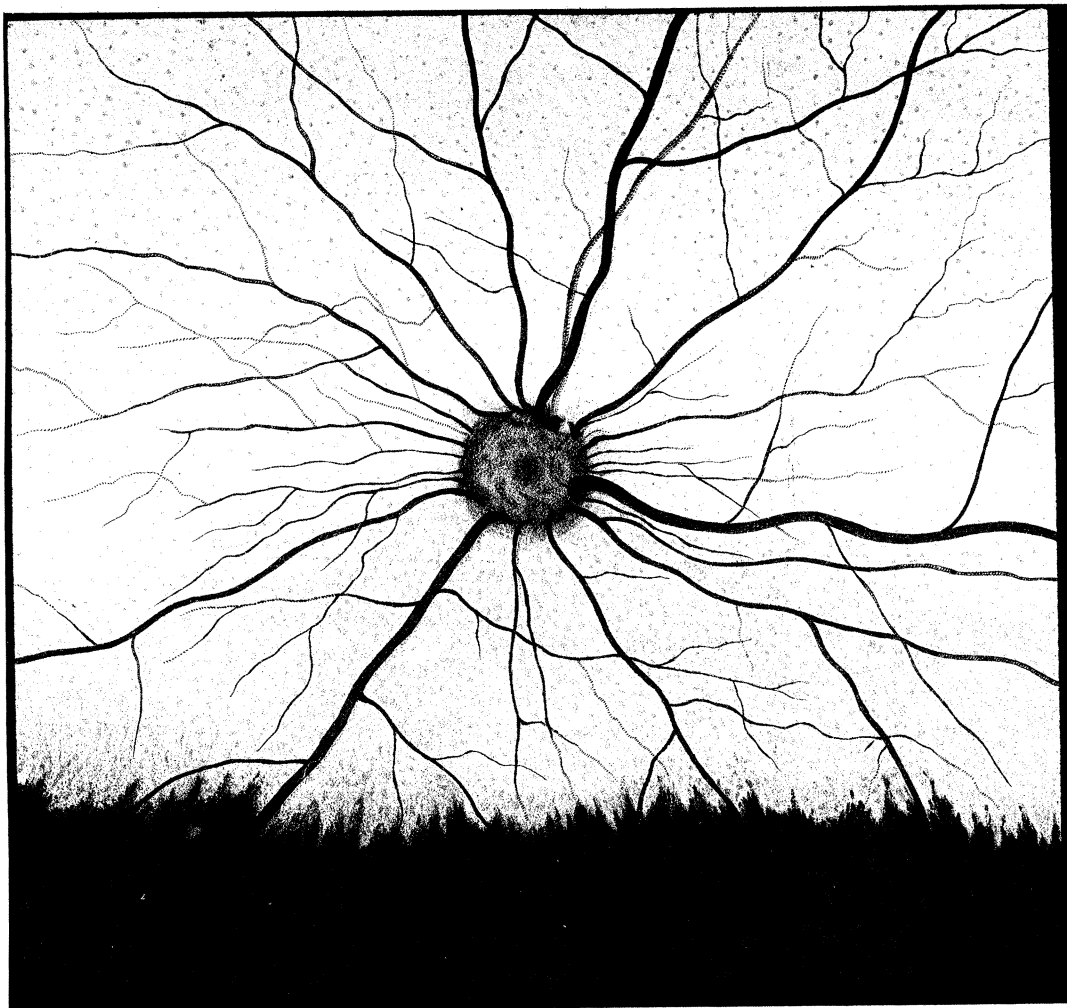
F. SERVAL.

SERVAL.

IV. CARNIVORA.

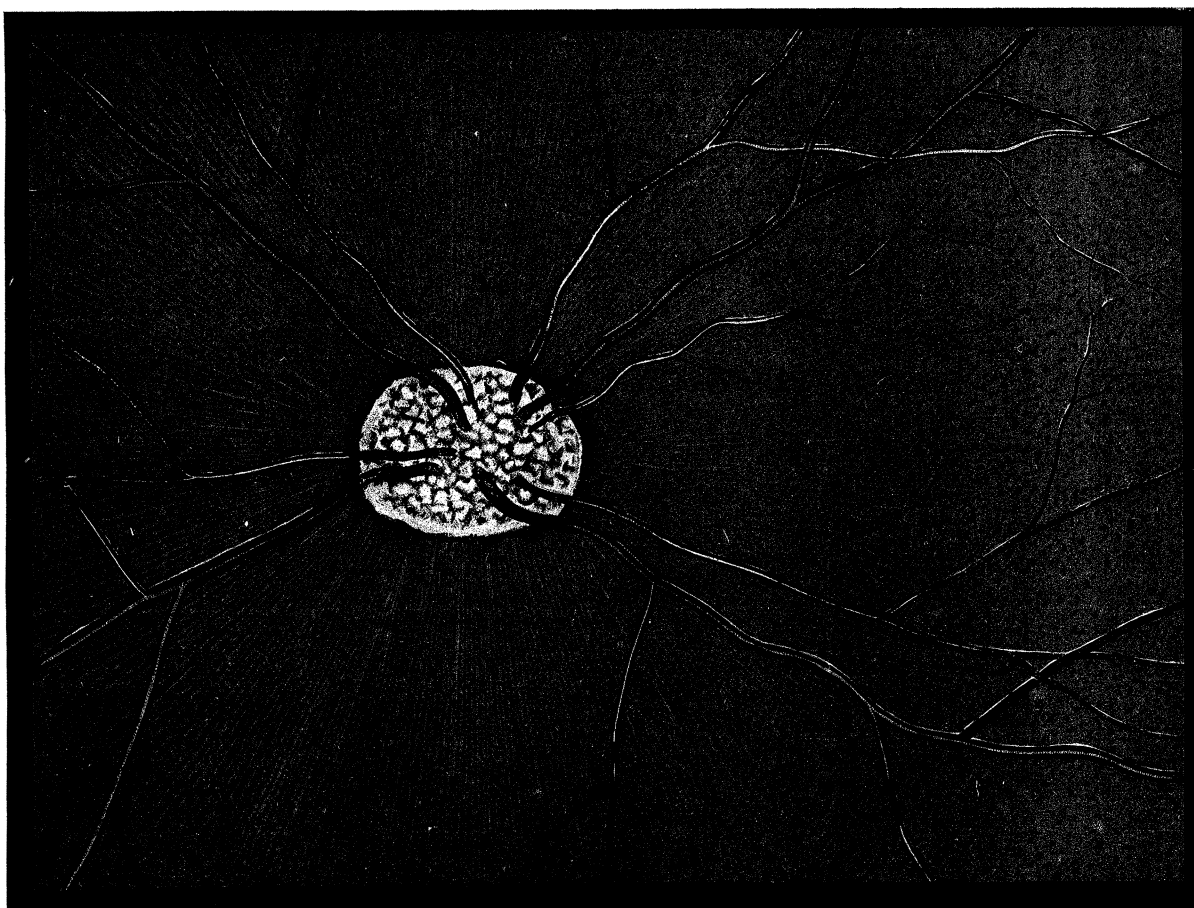
B. FISSIPEDIA.
GENETTA.

2. VIVERRIDAE.



G. VULGARIS.
CYNICTIS.

COMMON GENETTA.



G. PENICILLATA.

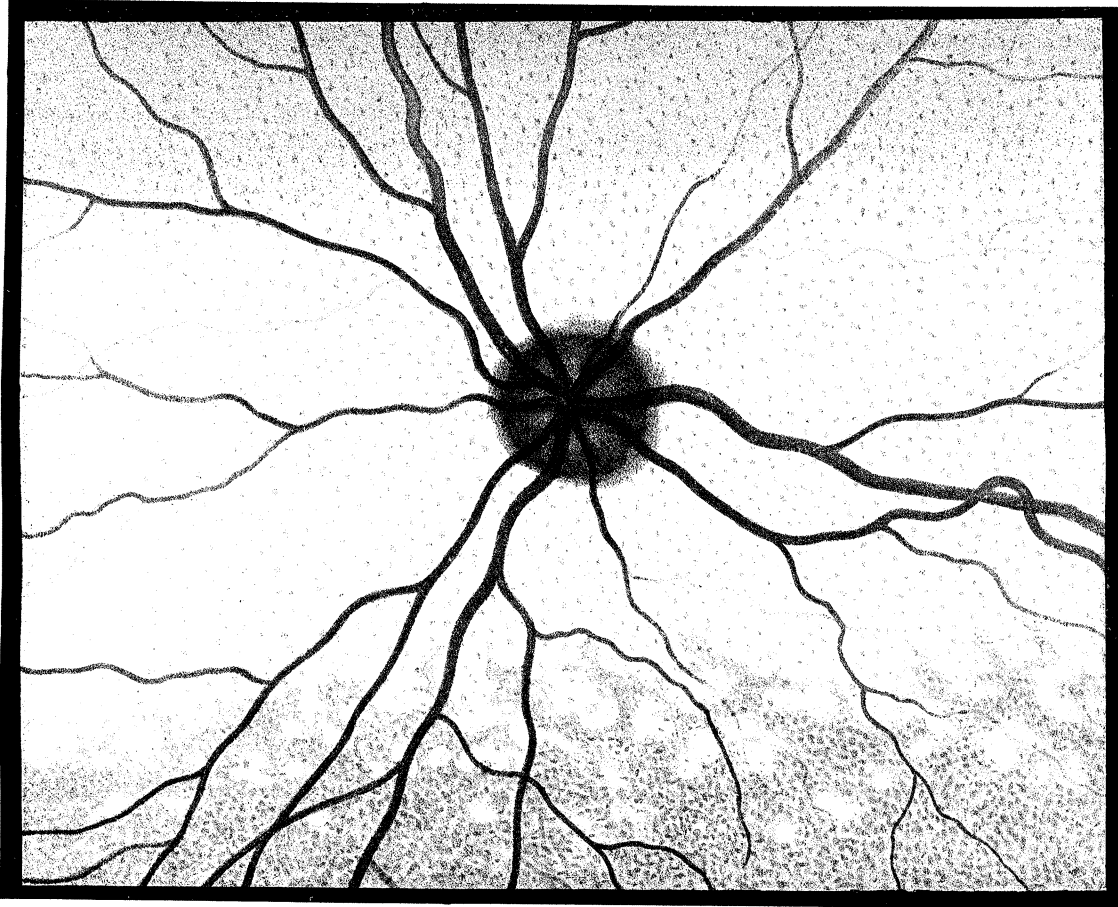
LEVAILLANT'S CYNICTIS.

IV. CARNIVORA.

FISSIPEDIA.

3. HYAENIDÆ.

HYAENA.



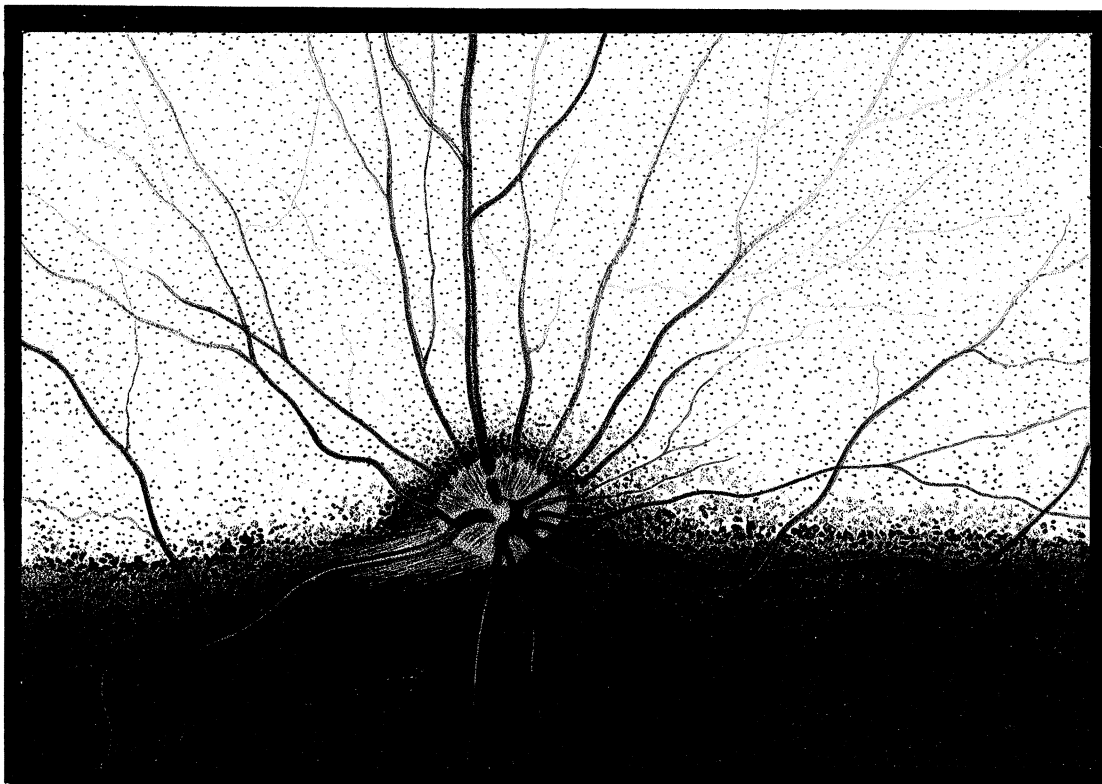HYAENA STRIATA.

STRIPED HYAENA.

B. FISSIPEDIA.

4. CANIDÆ.

CANIS.



C. MESOMELAS.

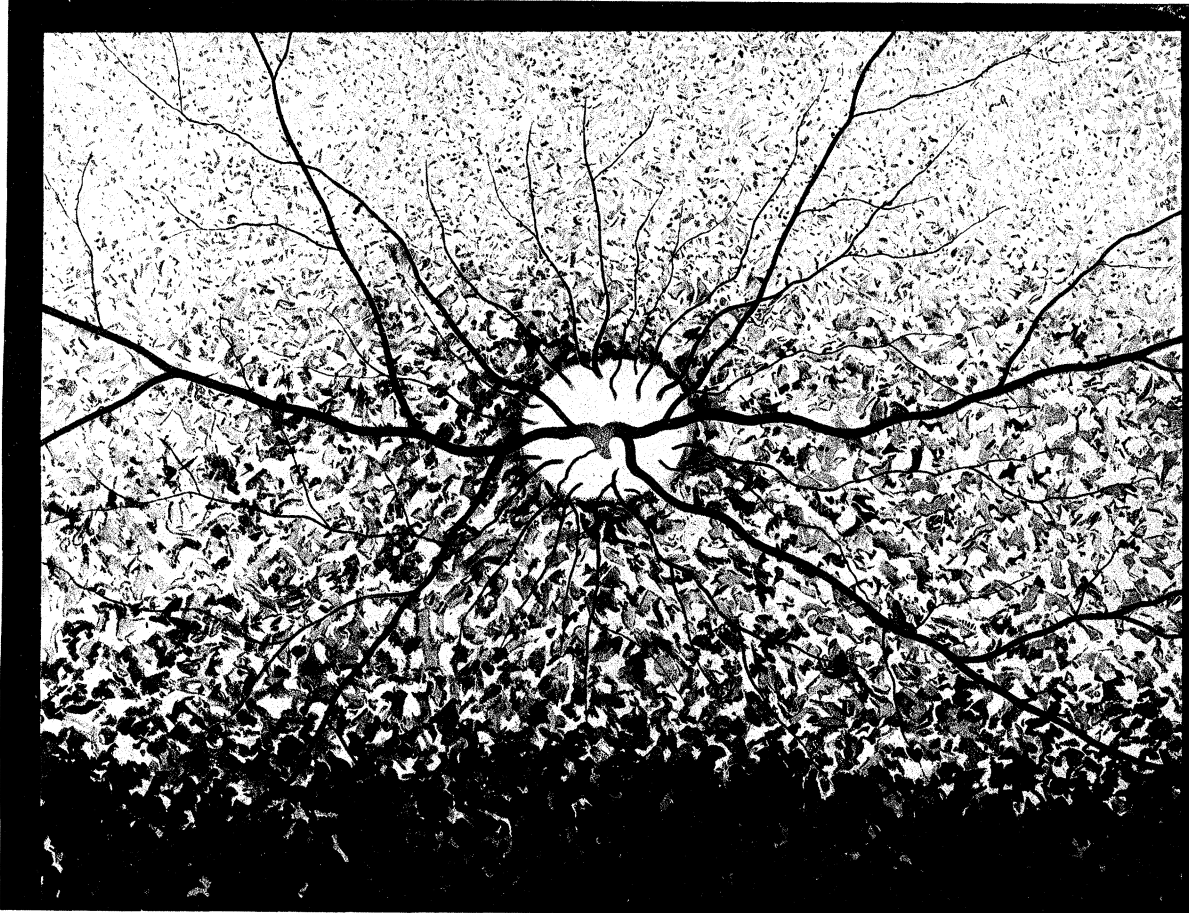
BLACK-BACKED JACKAL.

IV. CARNIVORA.

B. FISSIPEDIA.

5. MUSTELIDAE

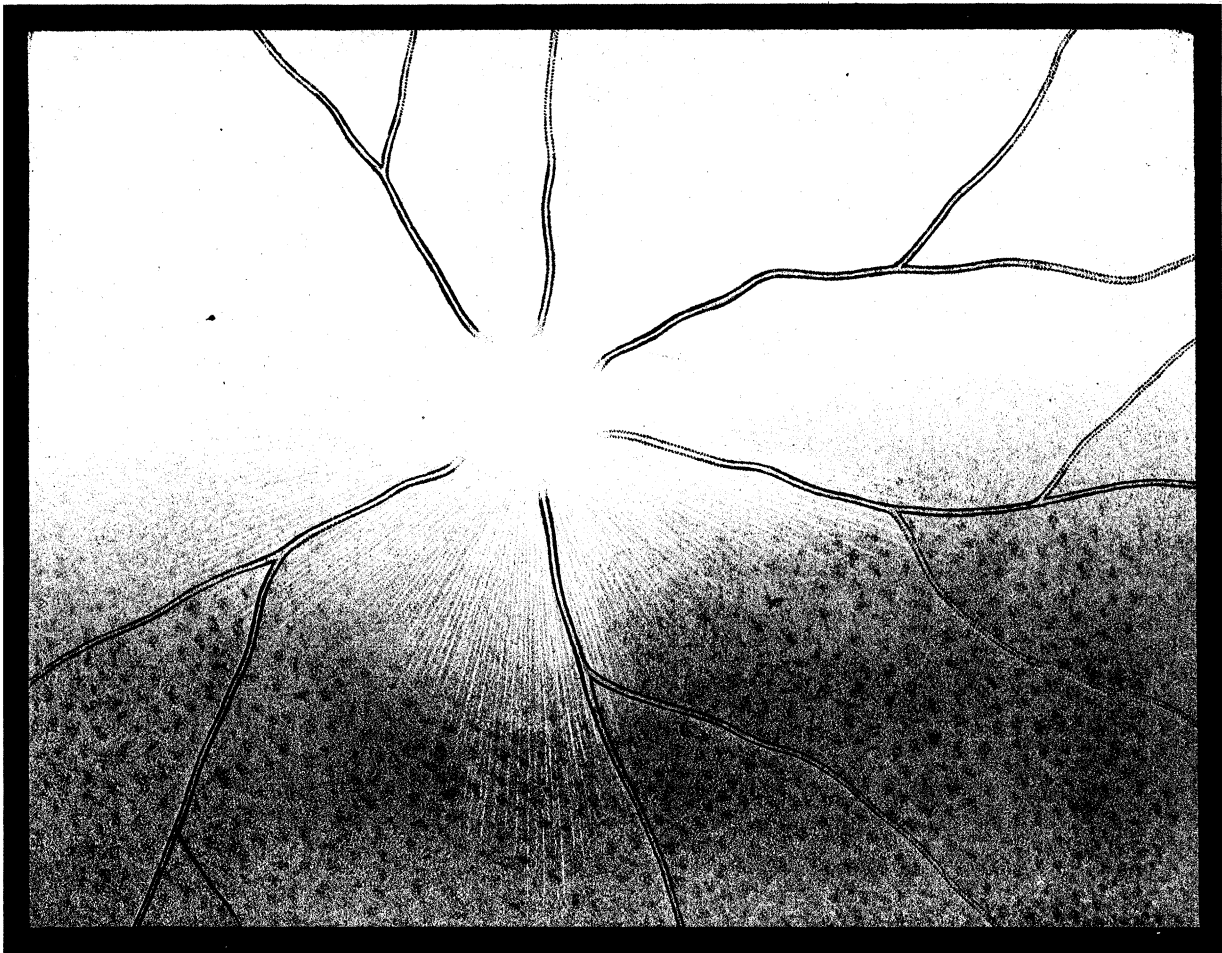
GALICTIS.



G. BARBARA.

TAYRA.

MEPHITIS.



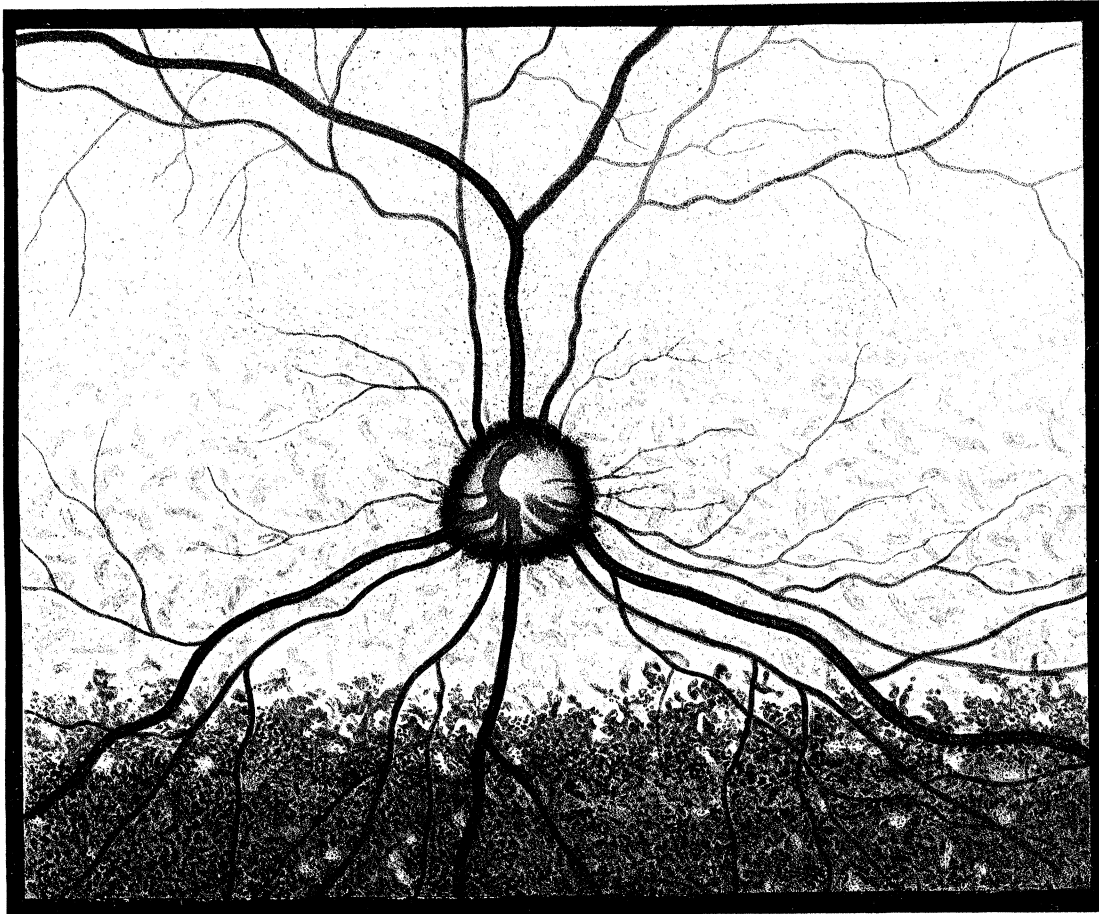
M. MEPHITICA.

CANADIAN SKUNK.

B. FISSIPEDIA.

6. PROCYONIDAE.

PROCYON.

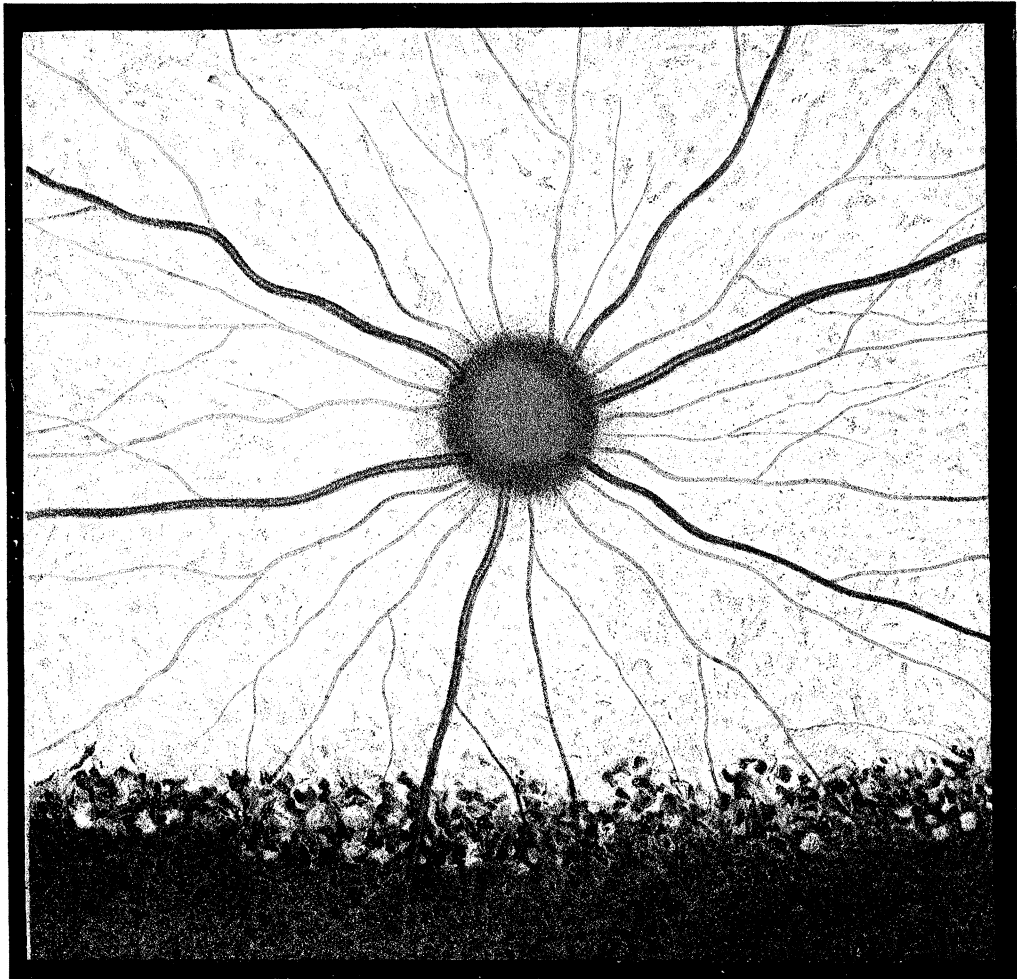


P. LOTOR.

THE RACCOON.

URSUS.

7. URSIDAE.



U. AMERICANUS.

BLACK BEAR.

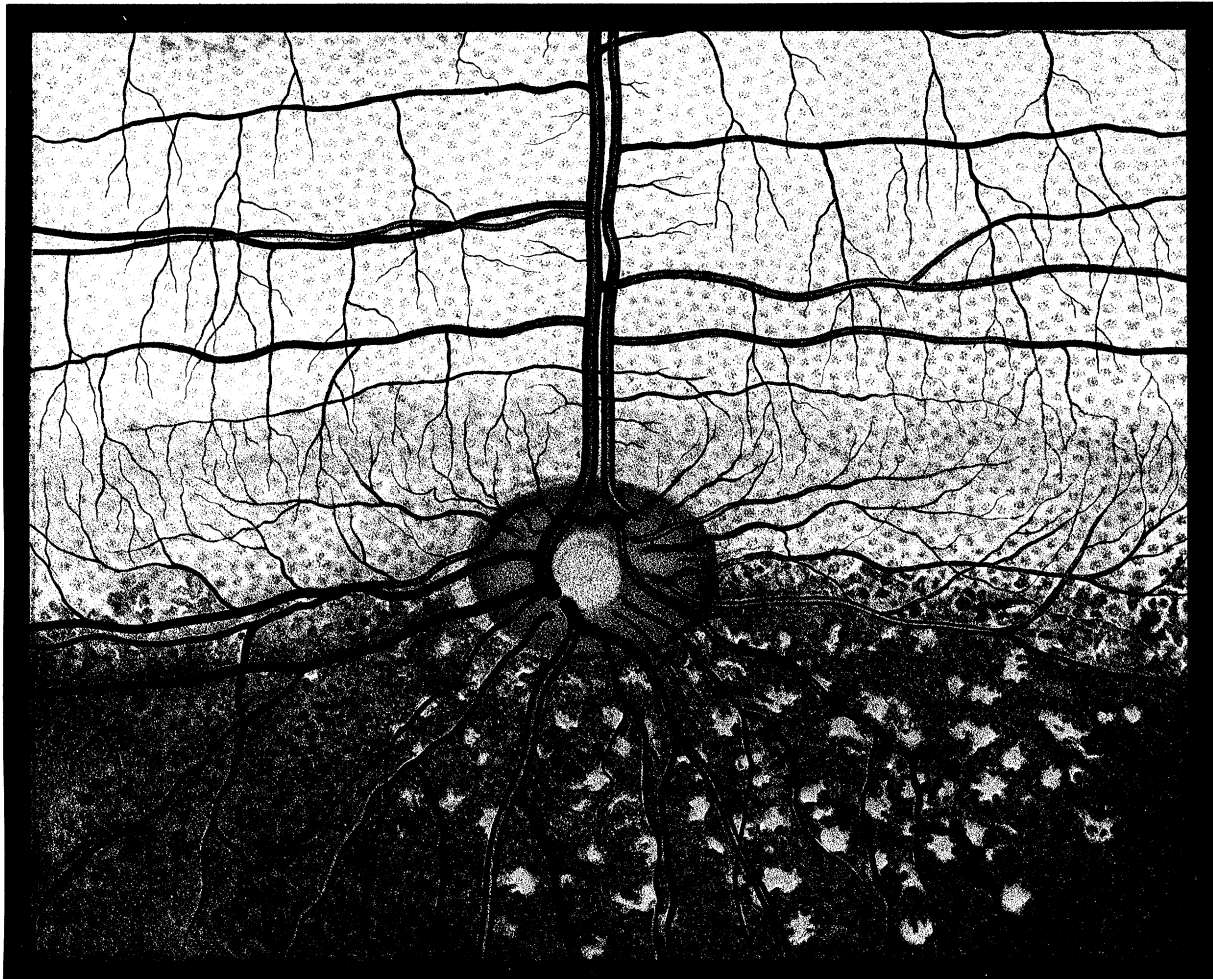
V. UNGULATA.

A. ARTIODACTYLA

a. SELENODONTA.

1. CAVICORNIA.

BOS.




BOS. INDICUS.

INDIAN OX.

CERVUS.

2. CERVICORNIA.



CERVUS PORCINUS.

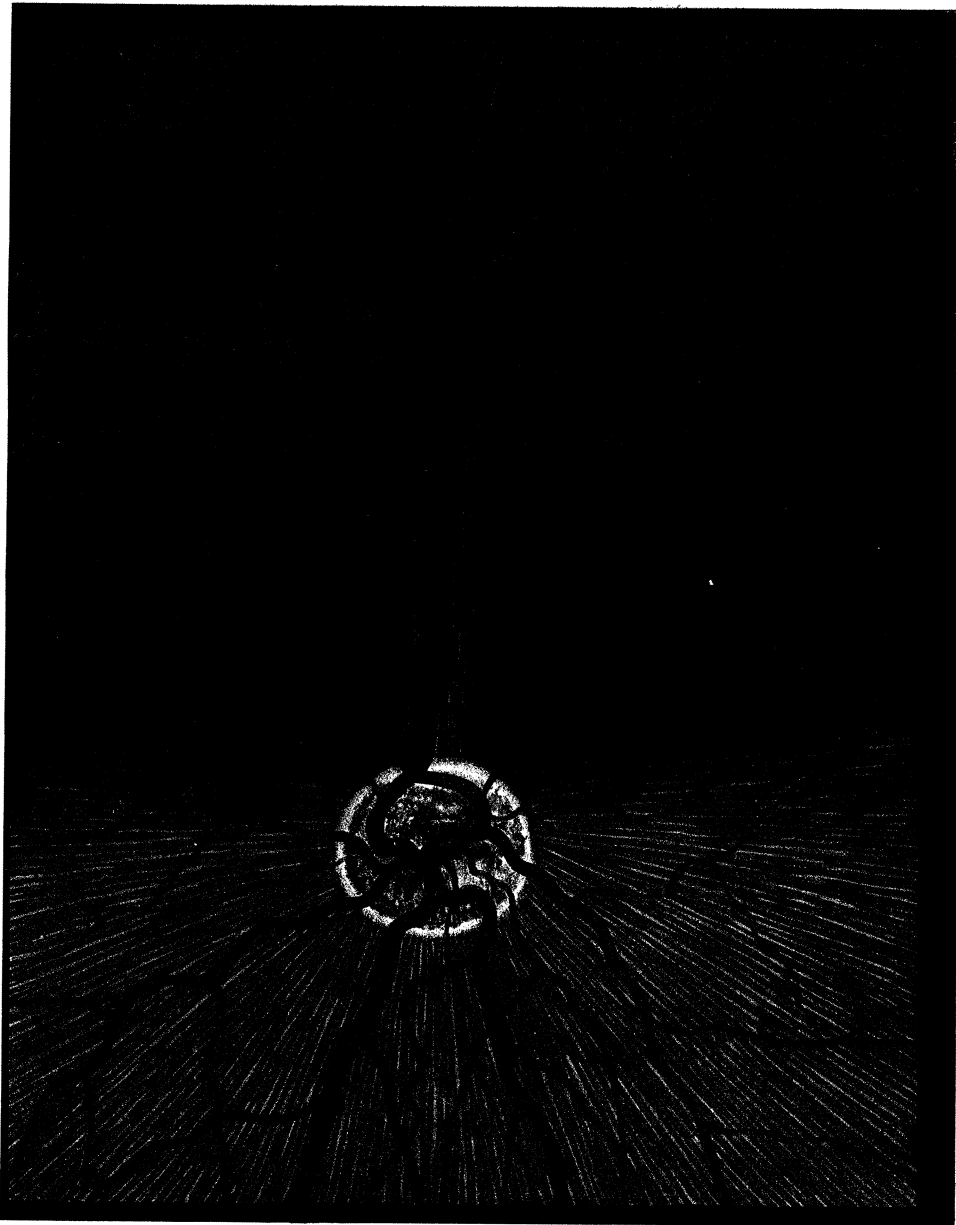
HOG-DEER.

V. UNGULATA.
a. SELENODONTA

A. ARTIODACTYLA.

3. CAMELIDAE.

CAMELUS.



C. BACTRIANUS.

BACTRIAN CAMEL.

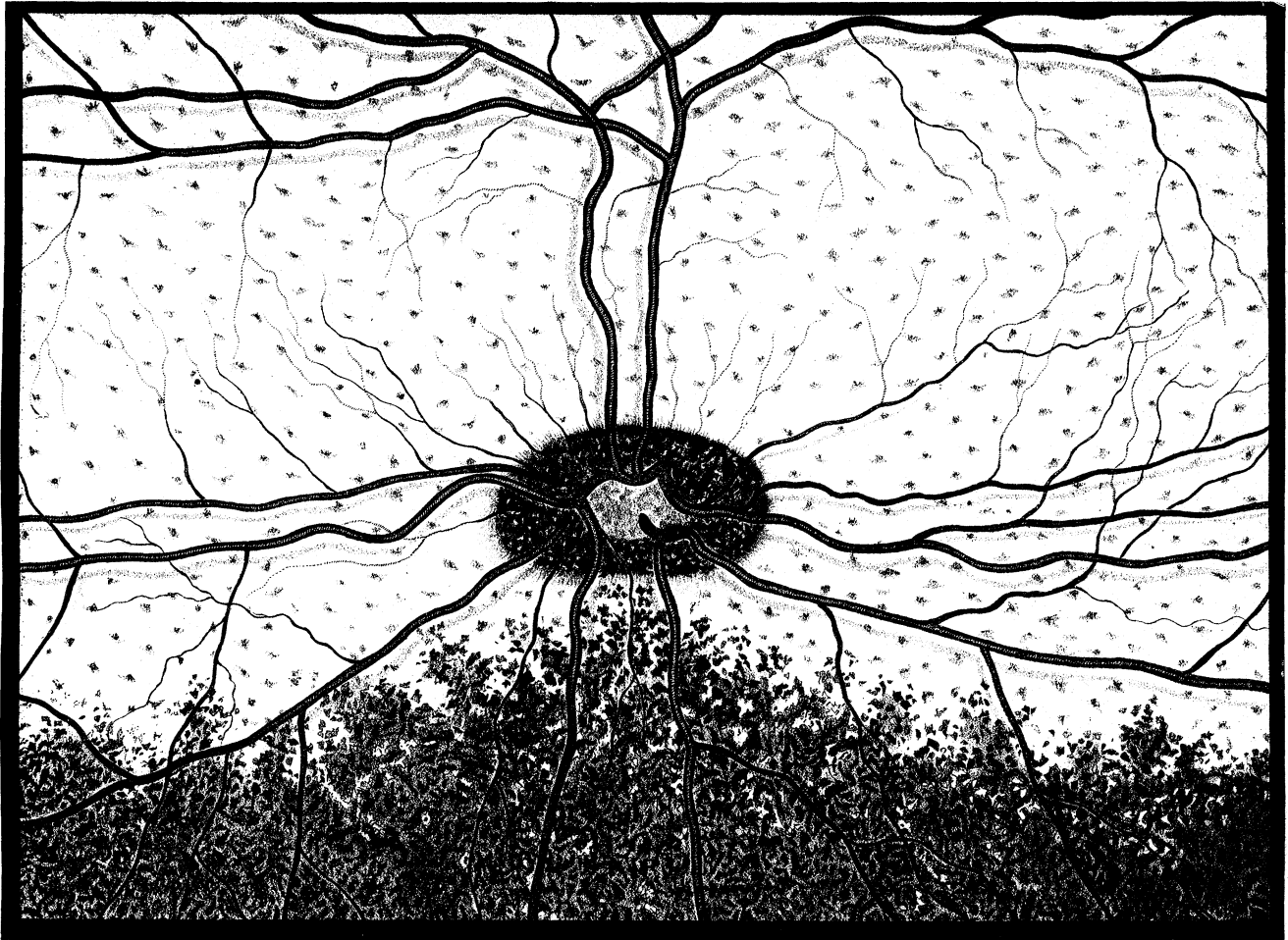
V. UNGULATA.

A. ARTIODACTYLA.

a. SELENODONTA.

4. TRAGULIDAE.

TRAGULUS.



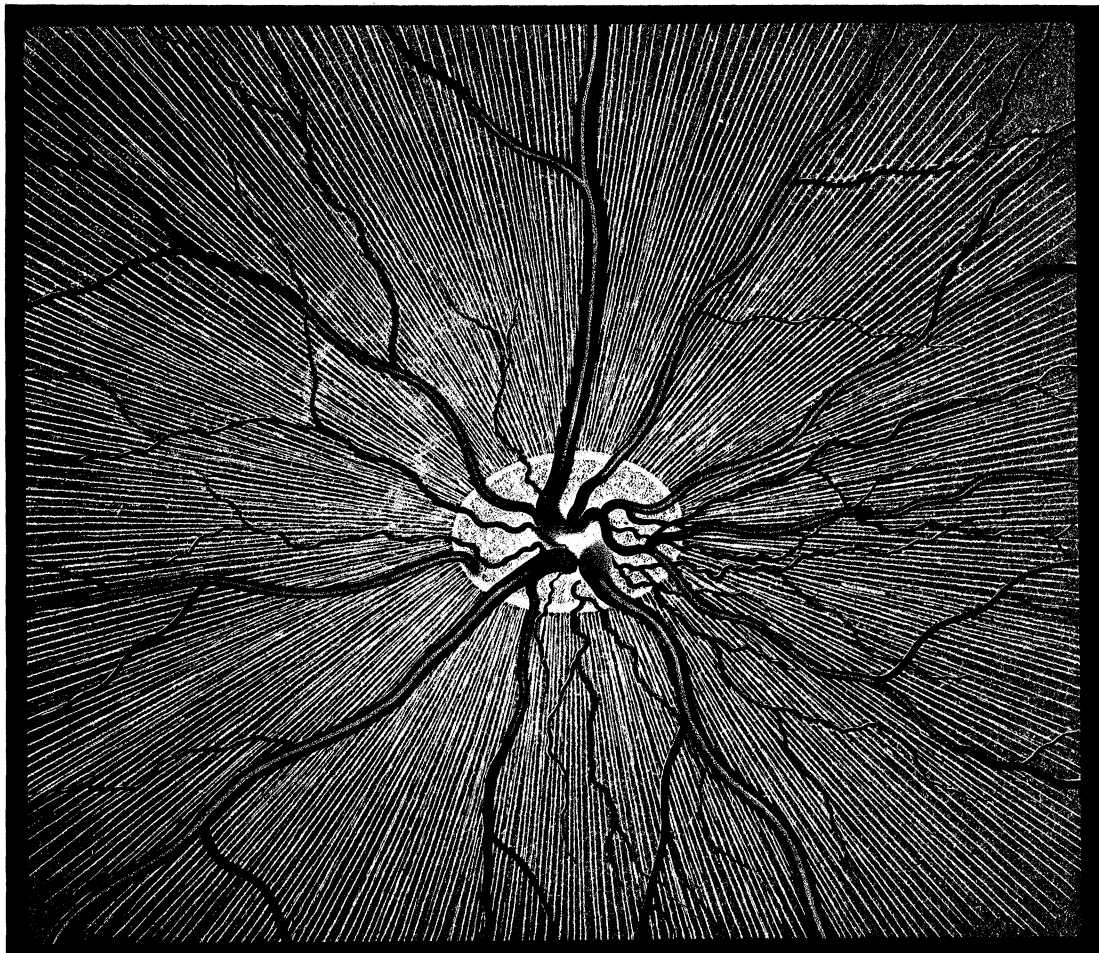
T. JAVANICUS.

CHEVROTAIN.

SUS.

b. BUNODONTA.

SUIDAE.




S. SCROFA.

WILD BOAR.

B. PERISSODACTYLA.
RHINOCEROS.

V. UNGULATA.

RHINOCEROTIDAE.

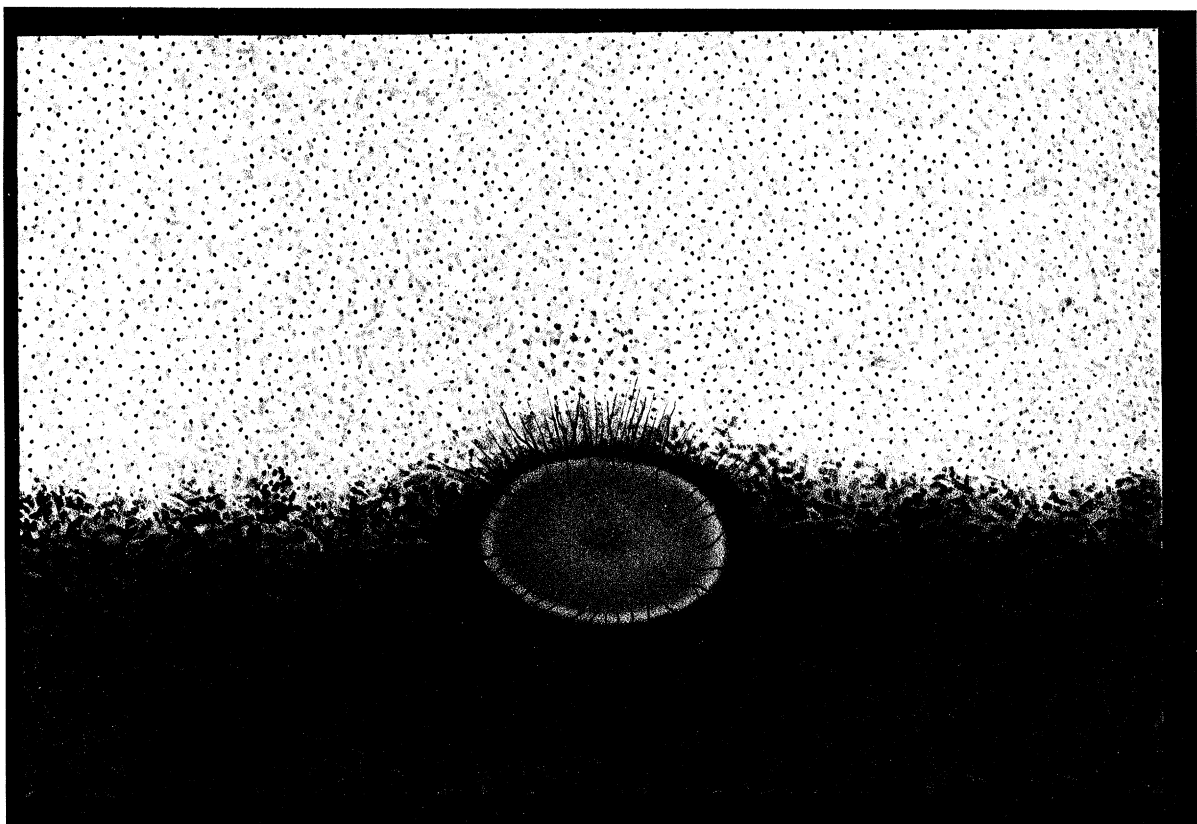


R. UNICORNIS.

INDIAN RHINOCEROS.

B. PERISSODACTYLA.
ZEBRA.

2. EQUIDAE.




Z. BURCHELLI.

BURCHELL'S ZEBRA.

TAPIRUS.

3. TAPIRIDAE.




T. AMERICANUS.

AMERICAN TAPIR.

C. PROBOSCIDEA.
ELEPHAS.

ELEPHANTIDAE.



E. AFRICANUS.

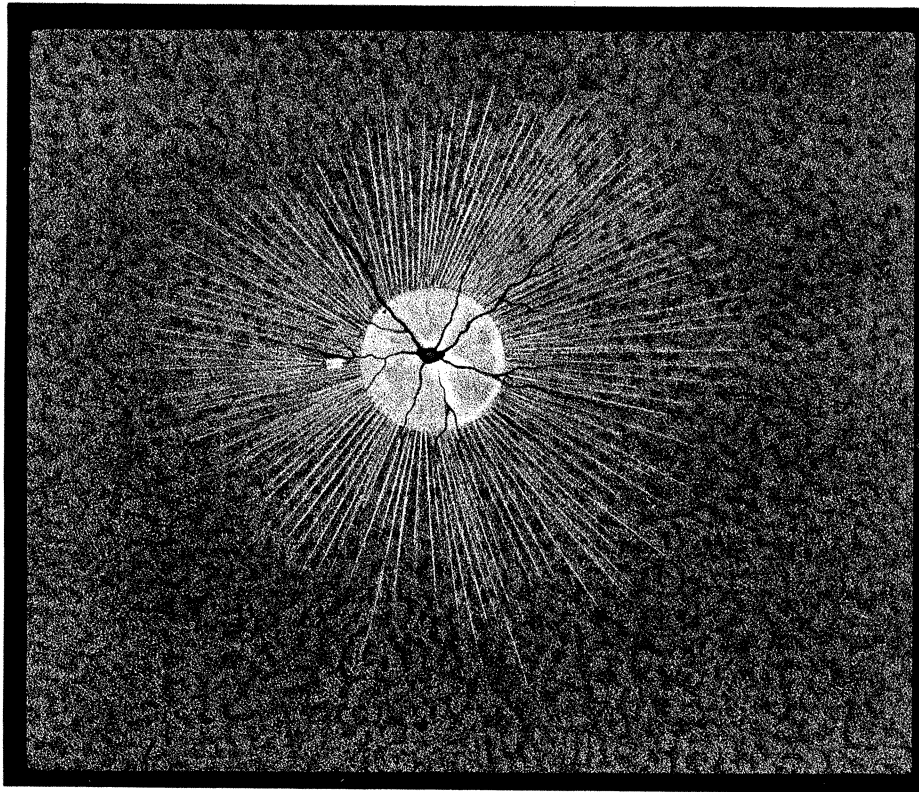
AFRICAN ELEPHANT.

V. UNGULATA.

D. HYRACOIDAE.

HYRACIDAE.

HYRAX.



H. DORSALIS.

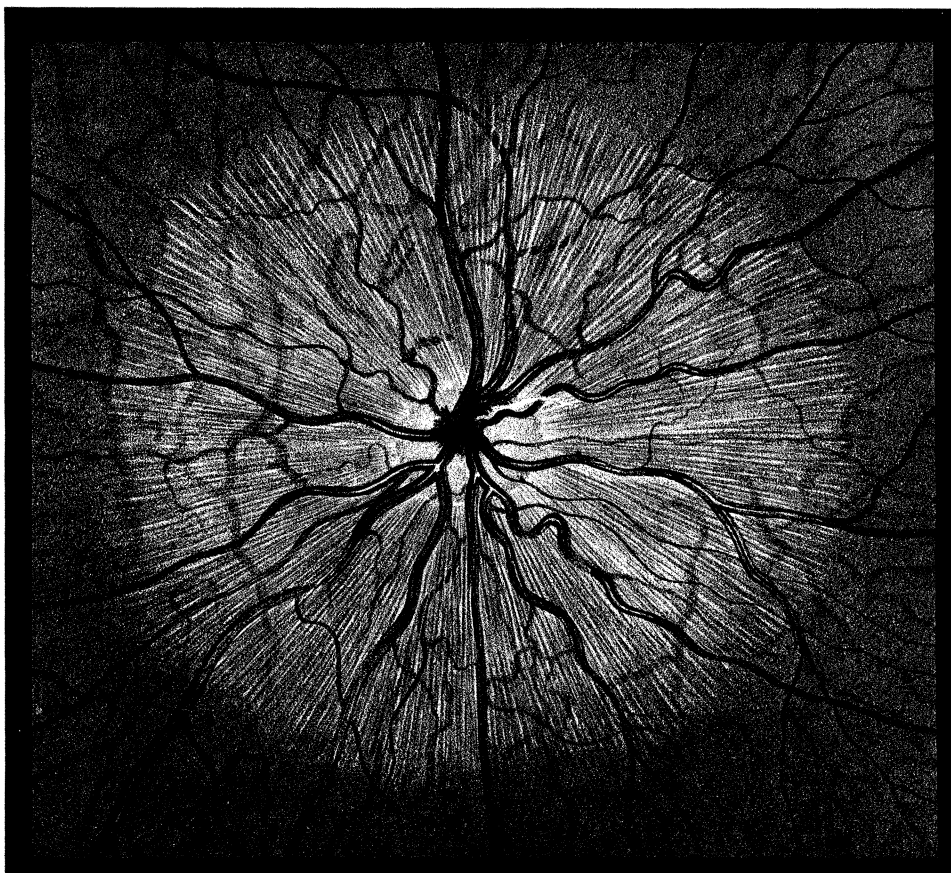
DORSAL HYRAX.

VIII. RODENTIA.

A. MYOMORPHA.

i. DIPODIDAE.

ALACTAYA.



A. INDICA.

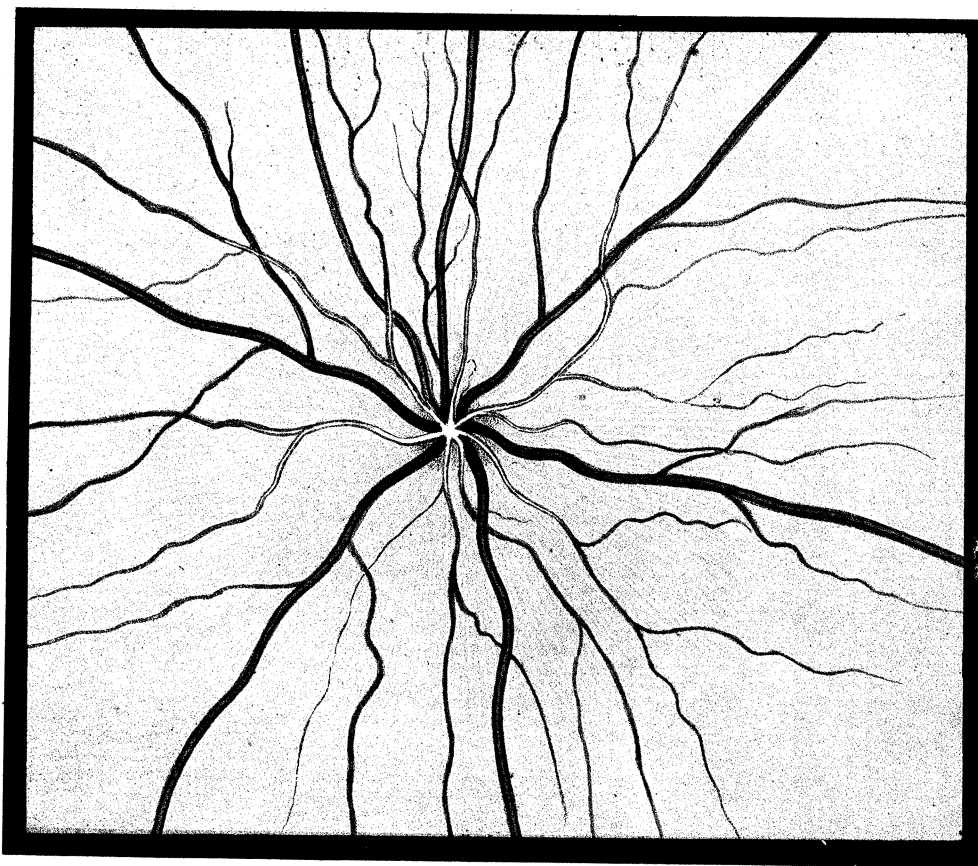
INDIAN ALACTAYA.

VIII. RODENTIA.

A. MYOMORPHA.

2. MURIDAE.

MUS.




M. RATTUS.

BRITISH BLACK RAT.

B. SCIUROMORPHA.

SCIURIDAE.

SCIURUS.



S. VULGARIS.

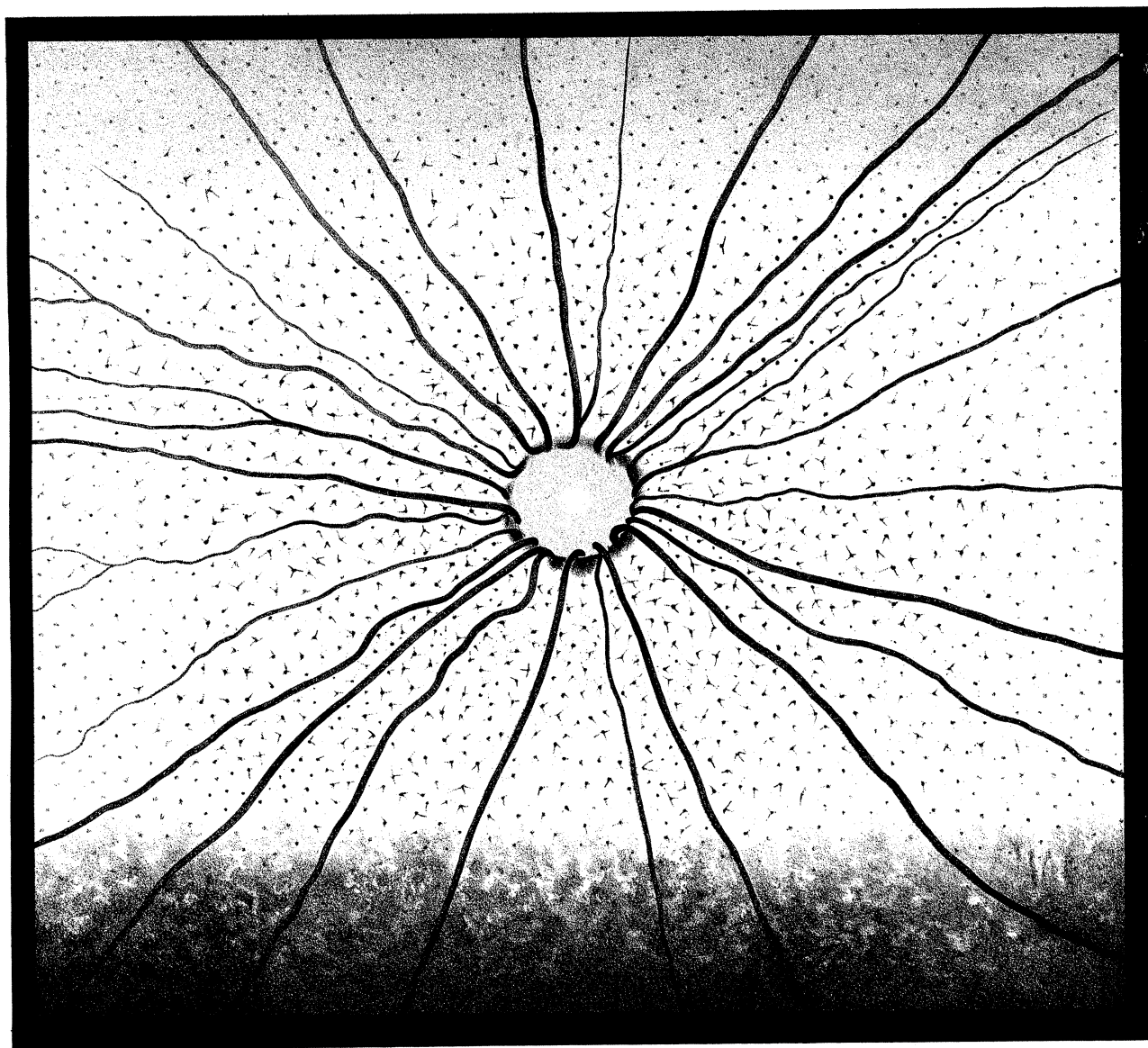
COMMON SQUIRREL

VIII. RODENTIA.

B. SCIUROMORPHA.

SCIURIDAE

PTEROMYS.

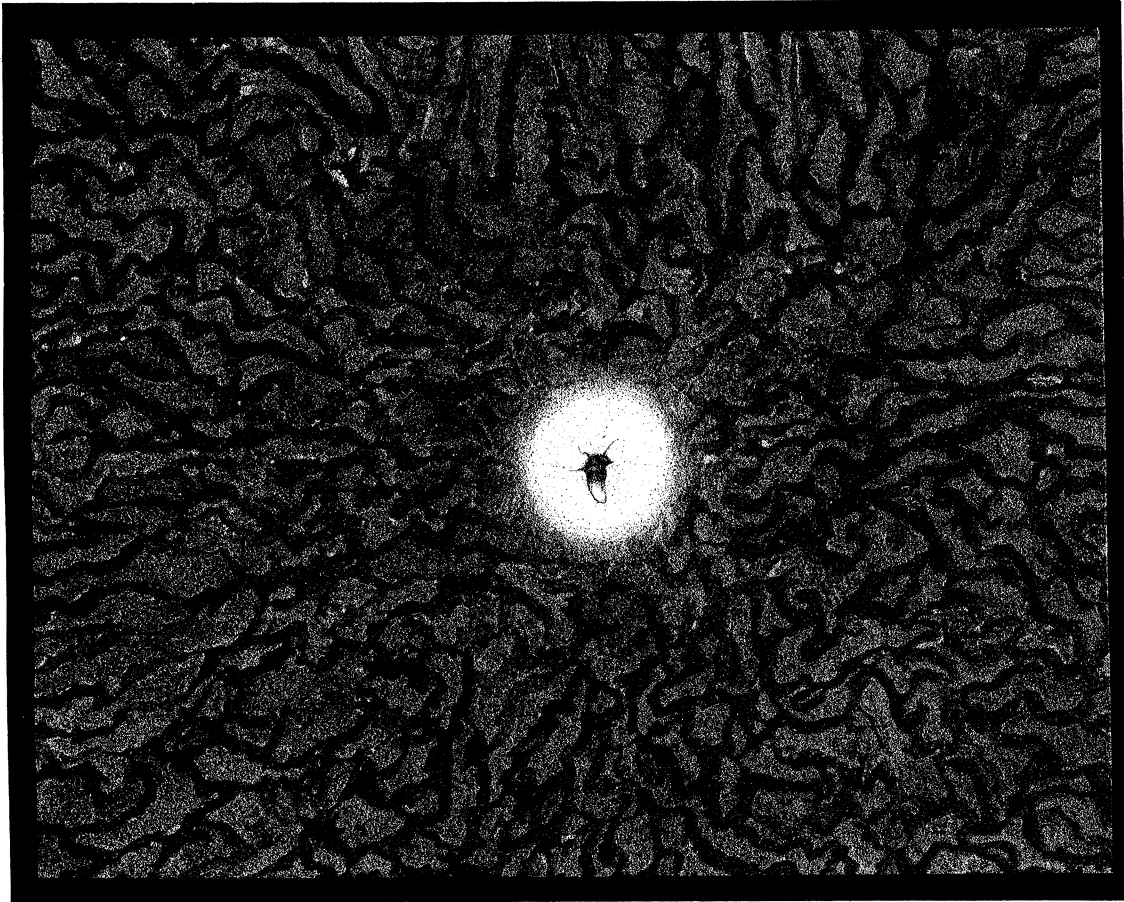


P. ALBORUFUS.

RED & WHITE FLYING SQUIRREL.

B. SCIUROMORPHA.
CASTOR.

CASTORIDAE.




C. CANADENSIS.

CANADIAN BEAVER.

C. HYSTRICOMORPHA.
CHINCHILLA.

1. CHINCHILLIDAE.



C. LANIGERA.

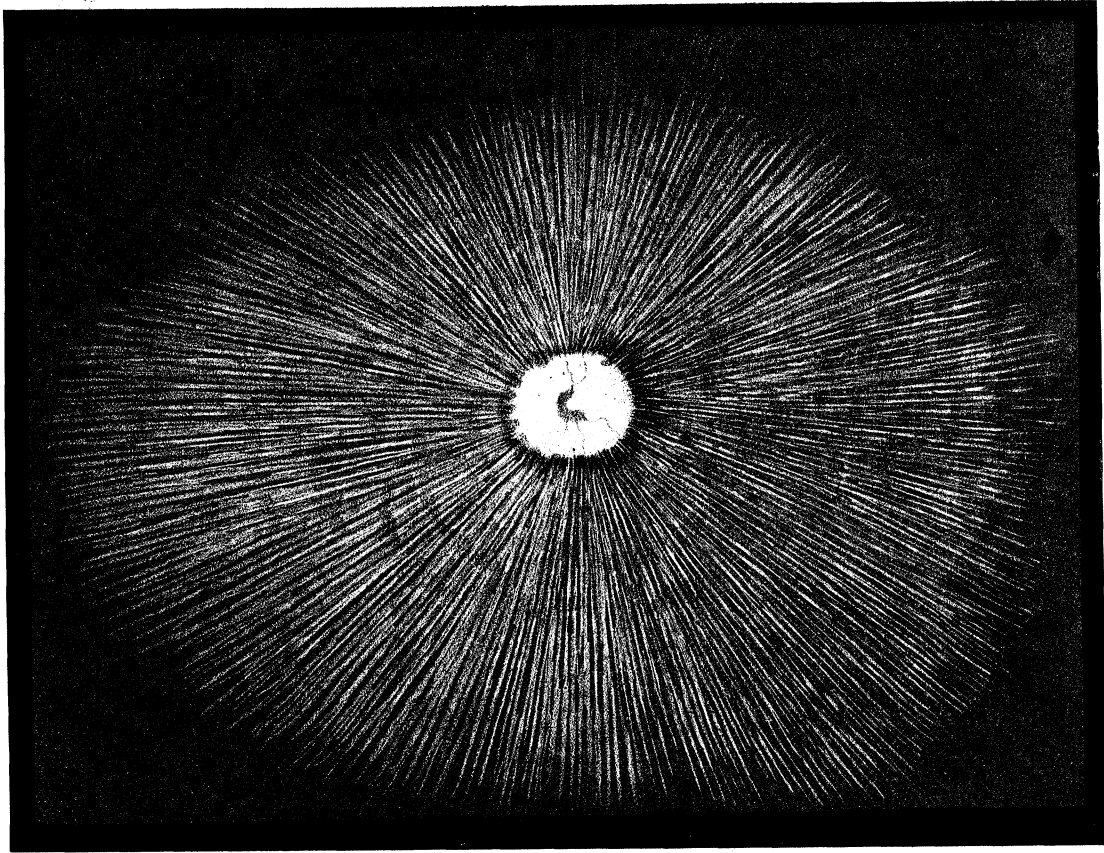
CHINCHILLA.

VIII. RODENTIA.

C. HYSTRICOMORPHA.

2. CAVIIDAE.

CAVIA.




C. PORCINUS.

COMMON GUINEA PIG.

DASYPROCTA.

4. DASYPROCTIDAE.



D. ISTHMICA

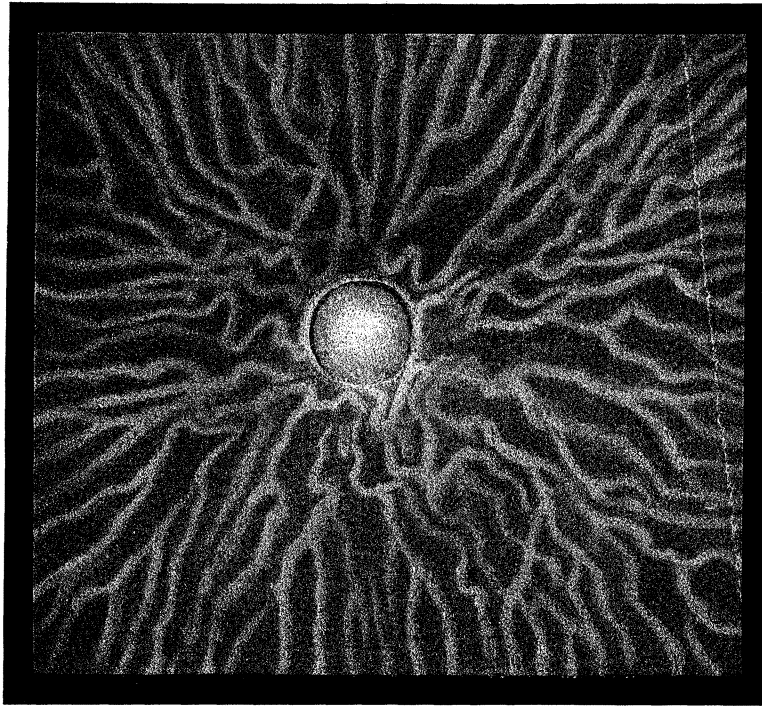
CENTRAL AMERICAN AGOUTI.

VIII. RODENTIA.

C. HYSTRICOMORPHA.

5. HYSTRICIDAE.

SPHINGURUS.



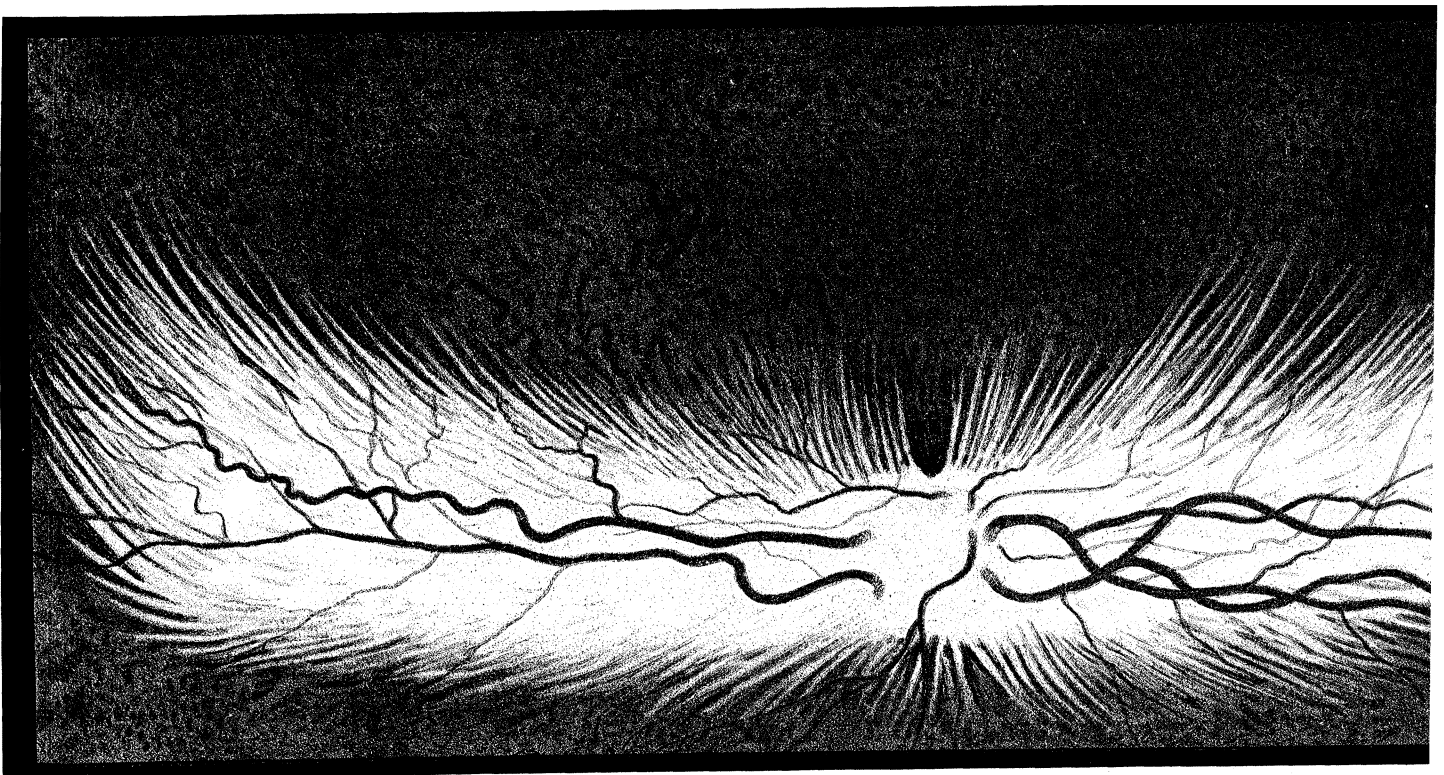
S. PREHENSILIS.

BRAZILIAN PORCUPINE.

D. LAGOMORPHA.

LEPORIDAE.

LEPUS.



L. CUNICULUS.


COMMON RABBIT.

IX. EDENTATA.

XENARTHRA.

DASYPODIDAE.

DASYPUS.



D. VILLOSUS.


HAIRY ARMADILLO.

X. MARSUPIALIA.

A. DIPROTODONTIA.

1. PHASCOLOMYIDAE.

PHASCOLOMYS.

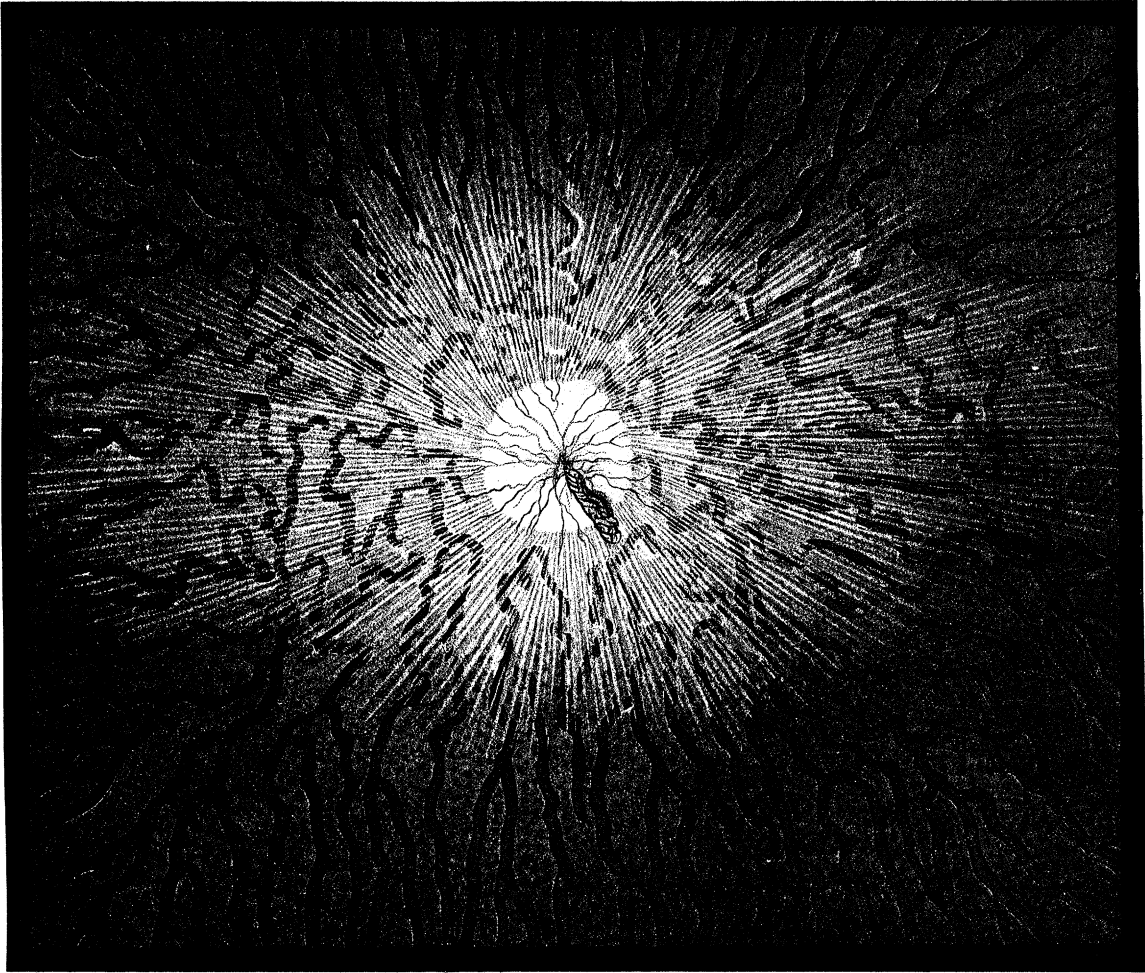


P. WOMBAT.

WOMBAT.

A. DIPROTODONTIA.
HYPSPRYMNUS.

2. MACROPODIDAE.

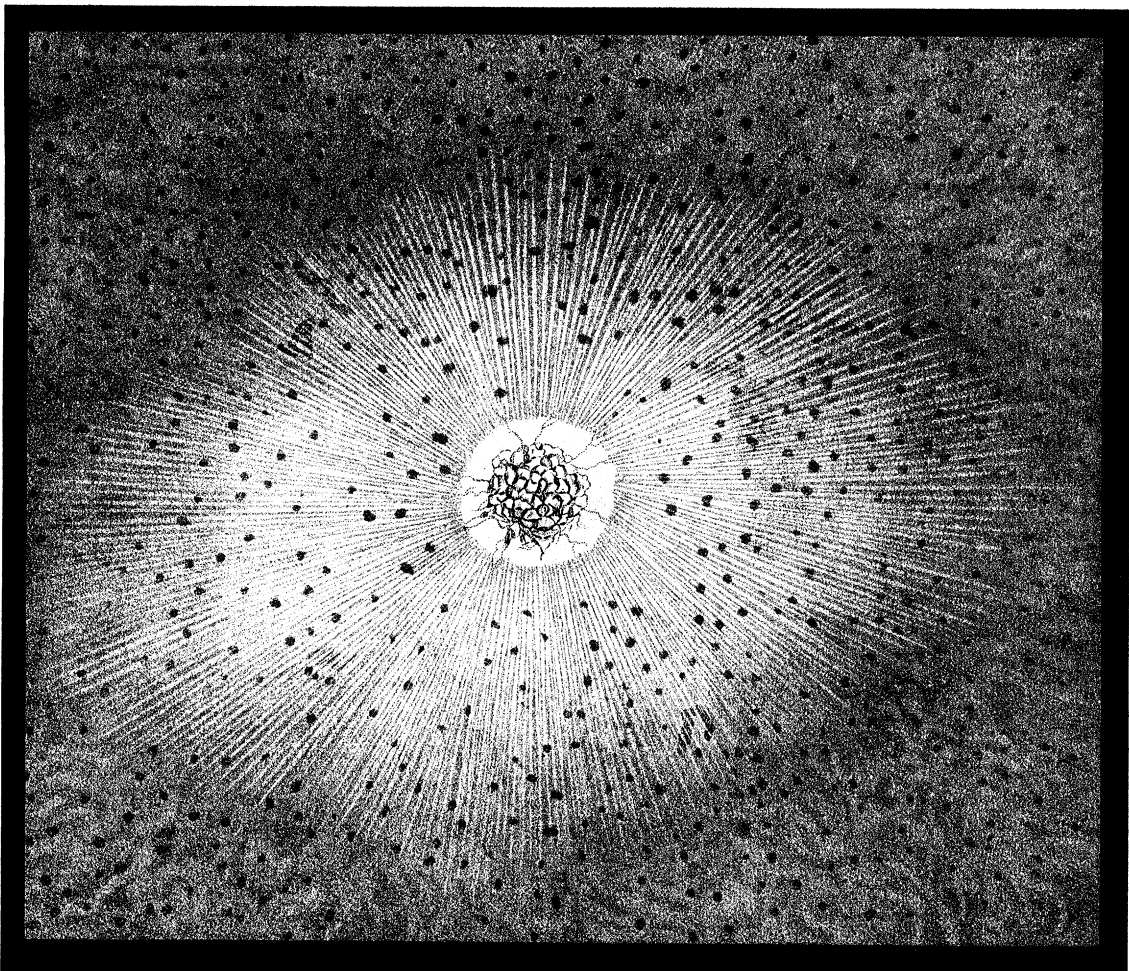


H. RUFESCENS.

RUFOUS RAT KANGAROO.

BELIDEUS.

3. PHALANGISTIDAE



B. SCIURUS.

SQUIRREL-LIKE PHALANGER.

X. MARSUPIALIA.

B. POLYPROTODONTIA.
DIDELPHYS.

1. DIDELPHYIDAE.

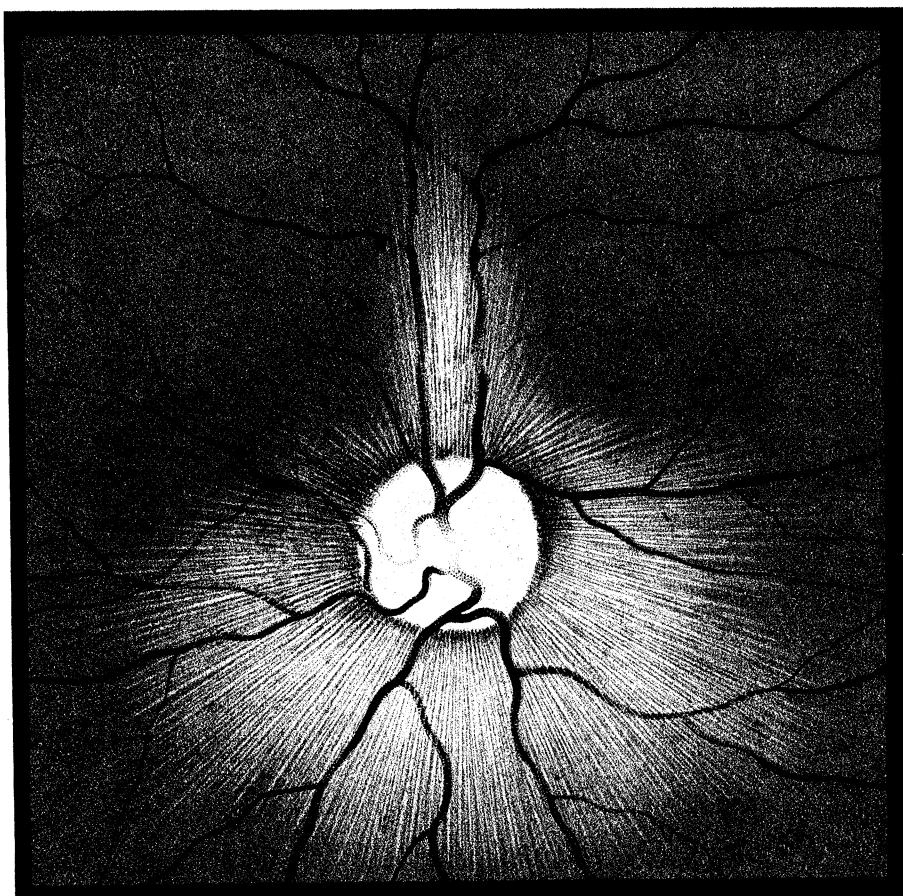


D. VIRGINIANA.

VIRGINIAN OPOSSUM.

DASYURUS.

2. DASYURIDAE.



D. URSINUS.


TASMANIAN DEVIL.

X. MARSUPIALIA.

B. POLYPROTODONTIA.

3. PERAMELIDAE.


PERAMELES.



P. LAGOTIS.

RABBIT-EARED PERAMELES.

XI. MONOTREMATA.



ECHIDNA.

Various Types of the obliterated Hyaloid Artery in Man.

Fig. 1.

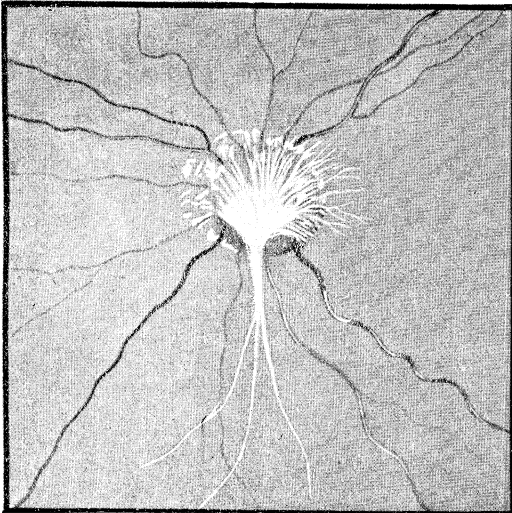


Fig. 2.

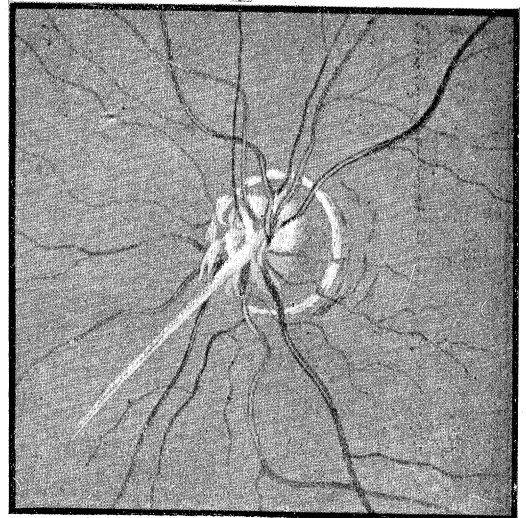


Fig. 3.

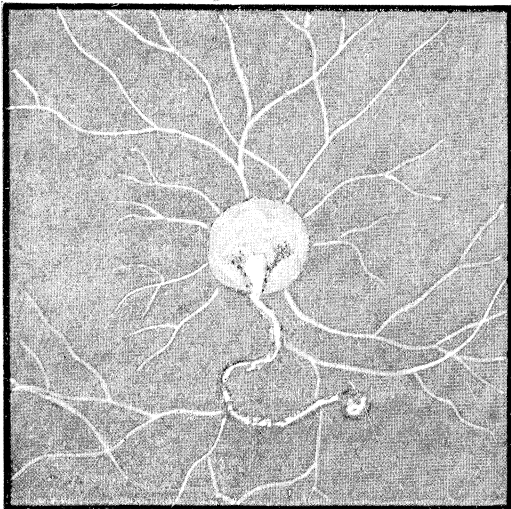
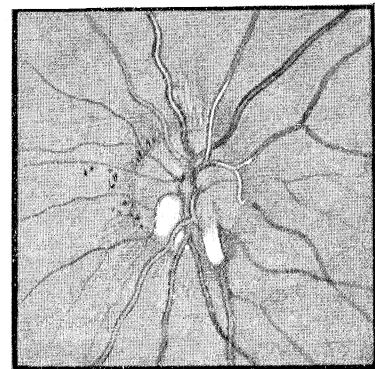
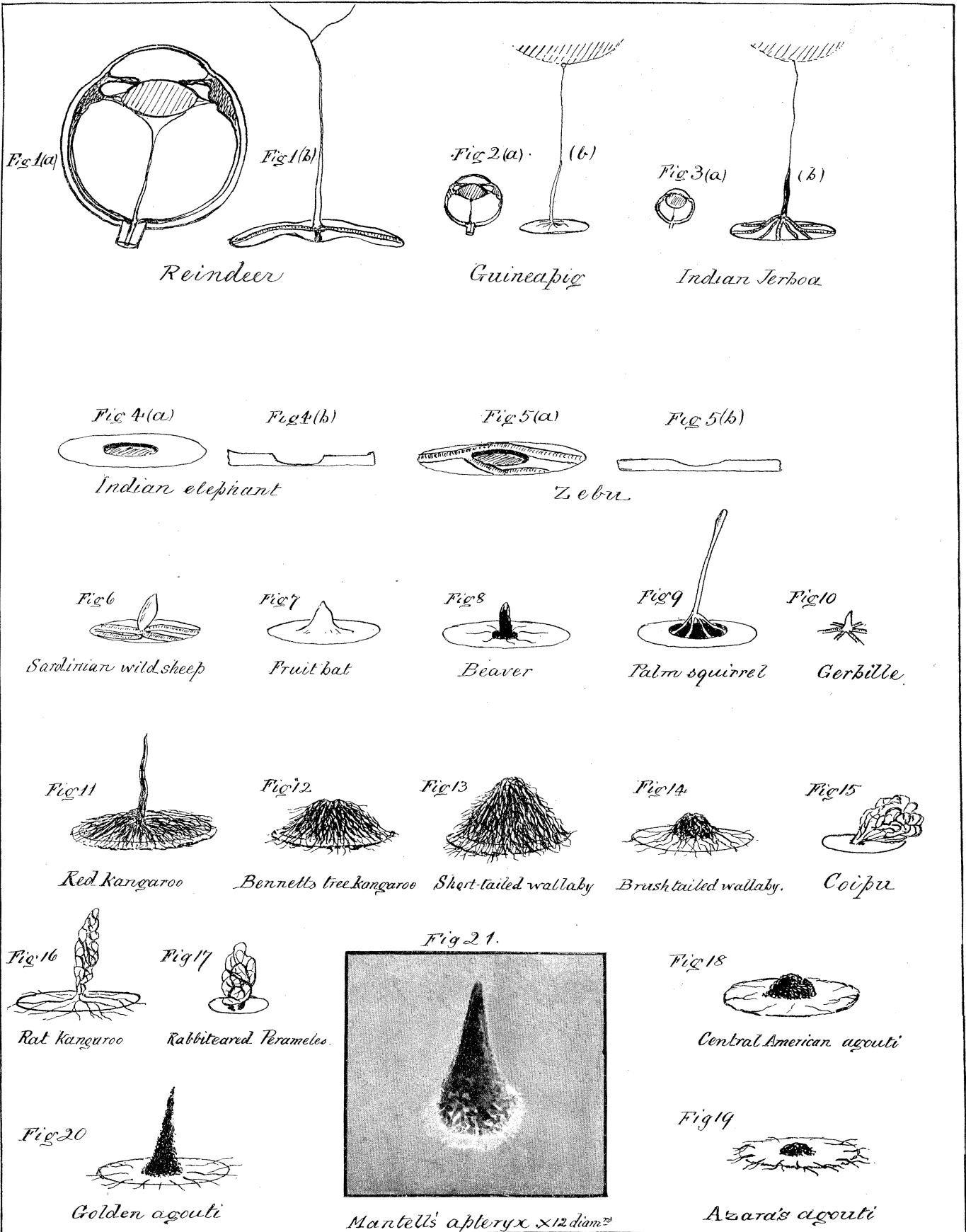


Fig. 4.



Primitive and Retrograde forms of the PECTEN and other vestigial remains occurring in the Mammalia.



Types of the Appendages to the Iris occurring in the Ungulates, illustrating the successive stages from the Corpus nigrum of the Equidæ to the functionally active Umbraculum in the Hyrax.

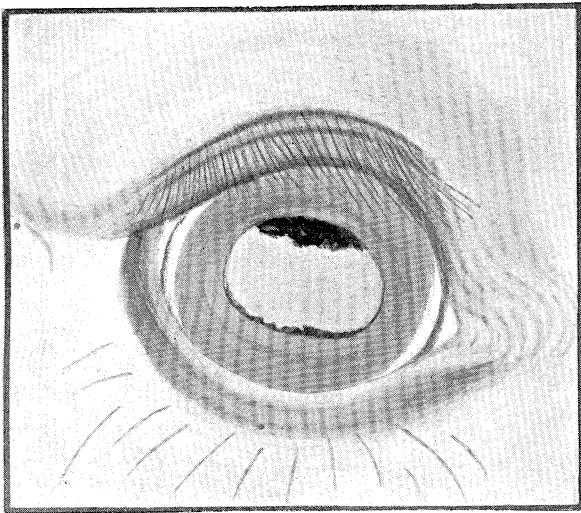


Fig. 1 Horse

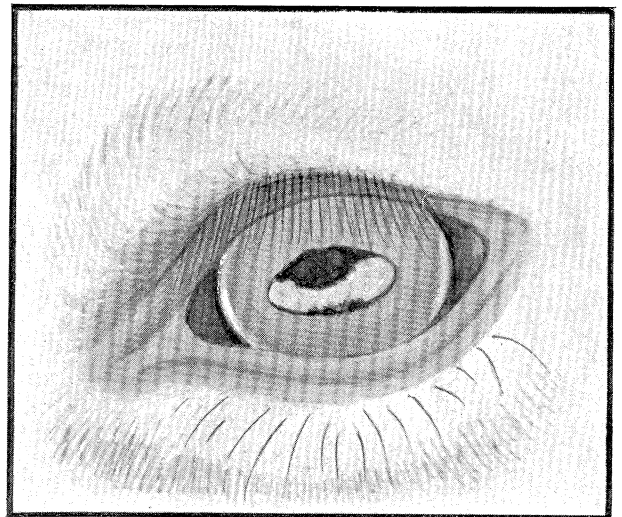
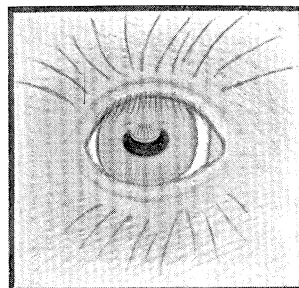


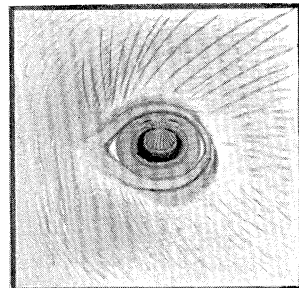
Fig. 2 Wild Ass

Fig. 7



Hyrax Dorsalis

Fig. 8



Hyrax Capensis

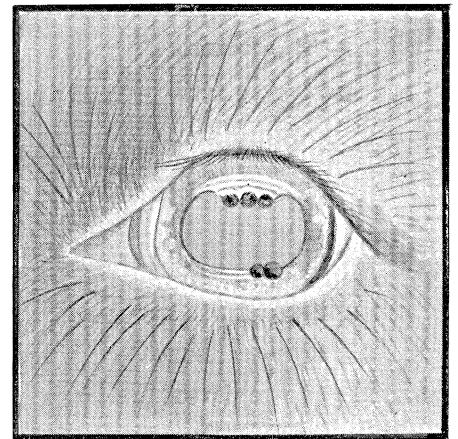


Fig. 4 Goat

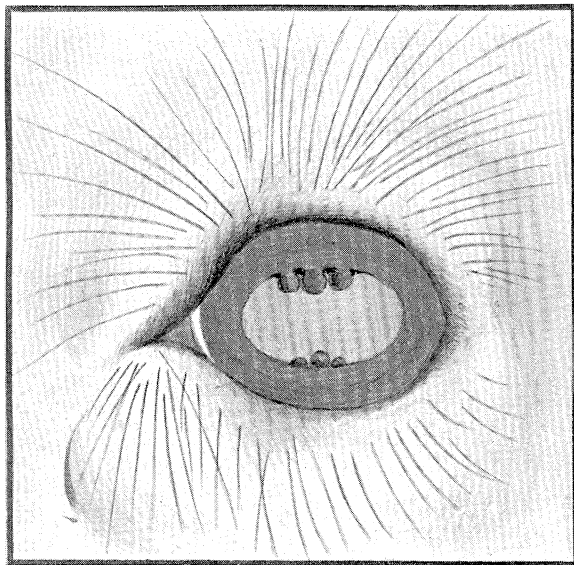


Fig. 3 Dorcas Gazelle

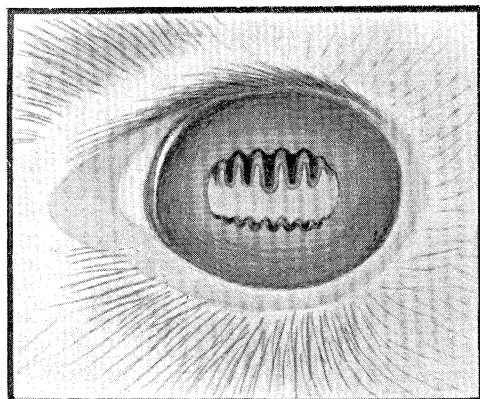


Fig. 5 Camel

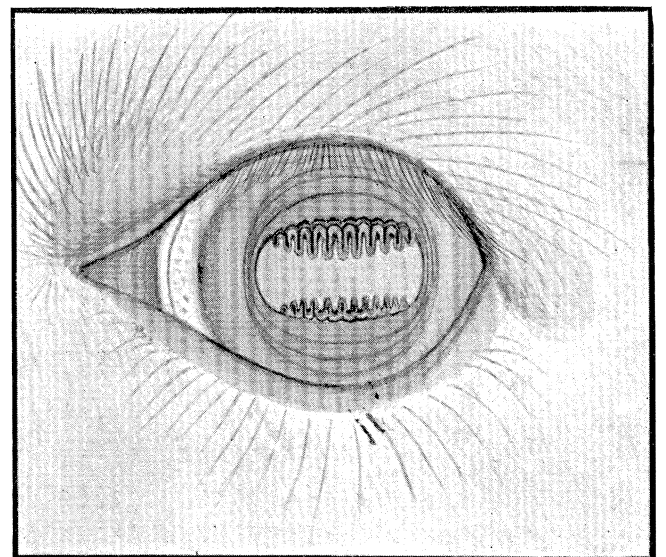


Fig. 6 Llama

Drawn from life. Natural size.

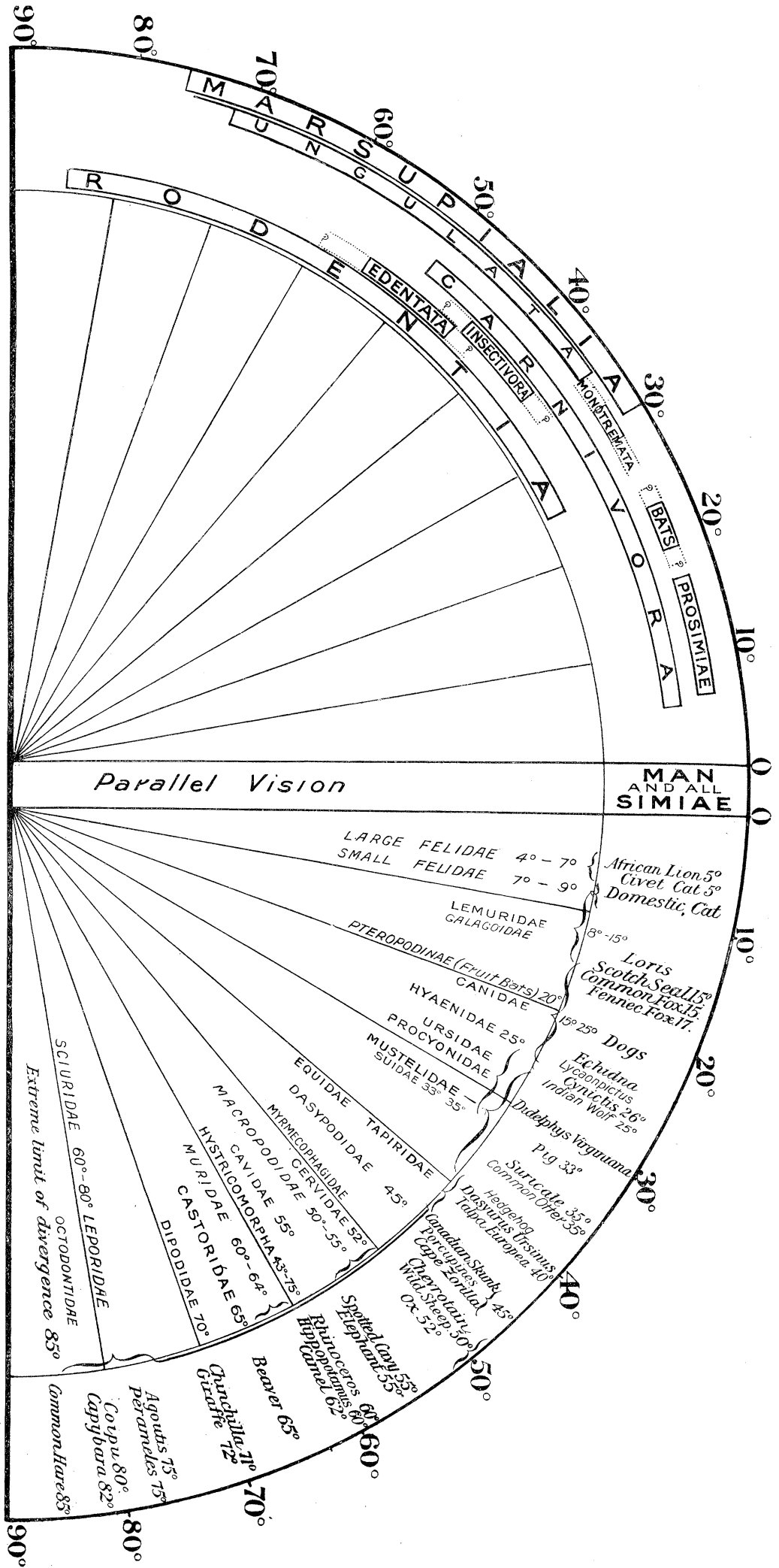
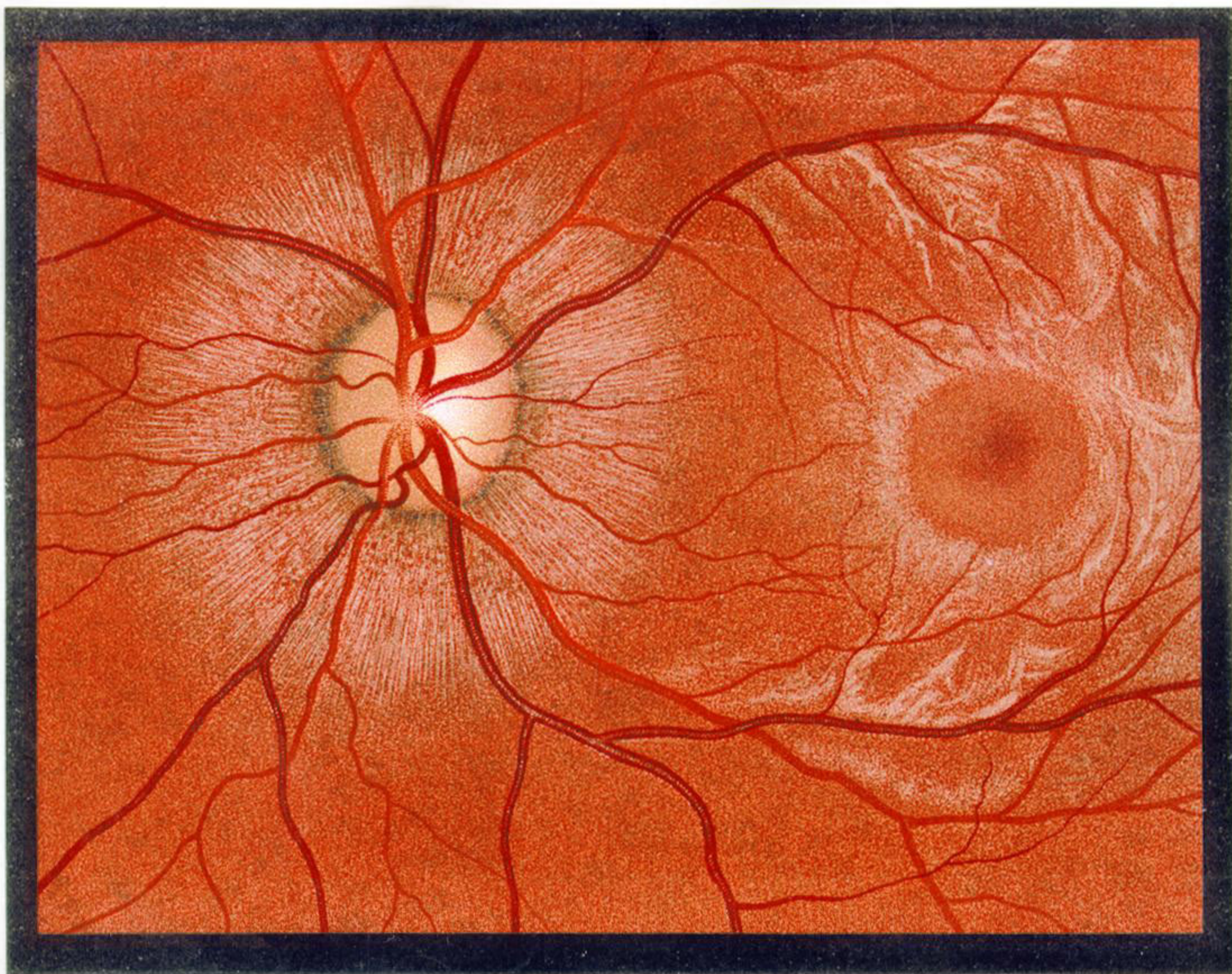


Diagram showing the divergence of the optical axes in the Mammalia. The Natural Orders are represented on the left-hand quadrant, the Families, Genera and Species on the right.

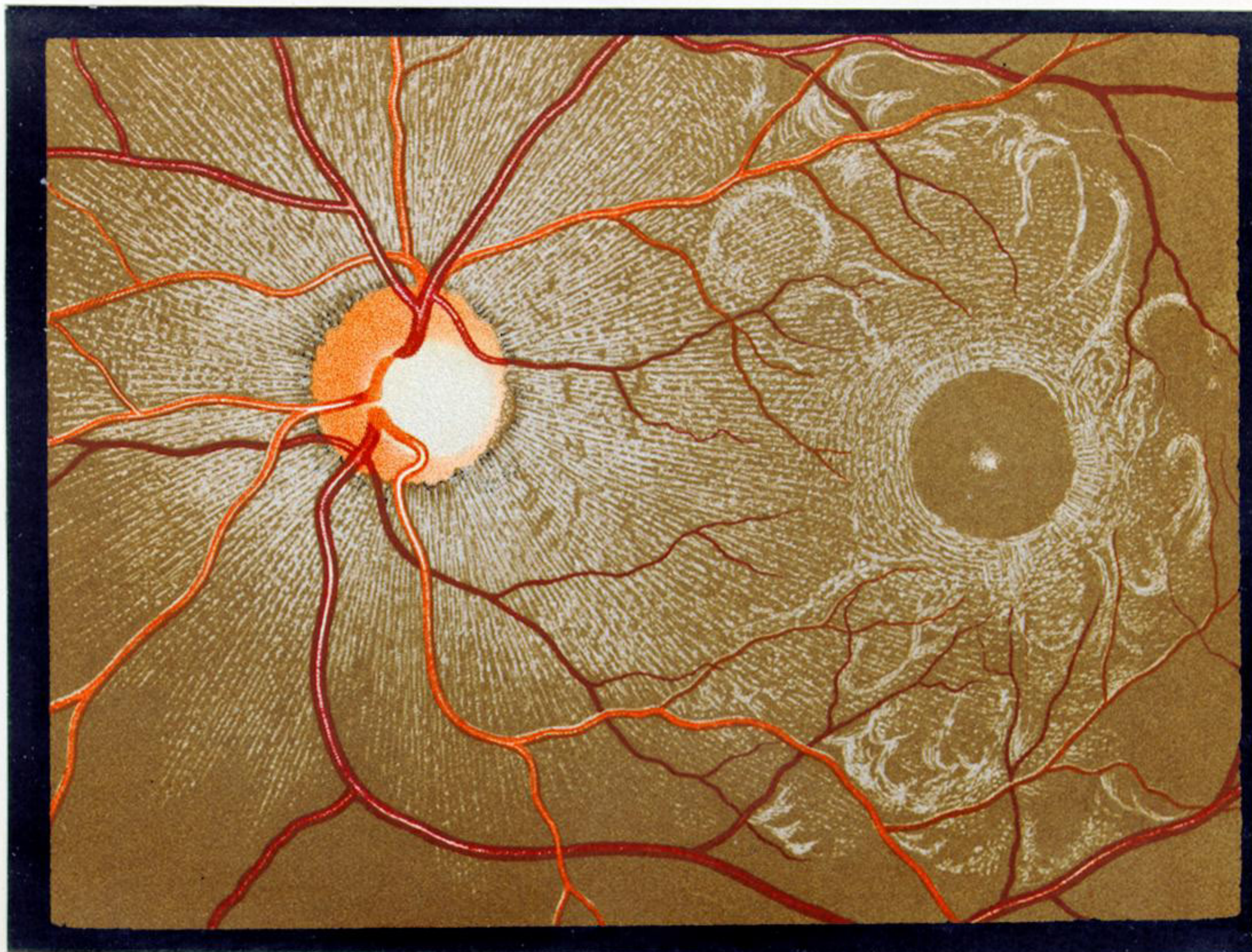
1. HOMO



HOMO.

DARK-HAIRED EUROPEAN.

1. HOMO.



HOMO.

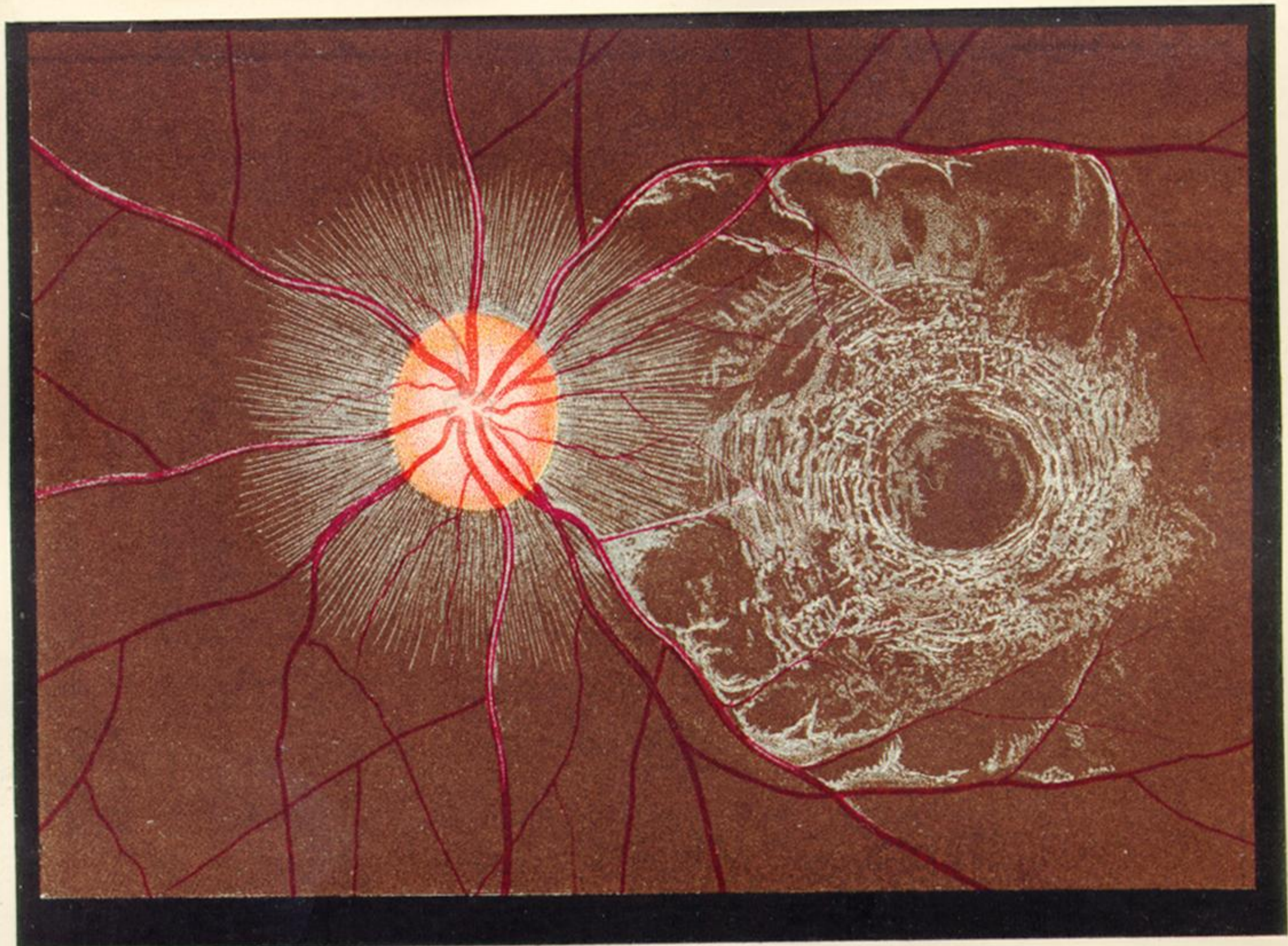
NUBIAN YOUTH.

PLATE 1.

1. Fundus oculi (left eye) of a dark-haired English girl, *æt.* 20. The mottled choroidal stroma can be indistinctly seen in the background. Translucent fibres of the optic nerve can be traced a short distance beyond the disc. The circular macula area is sharply defined, and surrounded by a reflex ring. Reflexes which vary with the direction of the entering light, and position of the observer's eyes, can be traced along the vessels.

2. Fundus oculi (left eye) of a Nubian youth, *æt.* 17. The fundus is of a chocolate colour, and the reflexes are very pronounced, extending over the whole central area. The translucent nerve fibres can also be traced for a much greater distance beyond the disc. The macula is circular and well defined, and surrounded by a brilliant reflex ring. The choroidal vessels are quite invisible.

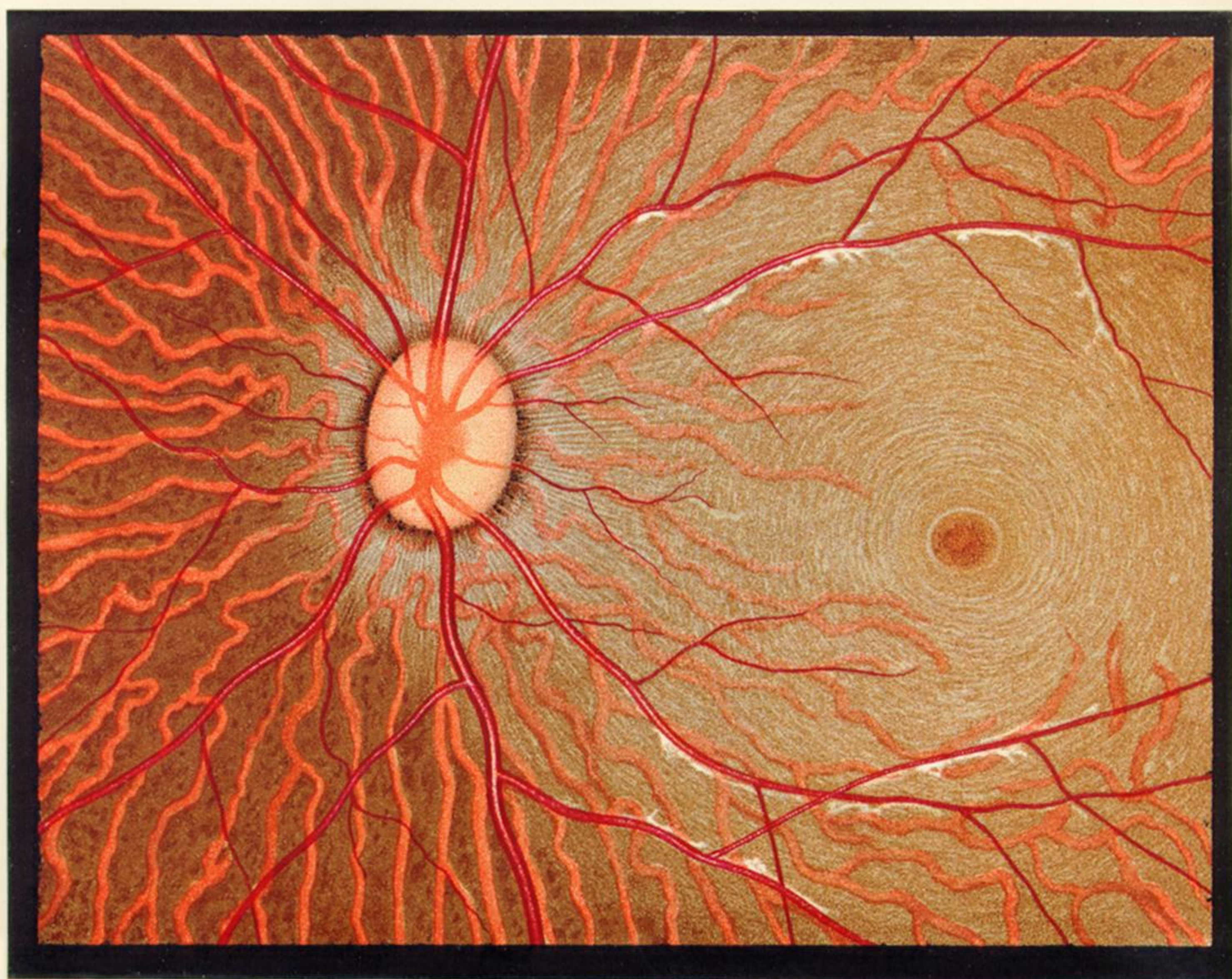
2. TROGLODYTES.



T. NIGER.

CHIMPANZEE.

4. HYLOBATES.



H. ALBIMANUS.

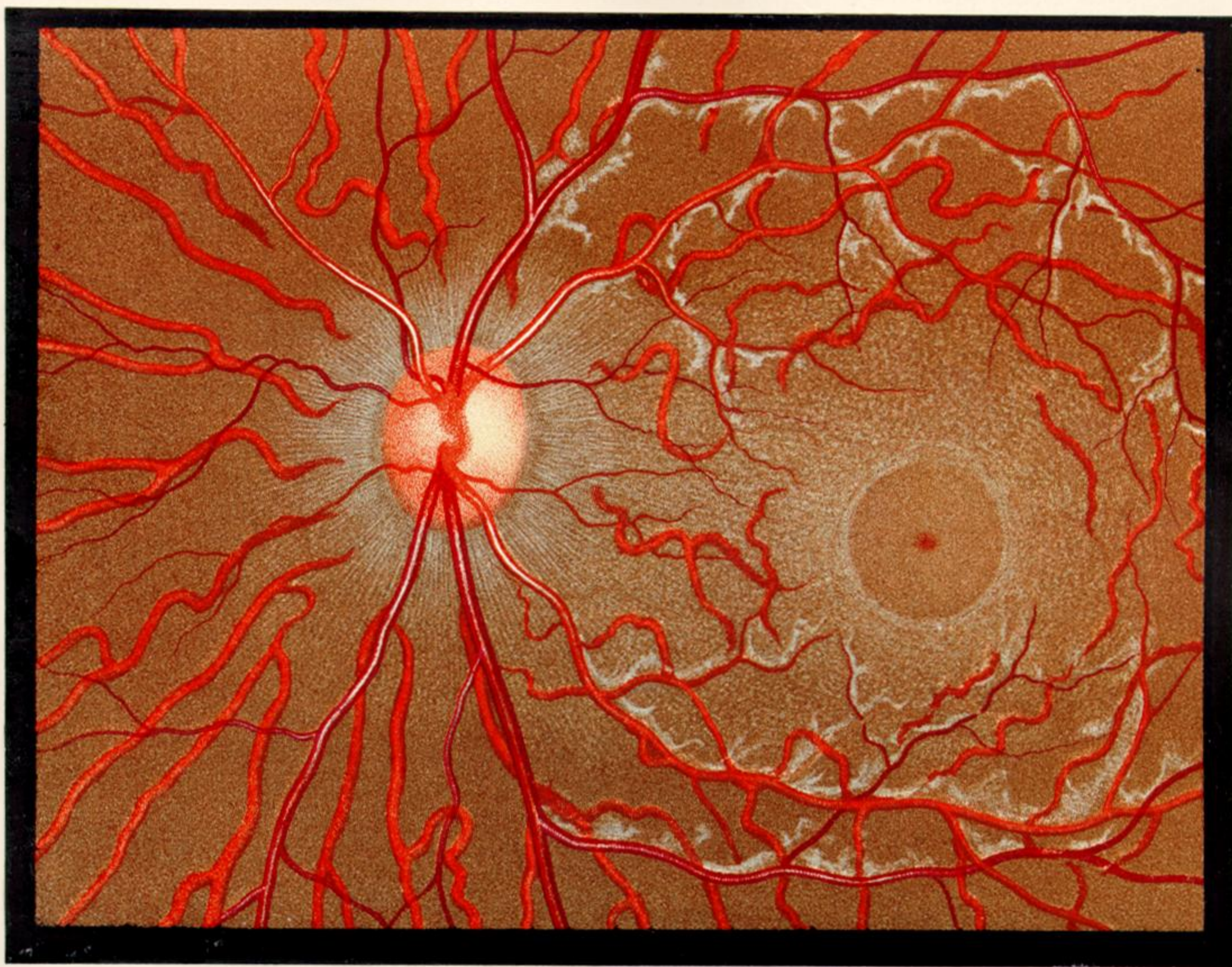
WHITE HANDED GIBBON.

PLATE 2.

1. Fundus oculi (left eye) of a Chimpanzee. The resemblance between this drawing and that of the Nubian youth is most striking. Beyond the facts that there is less differentiation of colour between the retinal arteries and veins, and that the vessels branch out somewhat straighter, no differences can be detected.

2. Fundus oculi (left eye) of the White-handed Gibbon. The nerve-fibre layer and reflexes are prominent. The macula area is very small. The brown choroidal stroma covered with black dots can be seen outside the central area, where it is obscured by the reflexes. On all sides bifurcating choroidal vessels radiate from the vicinity of the disc, and can be traced to the periphery of the field.

1. MACACUS.



M. CYNOMOLGUS.

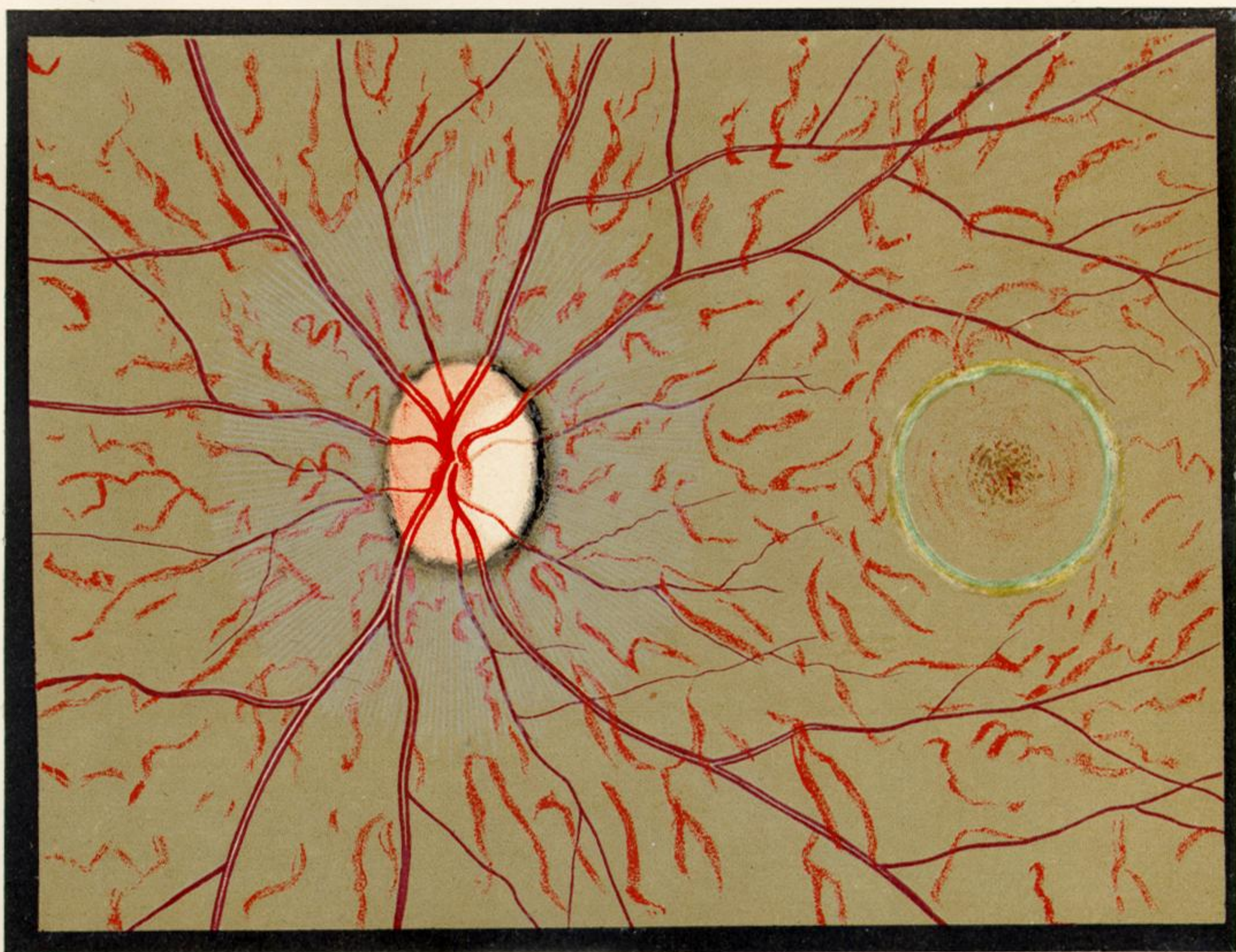MACAQUE.

A. SIMIAE.

b. ARCTOPITHECI.

HAPALIDAE.

HAPALE.



H. PENICILLATA.

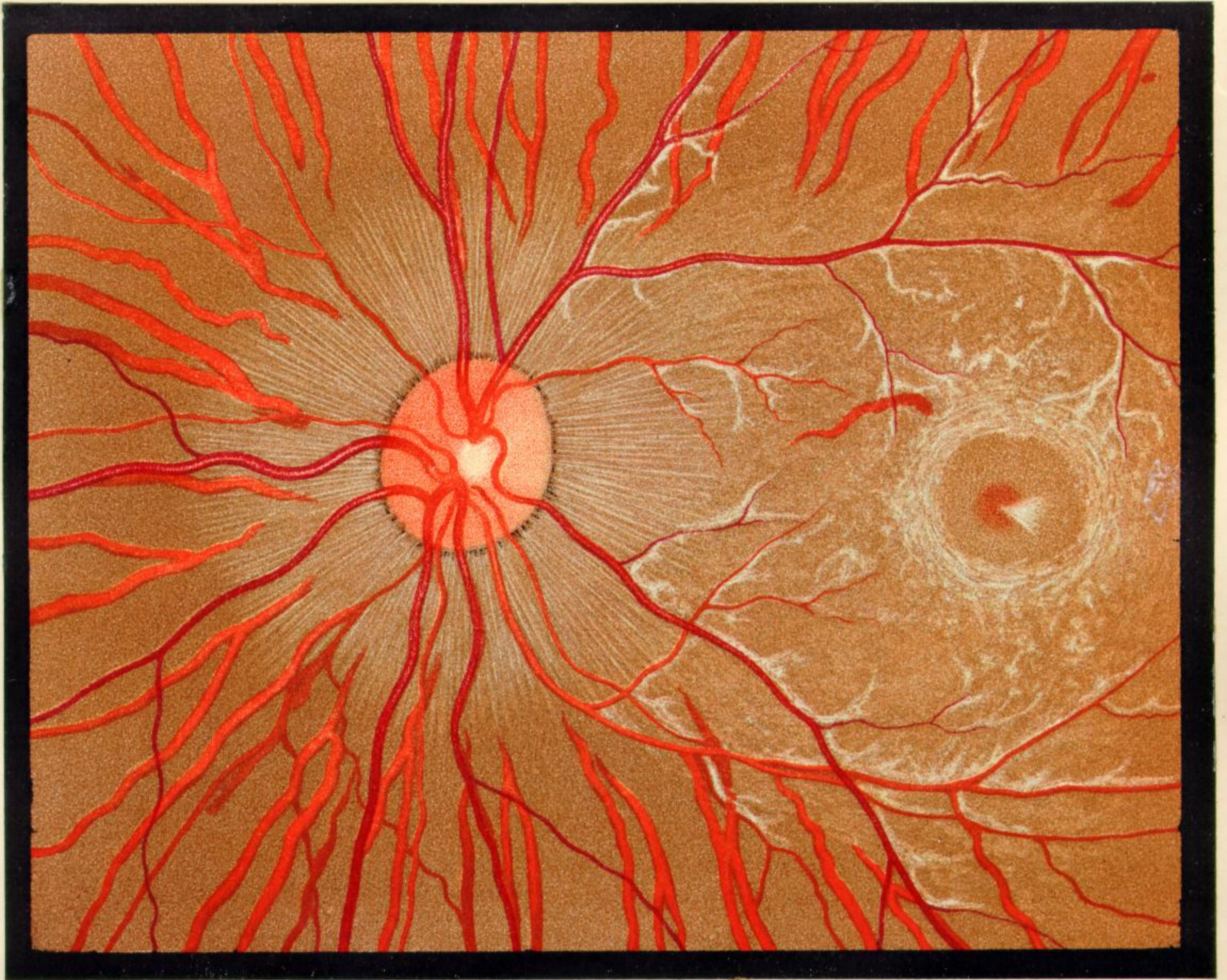BLACK-EARED MARMOSET.

PLATE 3.

1. Fundus oculi (left eye) of a Macaque. The background is without dots, and the choroidal vessels are arranged as in the Gibbon, only they are much fewer in number. The macula resembles that of man.

2. Fundus oculi (left eye) of a Black-eared Marmoset. The fundus is slate-coloured and the choroidal vessels few and interrupted. The macula is peculiar, being very large and surrounded by a prismatic reflex ring, yellow inside, and bluish-green externally. This peculiarity is also observed in the Chrysothrix.

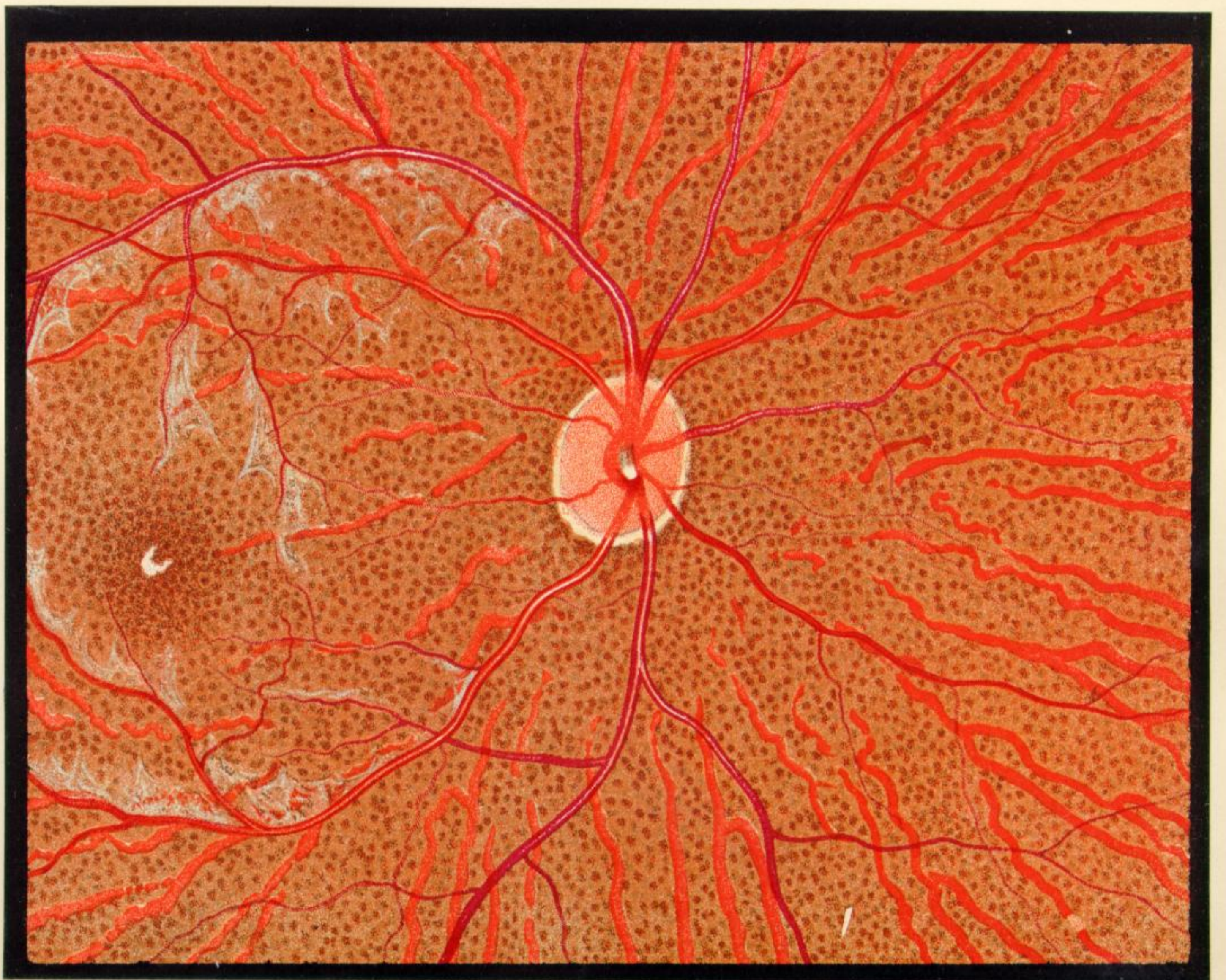3. ATELES.



A. GEOFFROYI.

BLACK HEADED SPIDER-MONKEY.

6. NYCTIPITHECUS.



N. LEMURINUS.

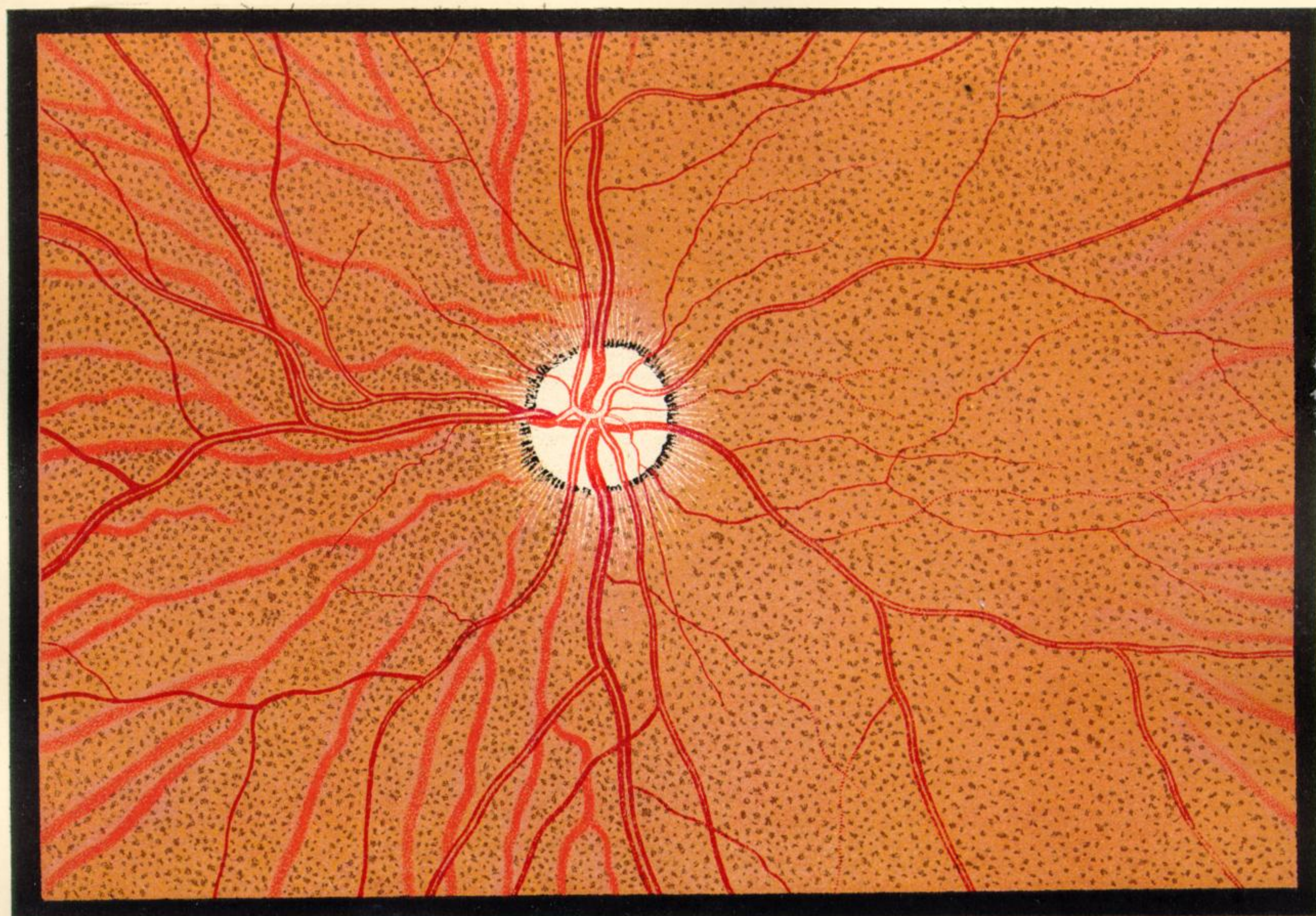
LEMURINE DOUROUCOULI.

PLATE 4.

1. Fundus oculi (left eye) of a Black-headed Spider-monkey. Though this is a New World monkey its eye closely resembles that of the Macaque, showing that the eye does not admit of any pronounced demarcation between the catarrhine and platyrrhine Simiæ.

2. Fundus oculi (right eye) of the Lemurine Douroucouli. The macula is present, but the macula ring has disappeared. The whole background is covered with dots, as in the case of the Lemurs, to which this fundus bears a close resemblance, were it not for the presence of a macula and a pink disc.

LEMUR.



L. CORONATUS.

CROWN LEMUR.

GALAGO.



G. MONTEIRI

MONTEIRO'S GALAGO.

PLATE 5.


1. Fundus oculi (right eye) of the Common Lemur. The macula, as in all animals below the true monkeys, is entirely wanting; but its apparent position is indicated by the absence of the large retinal vessels and all choroidal vessels over a certain area. The disc, as in all Lemurs, is chalky-white.

2. Fundus oculi of MONTEIRO'S Galago. We have evidently here already a tapetum lucidum and a tapetum nigrum, similar to those common to the carnivora. The background resembles burnished gold, and can only be feebly imitated in the drawing. If a brilliant light be focussed on it by means of a large lens, it will give a better idea of the original. The golden background is strewn over at regular intervals with stellate dots. The disc is dark grey, approaching black. The entire periphery of the fundus is covered with a dense network of pigment.

II. CHIROPTERA.

PTEROPODIDAE.

PTEROPUS.



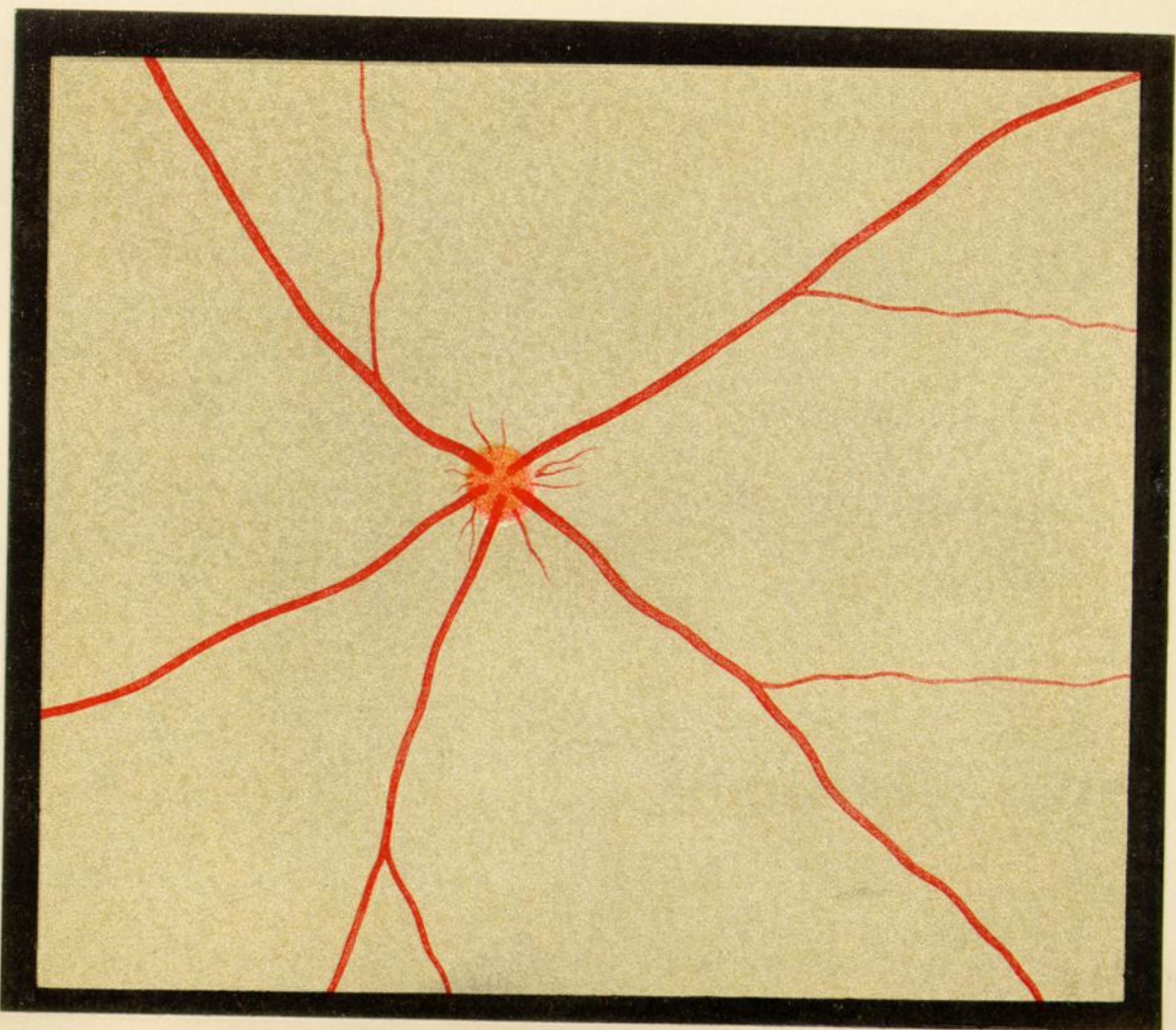
P. POLIOCEPHALUS.

AUSTRALIAN FRUIT-BAT.

III. INSECTIVORA.

SORICIDAE.

ERINACEUS.



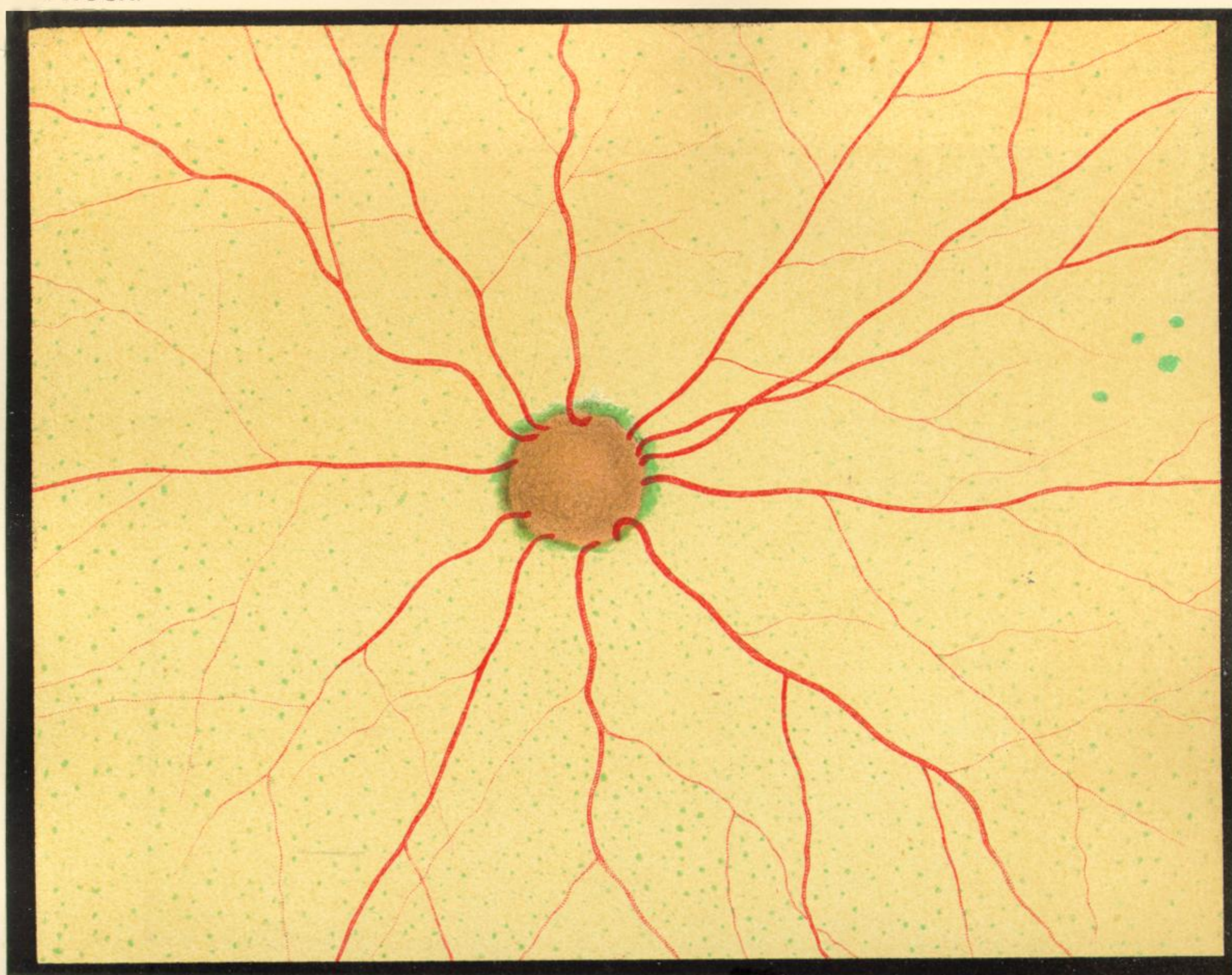
E. EUROPÆUS.

COMMON HEDGEHOG.

PLATE 6.

1. Fundus oculi of the Australian Fruit-bat. The entire fundus is uniform in colour and appearance, and very primitive. The colour is light terra-cotta, uniformly covered with large round dark dots, which viewed with the ophthalmoscope might be taken for deep pits. The disc is circular and greyish-white. There are no vessels of any kind visible, except a single minute capillary in the centre of the disc.

2. Fundus oculi of a Common Hedgehog. The background is uniformly light grey. The disc is small, circular, and pink. From this two sets of vessels proceed, viz., a peripheral set, which emerge from its edge in the form of five branches of minute capillary threads, and a central set, consisting of five large retinal vessels, which radiate to the periphery like the arms of a Starfish. There are no choroidal vessels visible, nor can the arteries be in any way distinguished from the veins.

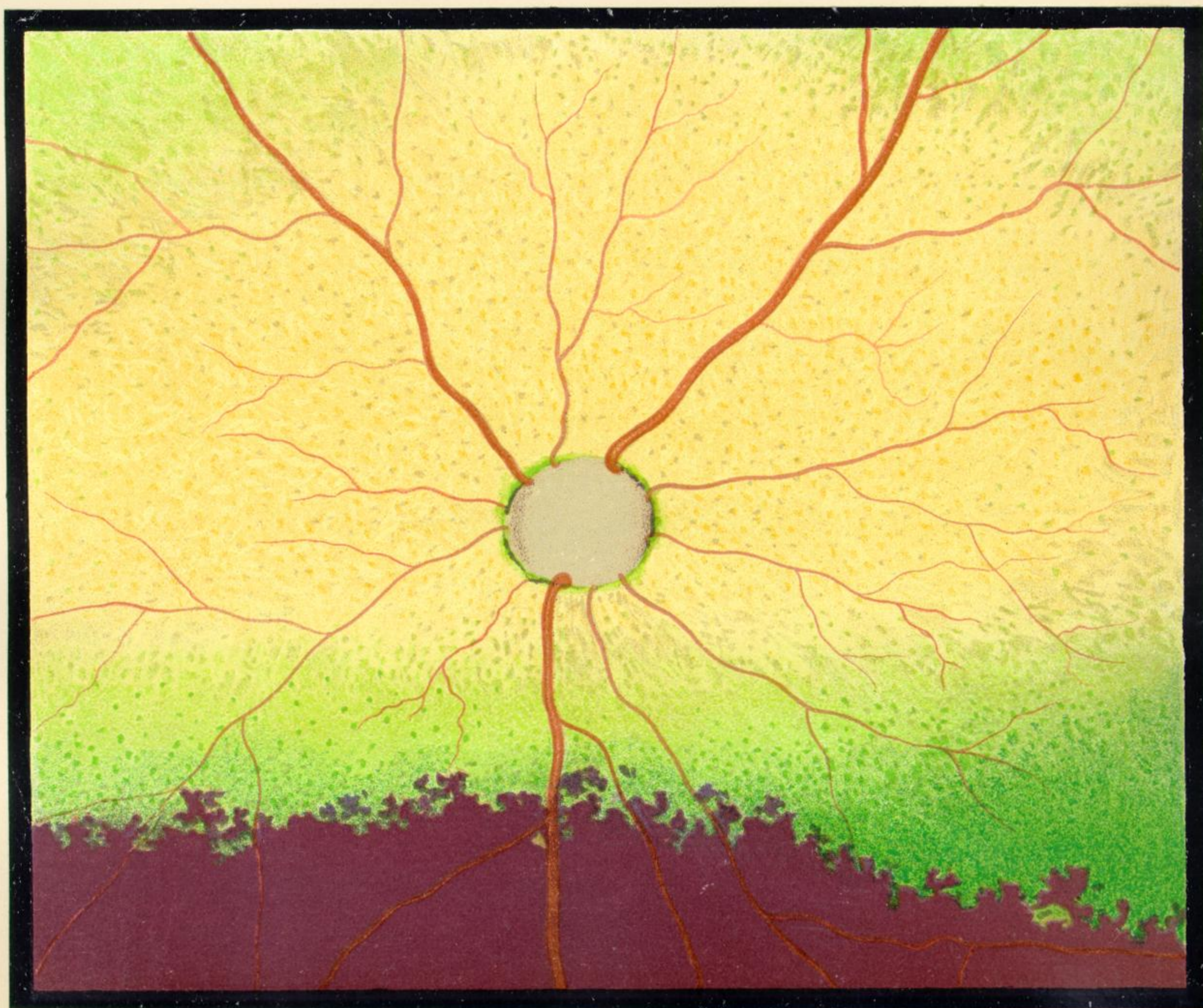


P. VITULINA.

THE COMMON SEAL.

B. FISSIPEDIA.
FELIS.

I. FELIDAE.



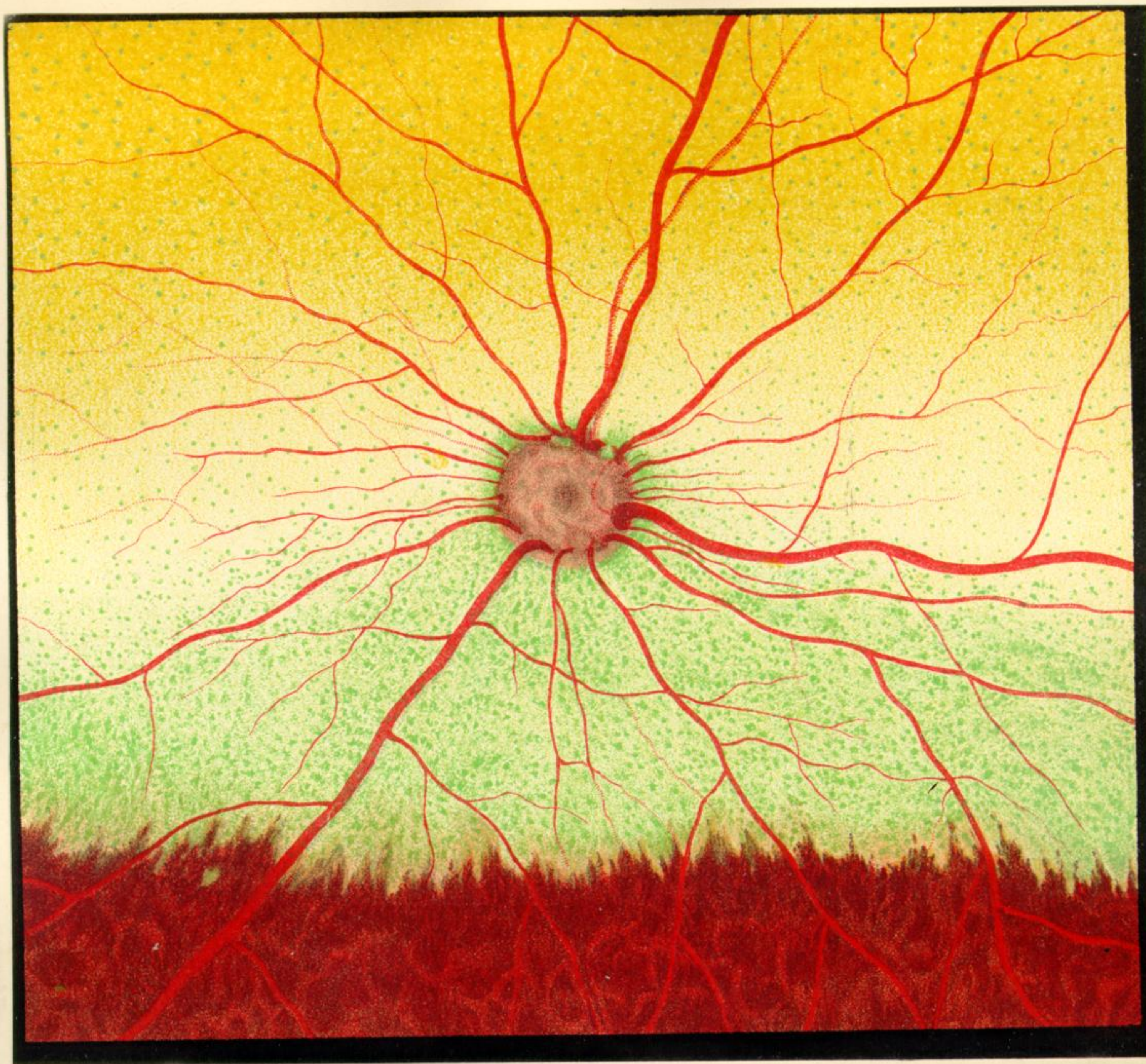F. SERVAL.

SERVAL.

PLATE 7.

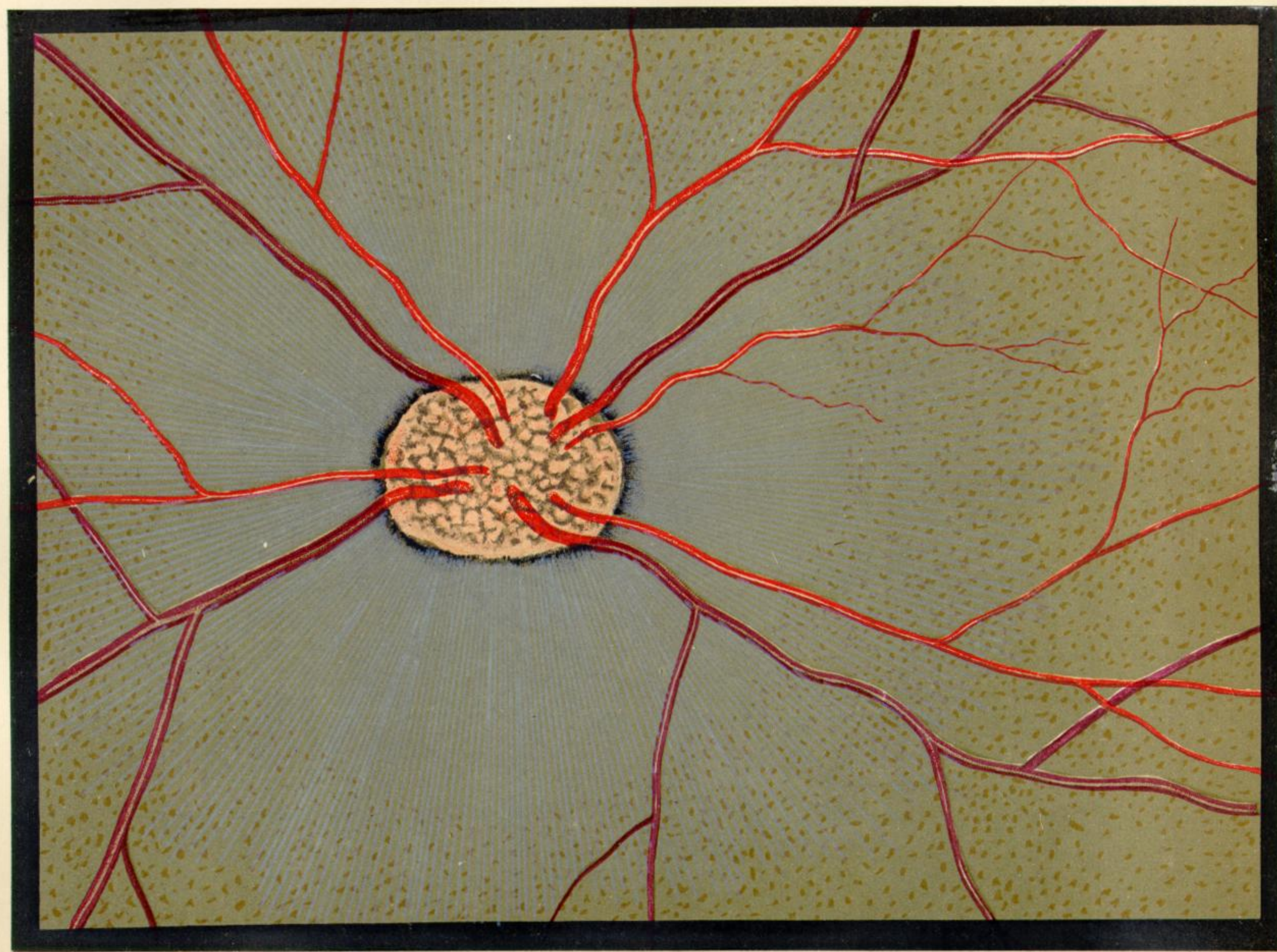
1. Fundus oculi of the Common Seal. The background is of a brilliant pale yellow colour, sprinkled with minute green dots. The disc is pale brownish-red, surrounded by a green border. About a dozen thin vessels curl over its margin, and radiate to the periphery. There is no distinction between arteries and veins.

2. Fundus oculi of the Serval. The three zones common to nearly all the Fissipedia are seen. The innermost zone occupies roughly the third of the area of the circle. It is the area of best vision, and lies around the visual axis. It is light gold in colour and of extreme brilliancy. This golden layer is completely surrounded by an emerald-green layer of variable width, and this again by a dense brown-purple layer, which extends on all sides beyond the periphery of the field to the Ora Serrata. This last layer is probably insensitive to light.



G. VULGARIS.
CYNICTIS.

COMMON GENETTA.



C. PENICILLATA.

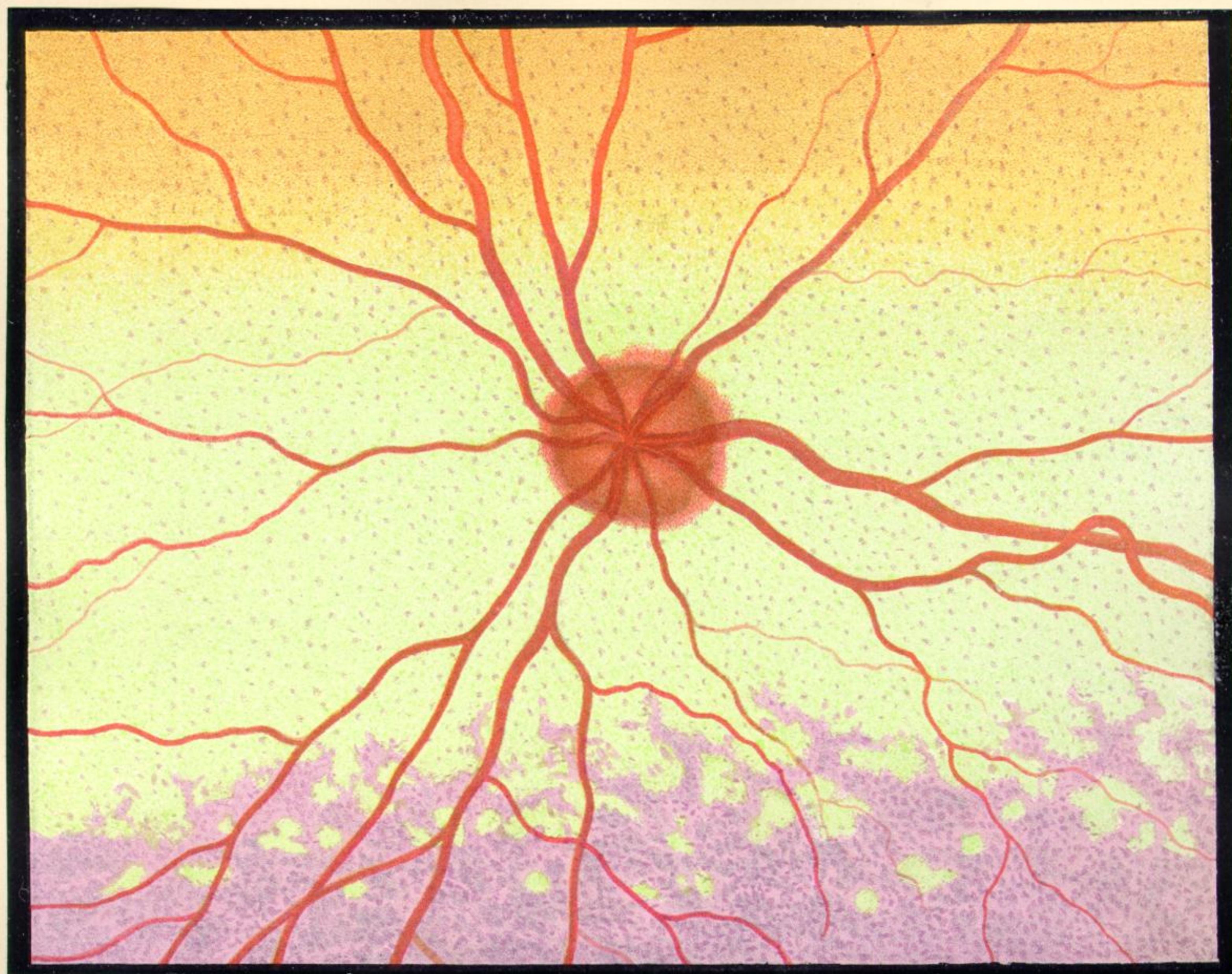LEVAILLANT'S CYNICTIS.

PLATE 8.

1. Fundus oculi of the Common Genetta. The golden central layer is situated much higher up than in the last animal. The intermediate green layer is very thin, and the peripheral layer dark red in colour.

2. Fundus oculi of LEVAILLANT'S Cynictis. The fundus is uniform in colour, possessing no differentiated zones, a peculiarity which distinguishes the Cynictis and the Suricate from all other Carnivora. The disc is horizontally oval and of abnormal size. It is covered with a pigmented reticulum.

HYAENA.



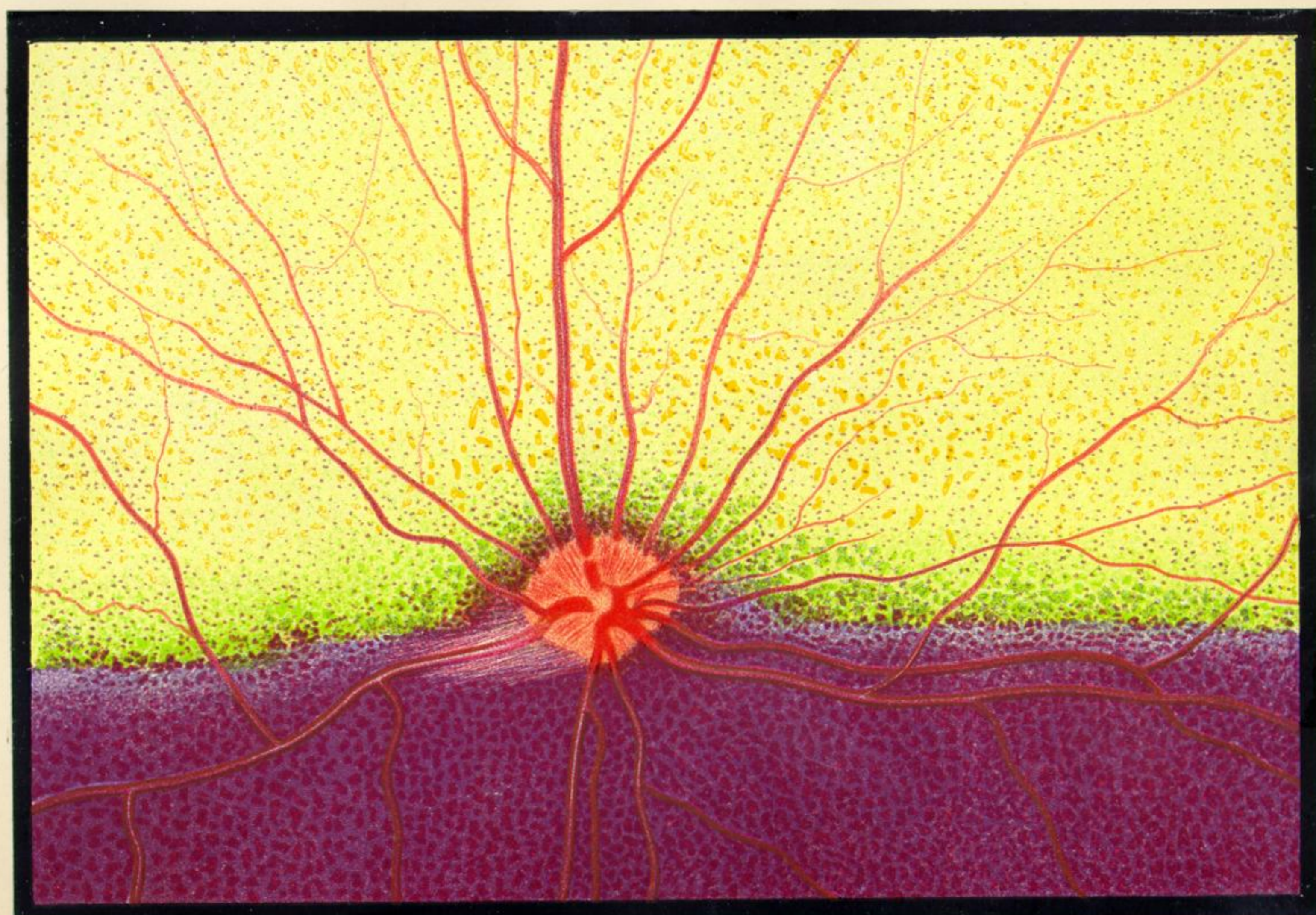HYAENA STRIATA.

STRIPED HYAENA.

B. FISSIPEDIA.

4. CANIDÆ.

CANIS.



C. MESOMELAS.

BLACK-BACKED JACKAL.

PLATE 9.

1. Fundus oculi of the Striped Hyæna. The central golden zone is high up above the disc, as is seen in all species of Hyænas, and the pale green zone is very broad. The peripheral zone is delicate mauve in colour.

2. Fundus oculi of a Jackal. The golden zone is very large, and the green zone correspondingly narrow. It is bordered externally by a narrow violet zone, which fuses with the deep brown-purple peripheral zone. The disc is bright pink and lozenge-shaped, a shape peculiar to the Jackals and Foxes.

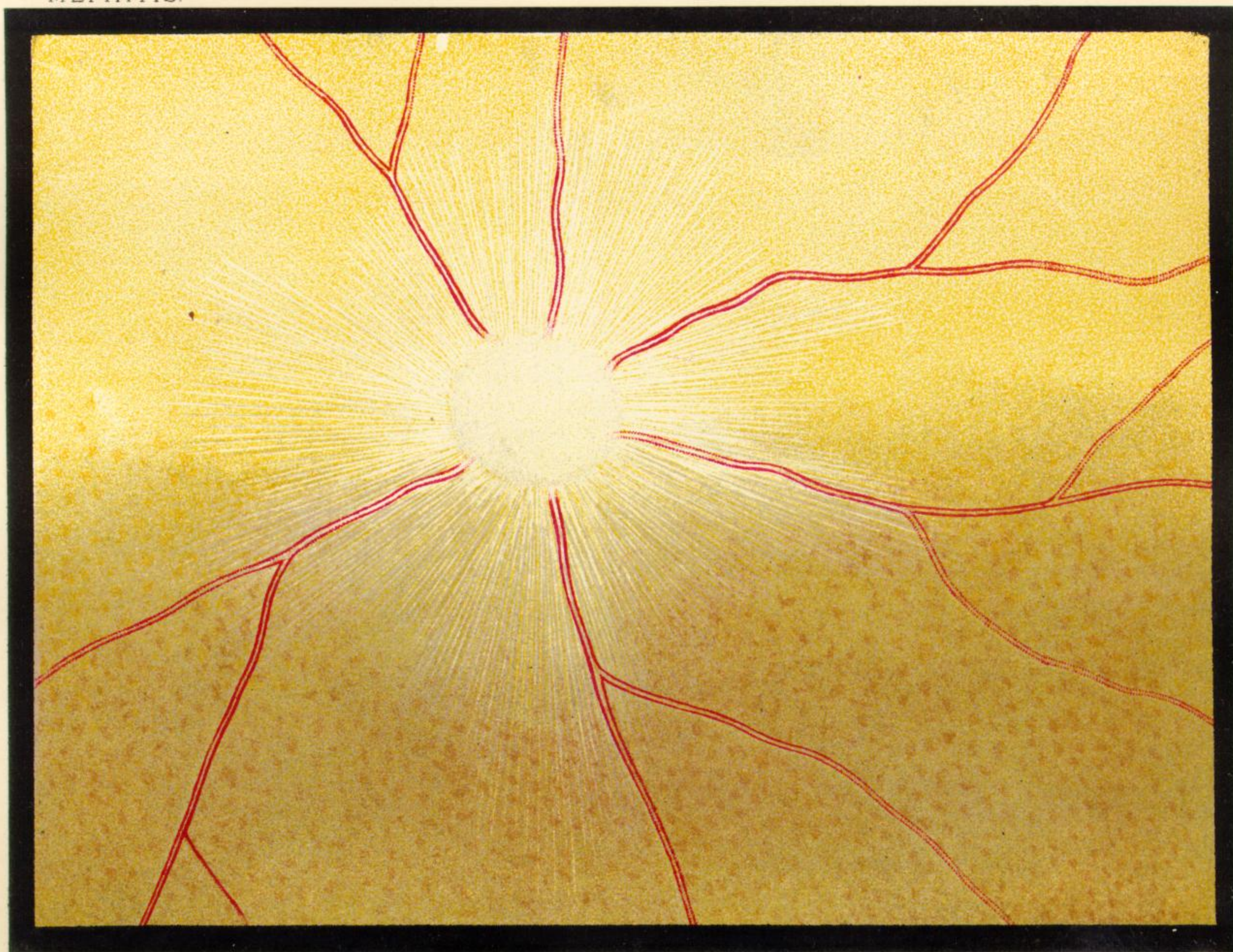GALICTIS.



G. BARBARA.

TAYRA.

MEPHITIS.



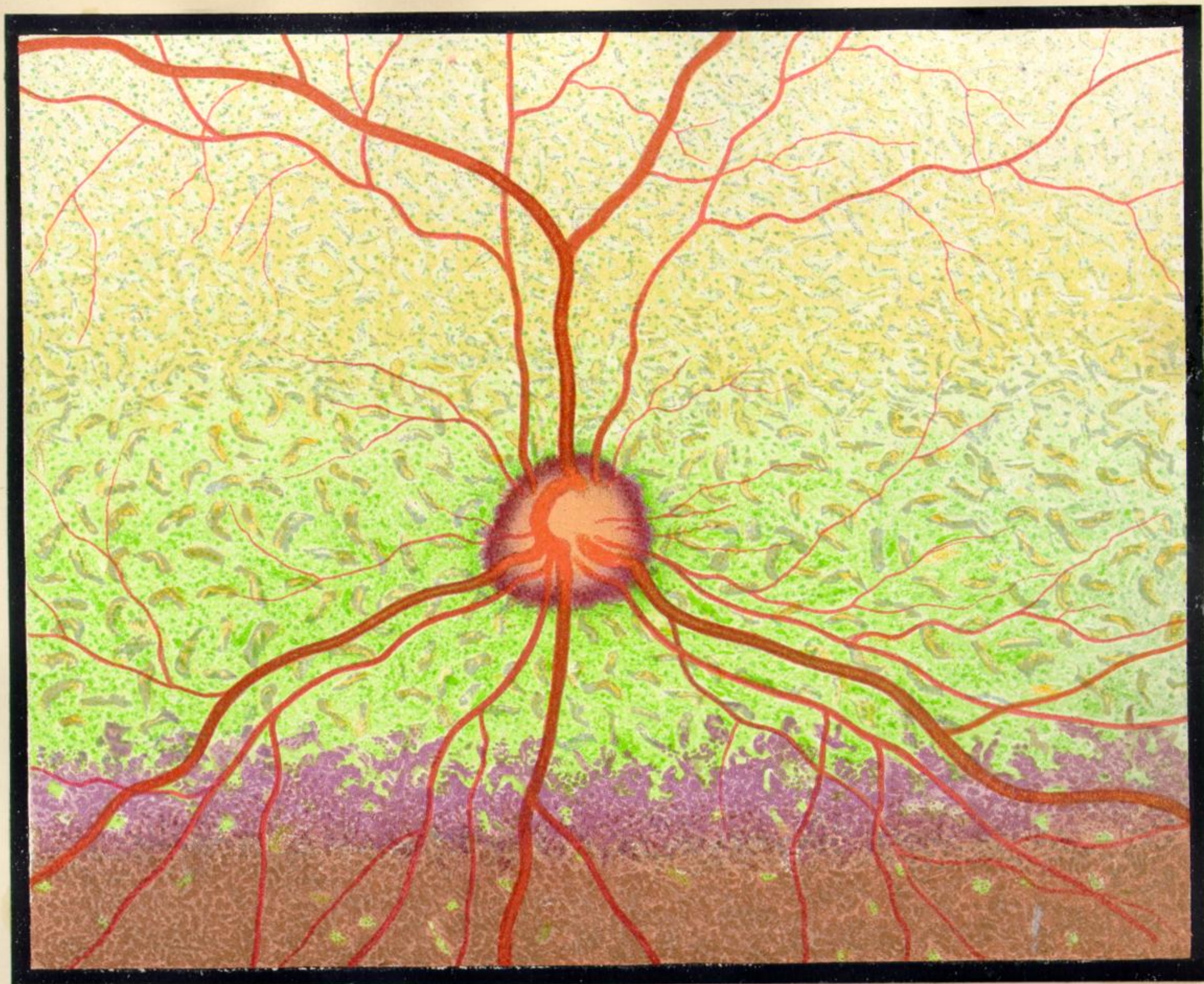
M. MEPHITICA.

CANADIAN SKUNK.

PLATE 10.

1. Fundus oculi of the Tayra. The fundus is green, and mottled all over with irregular patches of orange-gold. The peripheral area is of a rich brown colour.

2. Fundus oculi of the Canadian Skunk. A most remarkable fundus. The sensitive area of vision extends from the level of the disc upwards. The peripheral zone is very broad and of a yellow-buff colour, stippled with light brown dots.

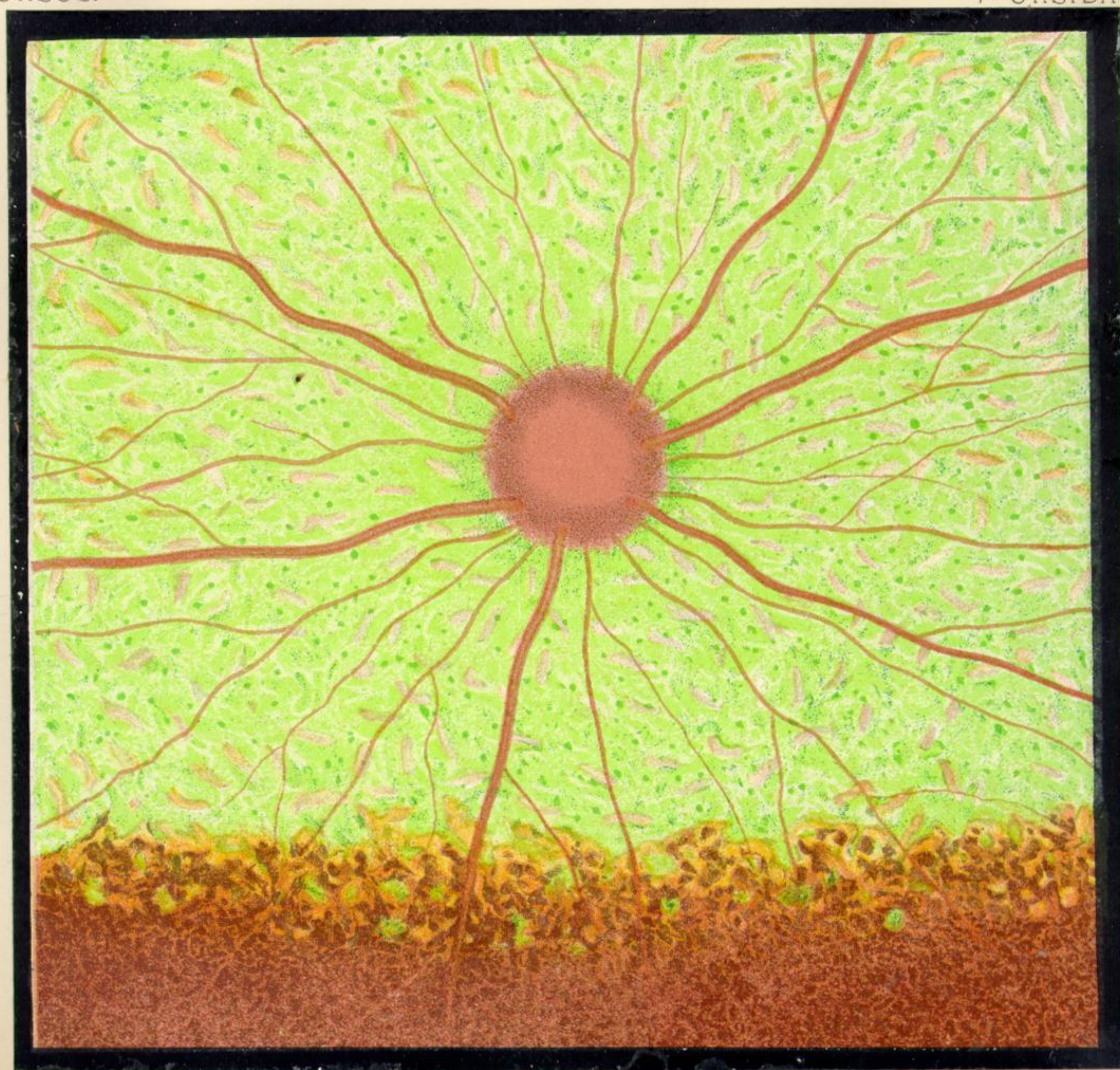


P. LOTOR.

THE RACCOON.

URSUS.

7. URSIDAE.



U. AMERICANUS.

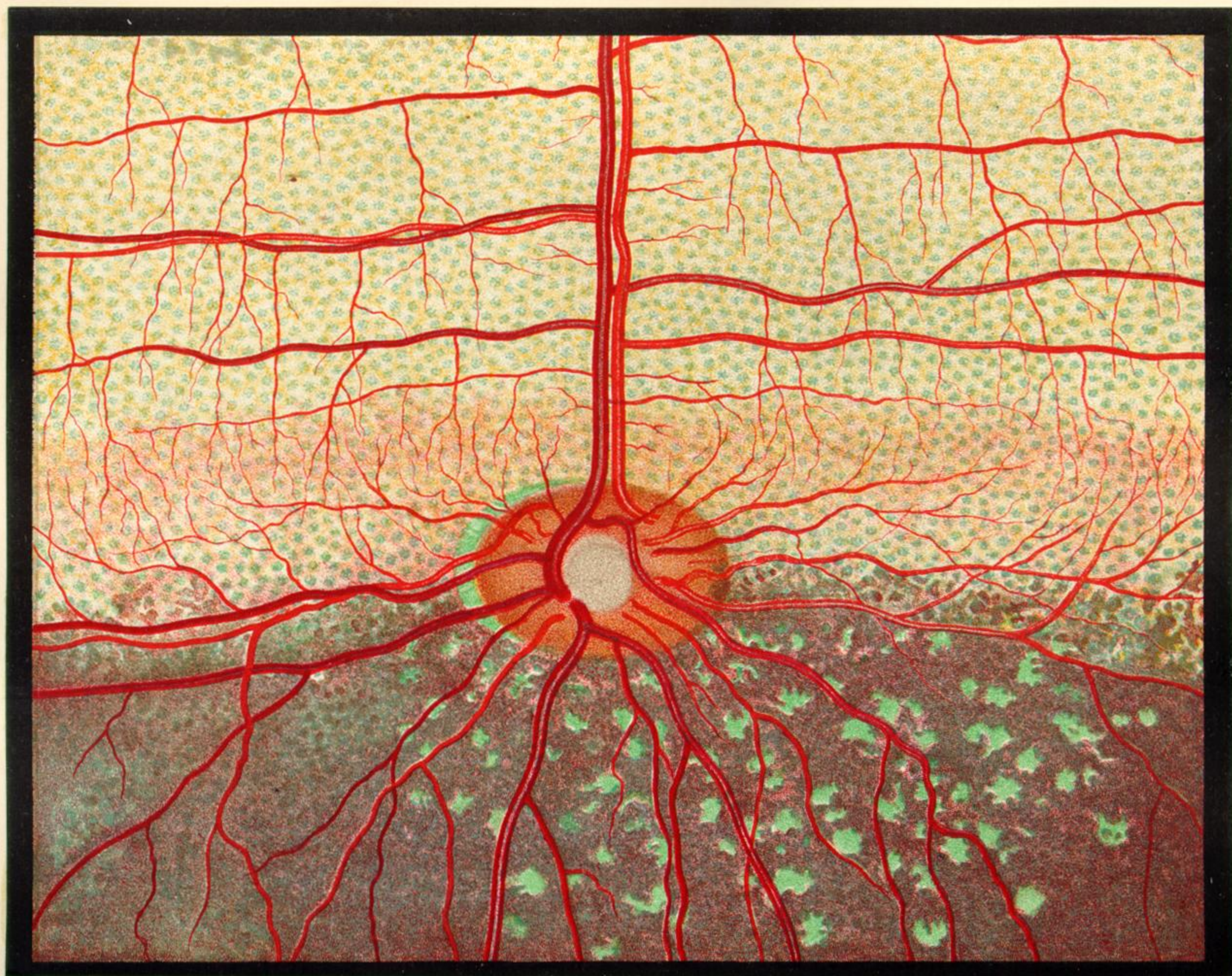
BLACK BEAR.

PLATE 11.

1. Fundus oculi of the Racoon. The pale golden-yellow zone is mottled and covered with green dots, while the green zone has a number of rice-shaped yellow spots scattered over the field. The peripheral zone is partly mauve and partly brown in colour.

2. Fundus oculi of a Black Bear. The resemblance to that of the Racoon is very striking. The yellow zone is absent, and the peripheral zone has no mauve or purple fringe, but uniformly brown, resembling that seen in the outer part of the peripheral zone of the Racoon. The pigment has a crystalline appearance and is patchy, resembling coarse sugar strewn over the fundus.

BOS.

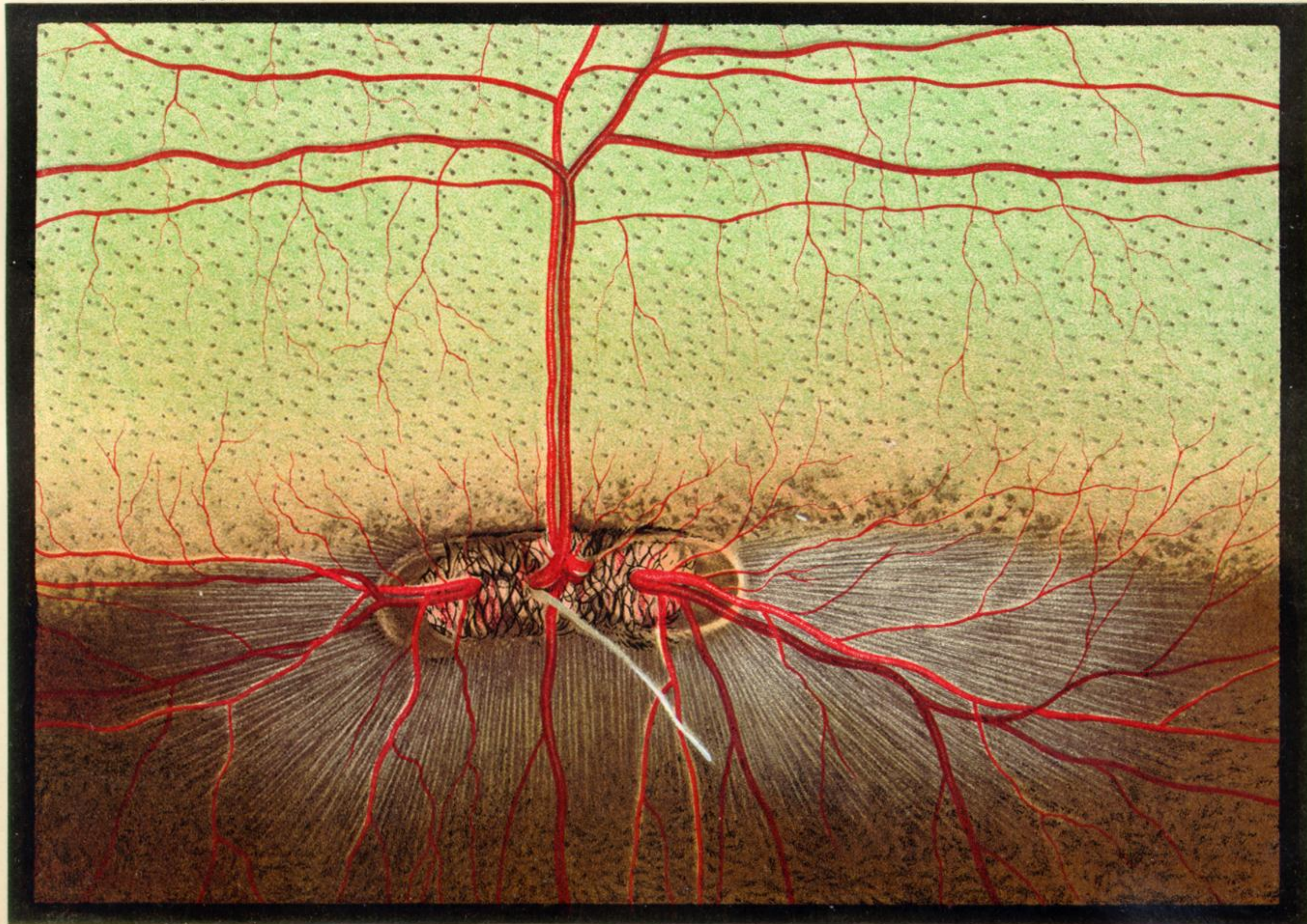


BOS. INDICUS.

INDIAN OX.

CERVUS.

2. CERVICORNIA.



CERVUS PORCINUS.

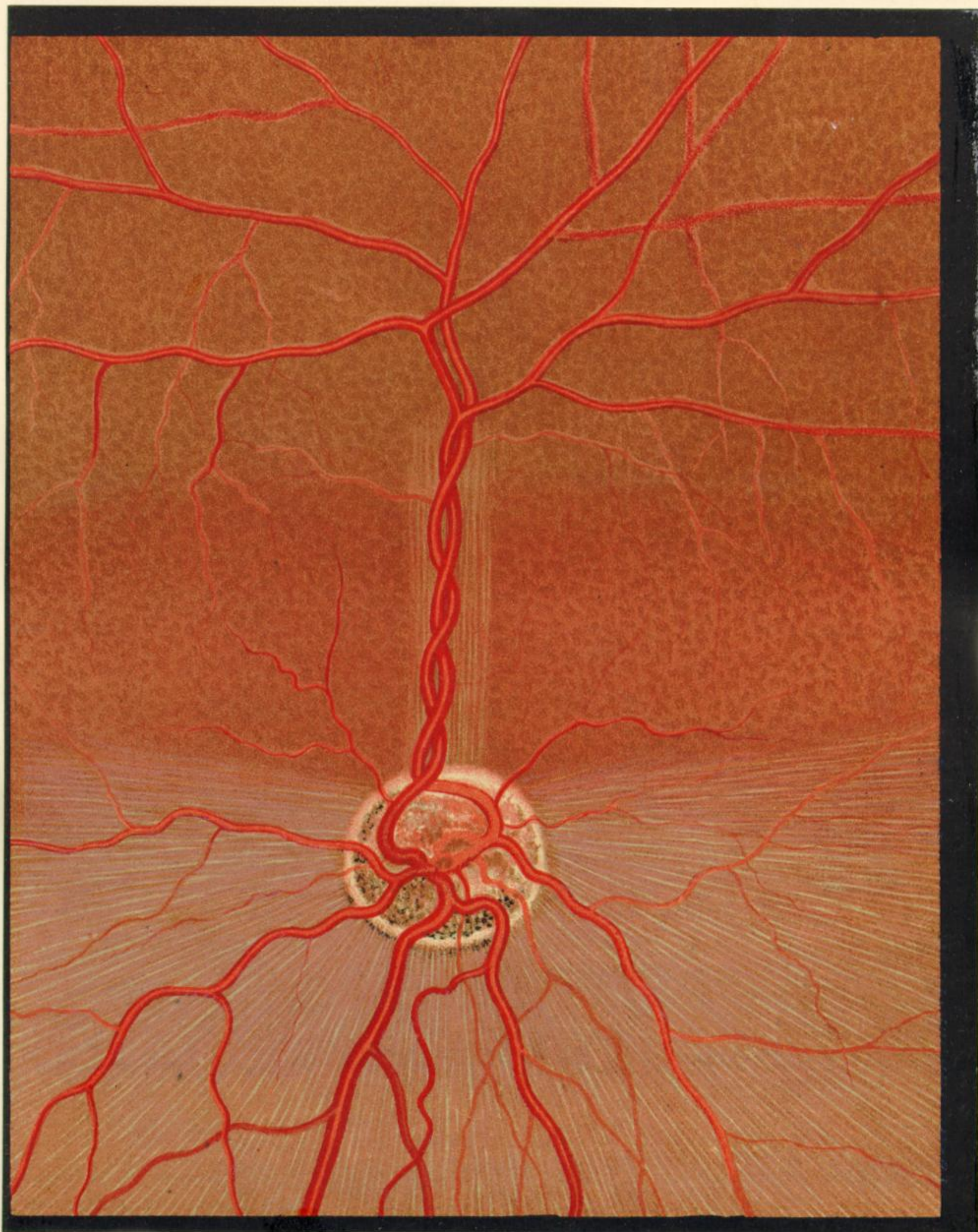
HOG-DEER.

PLATE 12.

1. Fundus oculi of the Indian Ox. The fundus is characteristic of nearly all Ruminants. The disc is horizontally oval and very large, with a central circular depression. The main trunks consist of one large pair (artery and vein) which runs straight up from the disc giving off horizontal branches from time to time, and numerous lateral and descending trunks, which ramify over the dark peripheral zone. Just above the disc, and extending in a horizontal manner on either side, is a rose-coloured band, nearly free from large vessels. It is probably the seat of acute vision.

2. Fundus oculi of the Hog Deer. The disc is remarkable, apparently consisting of three separate discs fused together. From the centre of each of these "discs" an arterial trunk proceeds, accompanied by its vein. The semi-opaque nerve fibres are very prominent and coarse, otherwise it resembles the fundus of the Ruminants.

CAMELUS.

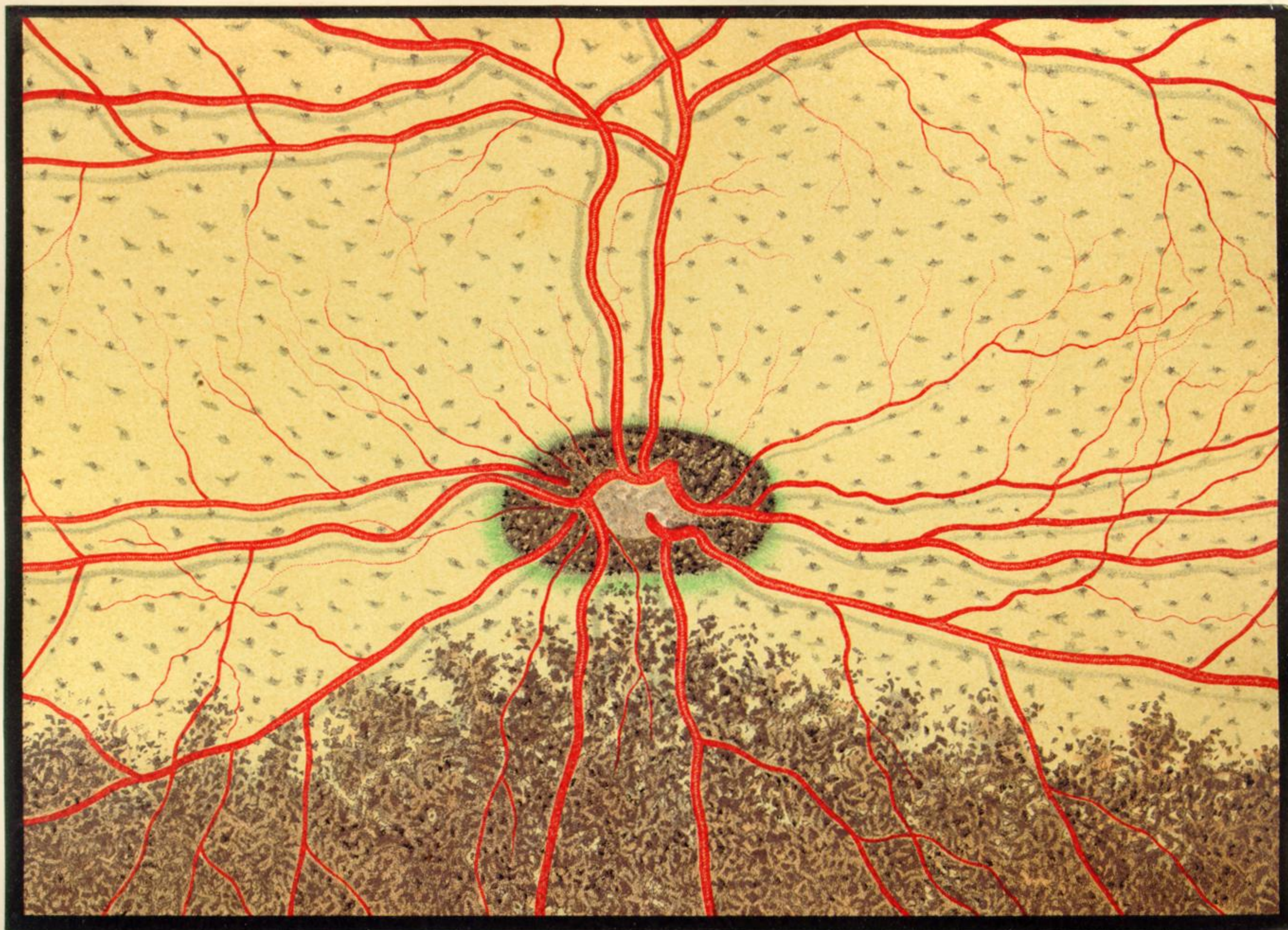


C. BACTRIANUS.

BACTRIAN CAMEL.

PLATE 13.

Fundus oculi of the Bactrian Camel. The fundus is uniformly chocolate-red in colour, the lower portion appearing paler, owing to the innumerable radiating nerve fibres. The disc is white, circular, and covered with a network of pigment. The main trunk ascends, intertwining with its vein, and gives off oblique and horizontal branches.



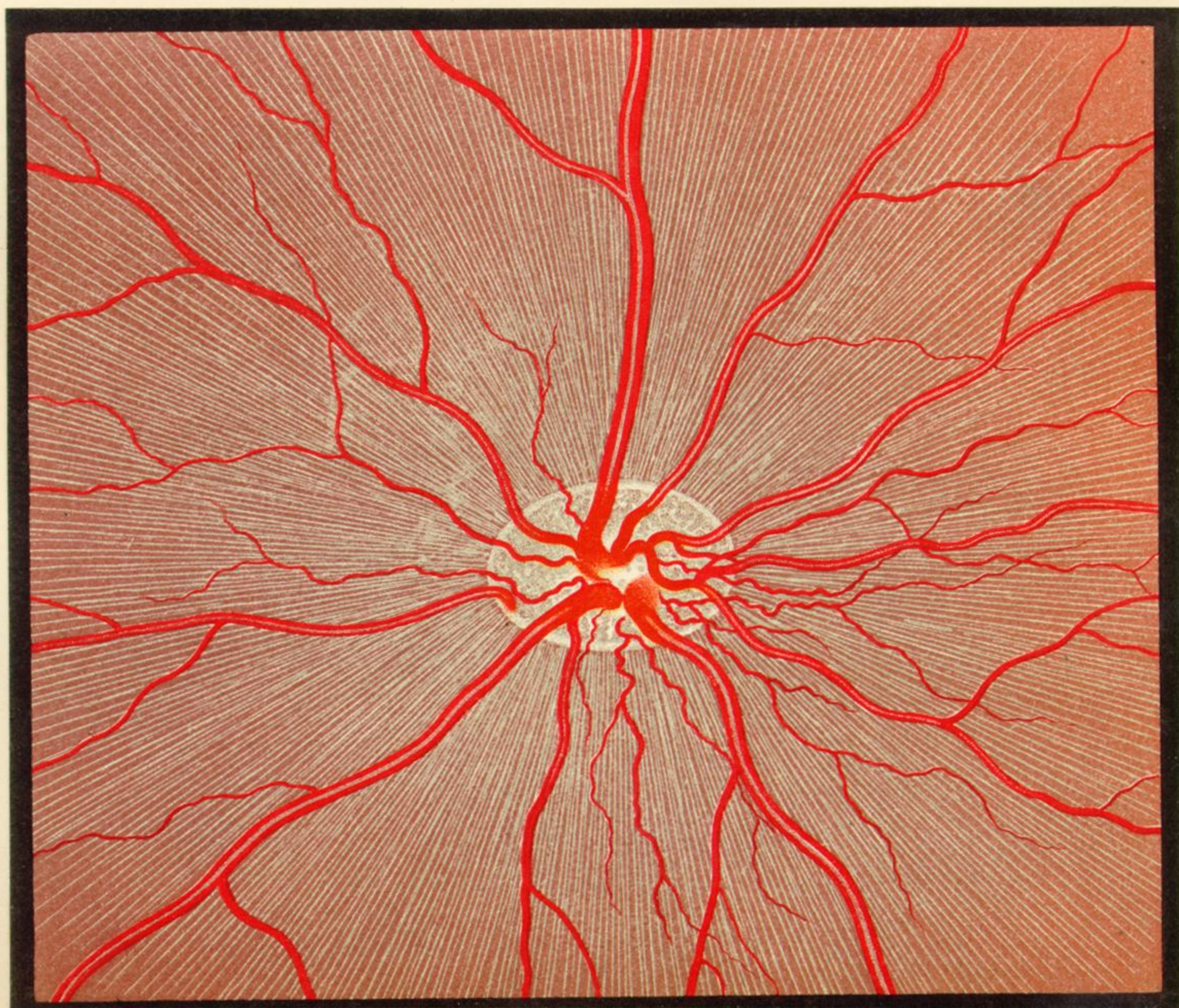
T. JAVANICUS.

CHEVROTAIN.

SUS.

b. BUNODONTA.

SUIDAE.



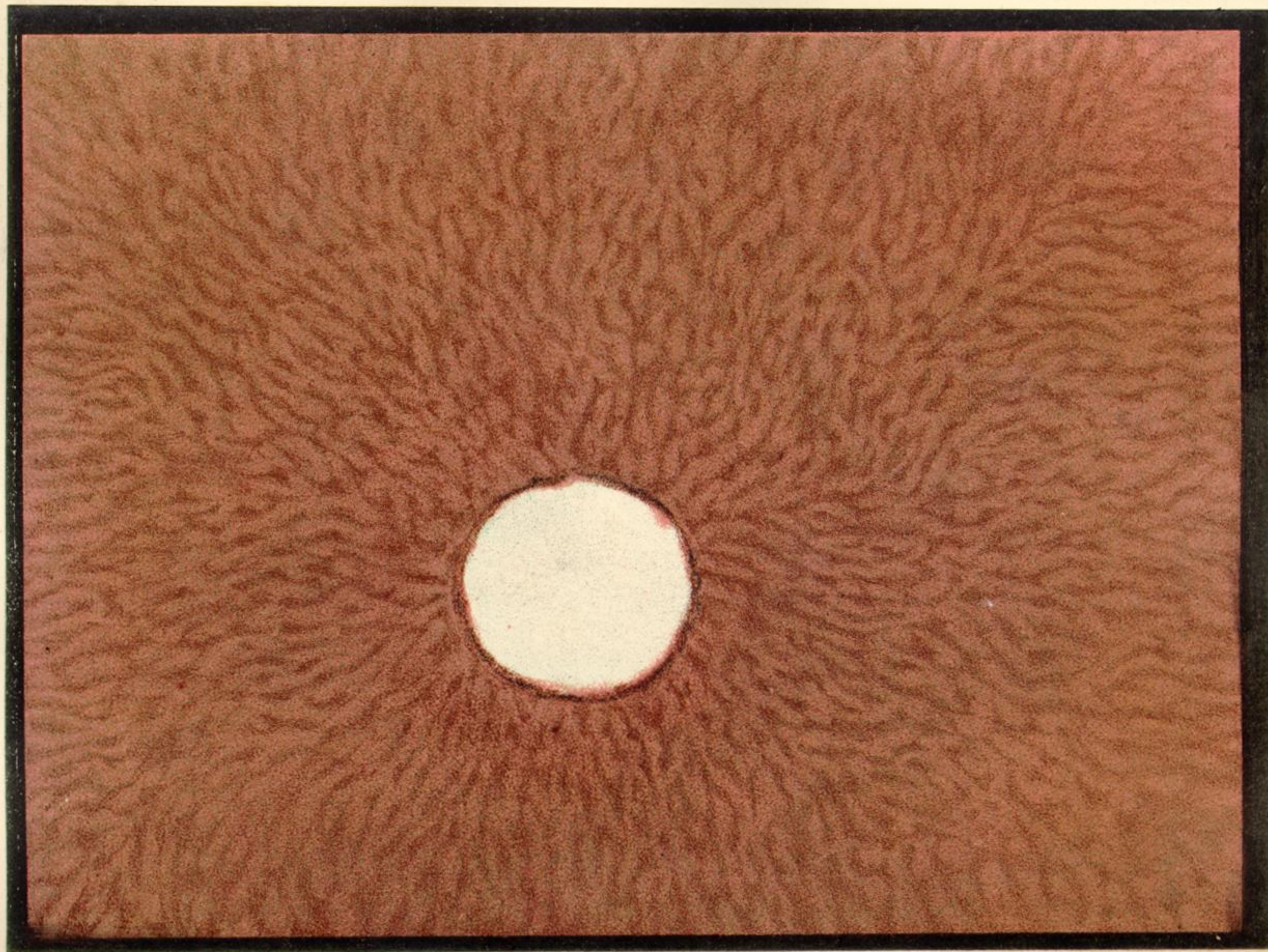
S. SCROFA.

WILD BOAR.

PLATE 14.


1. Fundus oculi of the Java Chevrotain. The surface of the disc is entirely masked with dense moss-like pigment, and is surrounded by a green border. The retinal vessels are so much in front of the choroidal background that they cast distinct shadows on it.

2. Fundus oculi of a Wild Boar. The veins and arteries are of immense calibre, and indistinguishable from one another in colour. The fundus is of a uniform slaty-pink colour without any peripheral zone. Semi-translucent nerve fibres radiate in all directions from the disc. None of the Suidæ possess a tapetum lucidum.



R. UNICORNIS.

INDIAN RHINOCEROS.




Z. BURCHELLI.

BURCHELL'S ZEBRA.

PLATE 15.

1. Fundus oculi of the Indian Rhinoceros. The fundus is mottled and of a uniform brown colour. The disc is chalky-white. No retinal or choroidal vessels are visible anywhere. It is a type of a very primitive fundus.

2. Fundus oculi of BURCHELL'S Zebra. The size and appearance of the disc and the retinal vessels are identical with those in the horse, but the sensitive area of vision is different, consisting of a coarse golden network, the spaces being filled up with pale green. The peripheral area is dense, mottled with light and dark patches of purple.




T. AMERICANUS.

AMERICAN TAPIR.

C. PROBOSCIDEA.
ELEPHAS.

ELEPHANTIDAE.



E. AFRICANUS.


AFRICAN ELEPHANT

PLATE 16.

1. Fundus oculi of the American Tapir. Besides the Elephant this is the only Ungulate which possesses a yellow or golden fundus. The peripheral zone is reddish-orange. The disc is white, and the retinal vessels are reduced to a few capillaries which extend across the disc.

2. Fundus oculi of the African Elephant. The fundus is of a uniform pale straw-yellow colour, and covered with an immense number of peculiar irregular or bent brownish rod-like patches. The disc is large, circular, and grey, like a grey atrophied disc in man. The retinal vessels are limited to six or seven minute vessels, which spread a short way beyond the margin of the disc. There is no peripheral zone.

HYRAX.



H. DORSALIS.

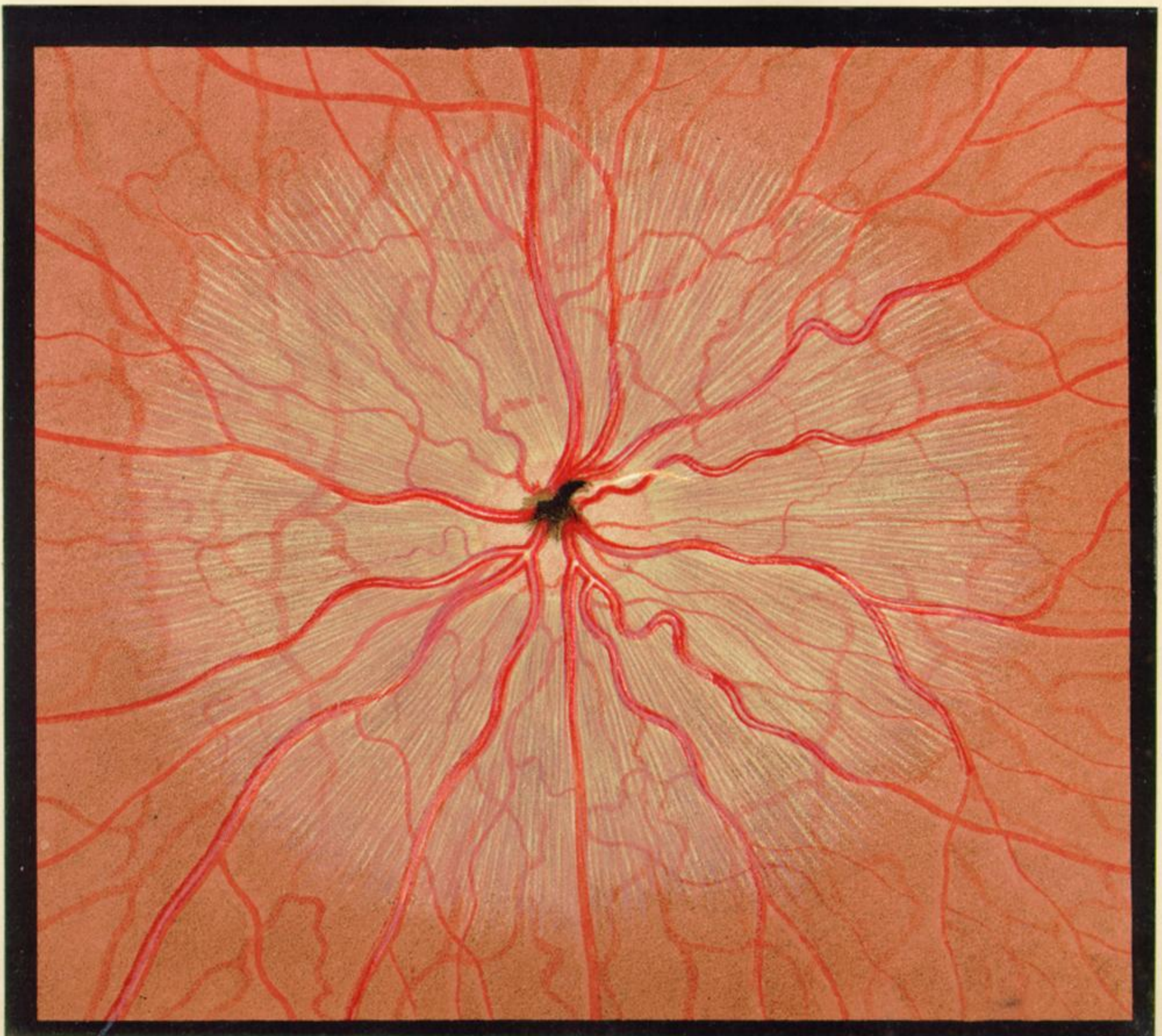
DORSAL HYRAX.

VIII. RODENTIA.

A. MYOMORPHA.

1. DIPODIDAE.

ALACTAYA.



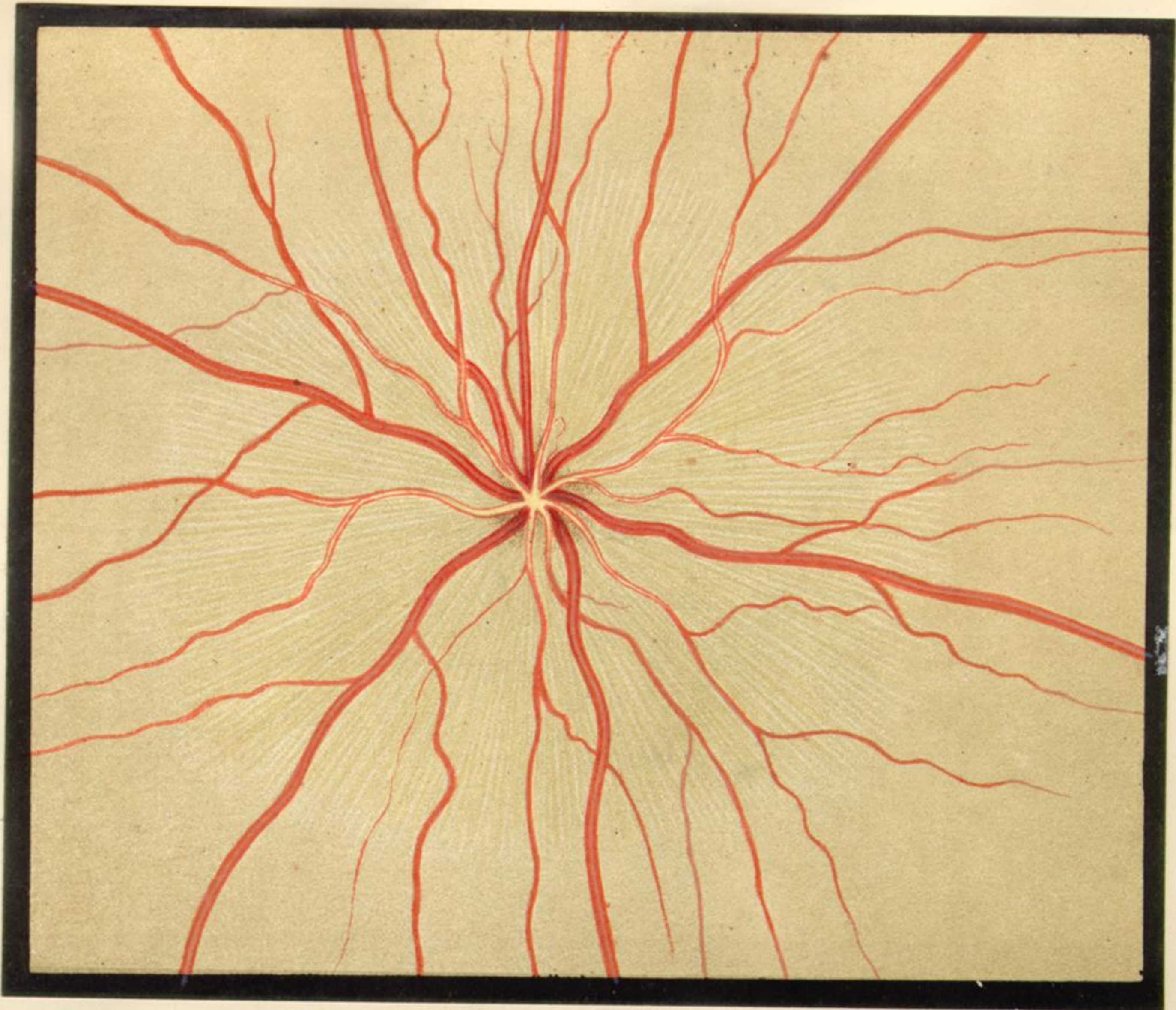
A. INDICA.

INDIAN ALACTAYA.

PLATE 17.

1. Fundus of the Dorsal Hyrax. Although the colour of the fundus is different from that of the Elephant, nevertheless it presents many points of resemblance. Both have a uniform background without any peripheral zone, covered with peculiarly shaped patches. Both have a circular grey disc, and a very primitive vascular supply.

2. Fundus oculi of the Indian Alactaya. The vascular supply, as in most of the higher Rodents, is very complete. The translucent nerve fibres are conspicuous, and the disc imperfectly defined. From its centre is a pigmented body, which projects into the vitreous, and from its summit a white fibrous cord passes to the lens.

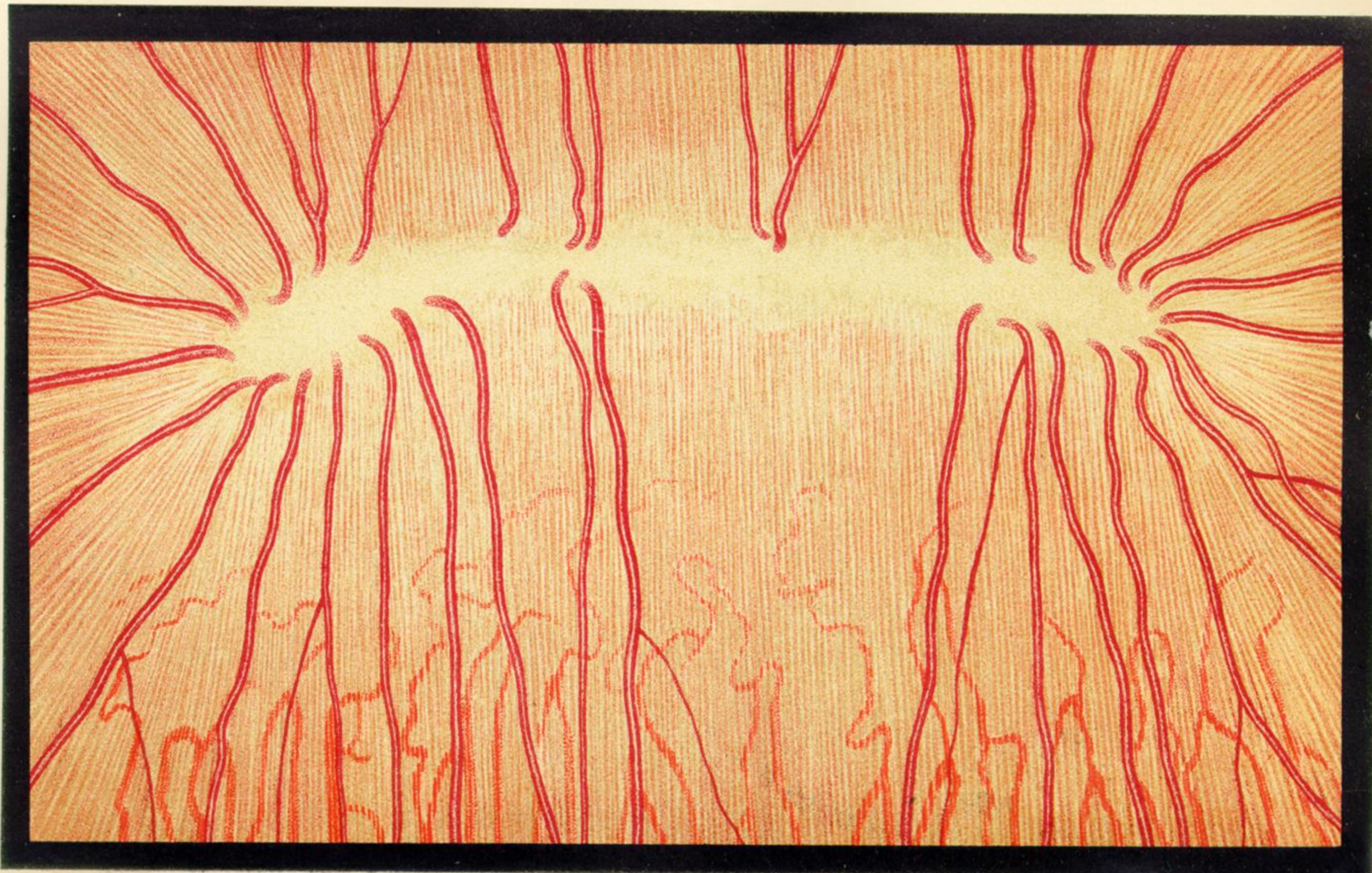

M. RATTUS.

BRITISH BLACK RAT.

B. SCIUROMORPHA.
SCIURUS.

SCIURIDAE.



S. VULGARIS.

COMMON SQUIRREL

PLATE 18.


1. Fundus oculi of the British Black Rat. The fundus is uniformly grey in colour. The veins are much larger than the arteries, and both radiate from the centre of the disc like the arms of a Starfish. The main arterial trunks alternate with the veins.

2. Fundus oculi of the Common Squirrel. The disc is of an enormous size for so small an eye. This is, with few exceptions, the case in all the Squirrels. It is placed well above the axis of vision. The retinal vessels are bright scarlet, and remarkable for their size and number, and there is no distinction between arteries and veins.

B. SCIUROMORPHA.

SCIURIDAE

PTEROMYS.



P. ALBORUFUS.

RED & WHITE FLYING SQUIRREL.

PLATE 19.

Fundus of the Red and White Flying Squirrel. The central area is of a brilliant golden-yellow, covered over with stellate dots. The circular and radiform distribution of the vessels found in the Flying Squirrels and the Palm Squirrel distinguishes them from the other Squirrels and Marmots.




C. CANADENSIS.

CANADIAN BEAVER.

C. HYSTRICOMORPHA.
CHINCHILLA.

1. CHINCHILLIDAE.




C. LANIGERA.

CHINCHILLA.

PLATE 20.

1. Fundus oculi of the Canadian Beaver.
2. Fundus oculi of the Chinchilla. The fundus in each of these animals is almost identical, except that the former has a peculiar conical prominence projecting from the centre of the disc (see Plate 28).

CAVIA.



C. PORCINUS.

COMMON GUINEA PIG.

DASYPROCTA.

4. DASYPROCTIDAE.



D. ISTHMICA

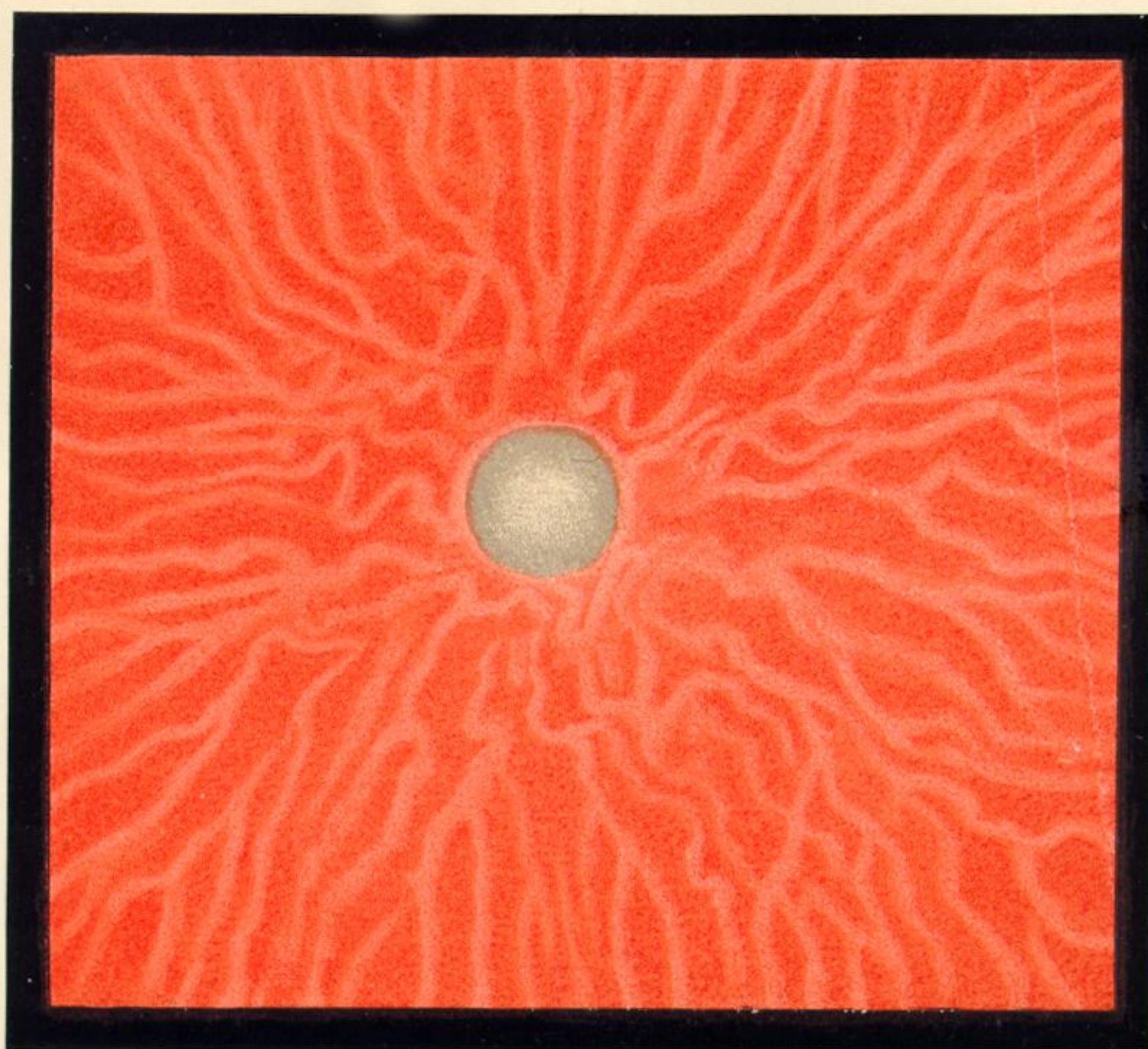
CENTRAL AMERICAN AGOUTI.

PLATE 21.

1. Fundus oculi of the Guinea-pig. The choroid is covered with a peculiar concentric mottling. The disc is white, irregular in outline, and has also a central conical protuberance. (See Plate 20, fig. 1, and Plate 28.)

2. Fundus oculi of the Central American Agouti. The disc is remarkable, as a vascular and pigmented "pecten" is seen protruding into the vitreous from its centre. A similar pecten, though varying in detail, was seen in all the species of Agouti examined.

SPHINGURUS.



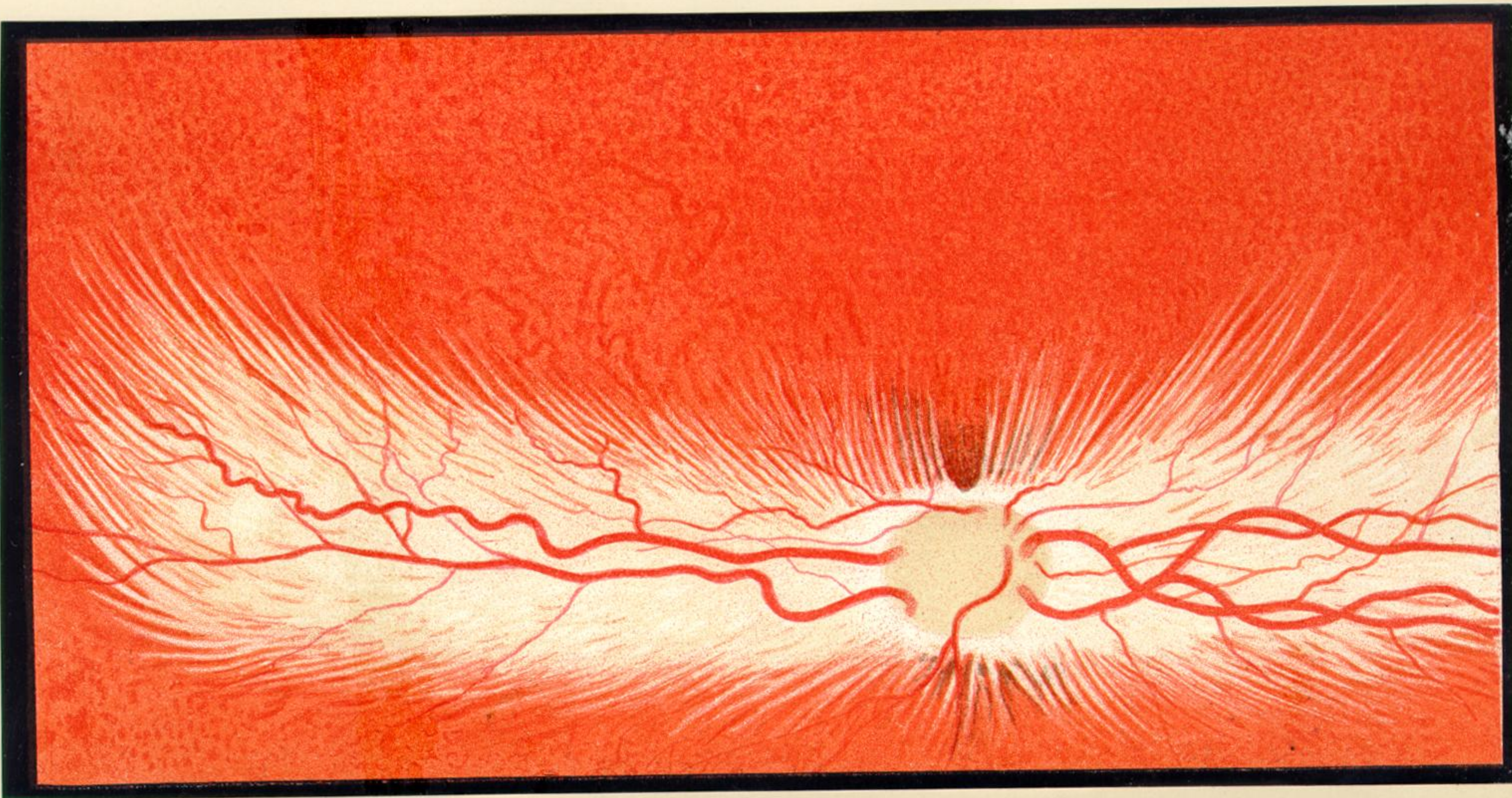
S. PREHENSILIS.

BRAZILIAN PORCUPINE.

D. LAGOMORPHA.

LEPORIDAE.

LEPUS.



L. CUNICULUS.


COMMON RABBIT.

PLATE 22.

1. Fundus oculi of the Brazilian Porcupine. The fundus is most primitive, as is found the case in most animals which are specially protected from injury by nature. No peripheral area, and no trace of retinal vessels, exist. (Cf. Plate 15, fig. 1, and Plate 23, fig. 1.)

2. Fundus oculi of the common Silver-grey Rabbit. The disc together with its dense brush-like opaque nerve fibres are placed well above the area of best vision, which lies in a horizontal plane intersecting the optic axis. The retinal vessels also lie out of the way of vision, being placed in the centre of the nerve fibre bundles.

DASYPUS.



D. VILLOSUS.

HAIRY ARMADILLO.

X. MARSUPIALIA.

A. DIPROTODONTIA.

1. PHASCOLOMYIDAE.

PHASCOLOMYS.



P. WOMBAT.

WOMBAT.

PLATE 23.

1. Fundus oculi of the Hairy Armadillo. A very primitive disc closely resembling that of the Porcupine.

2. Fundus oculi of the Wombat. The chocolate background is covered with interrupted varicose choroidal vessels. The disc is pinkish-white, and covered with a capillary network of vessels proceeding from the central artery of the retina. No other retinal vessels are present.

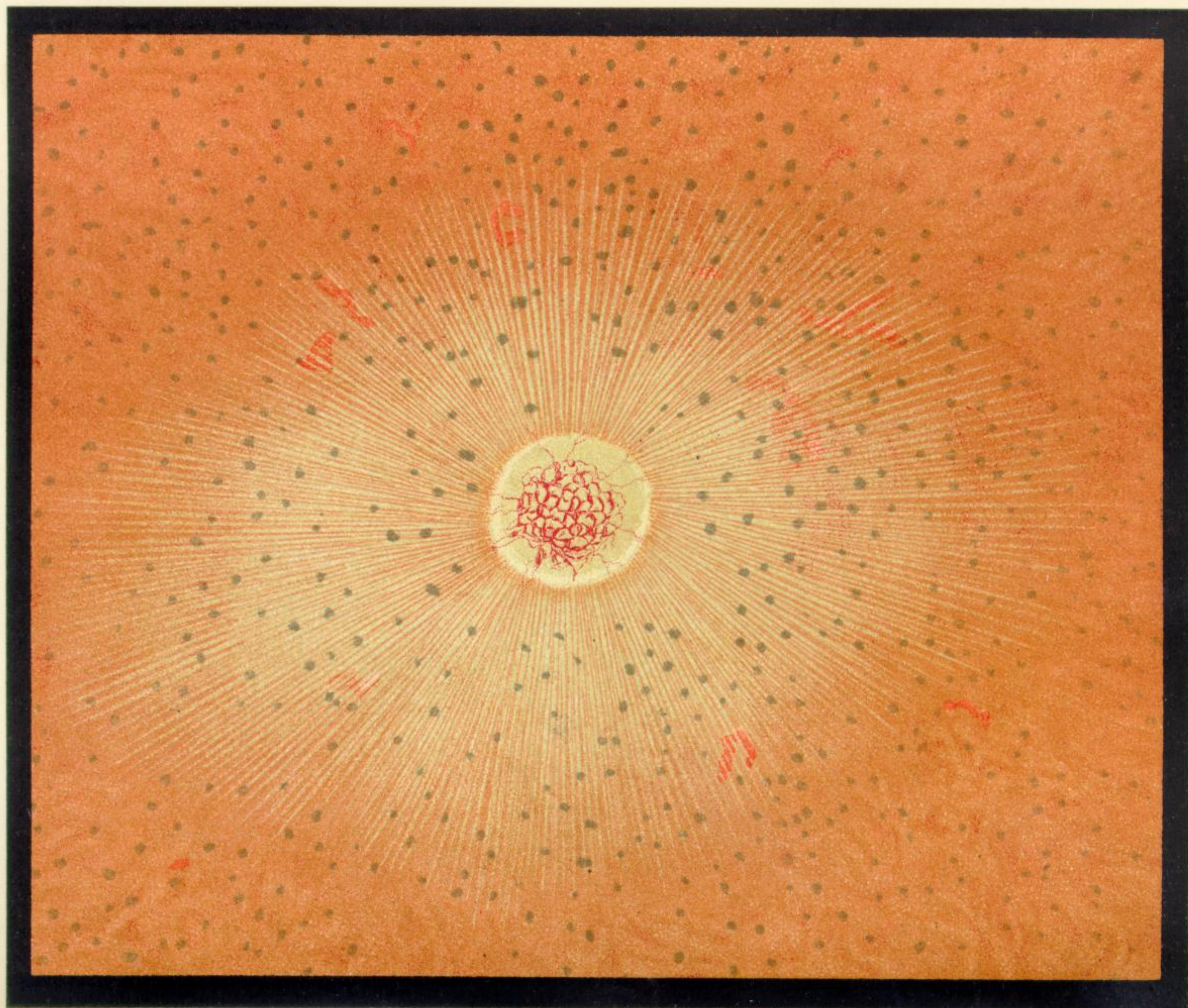


H. RUFESCENS.

RUFOUS RAT KANGAROO.

BELIDEUS.

3. PHALANGISTIDAE



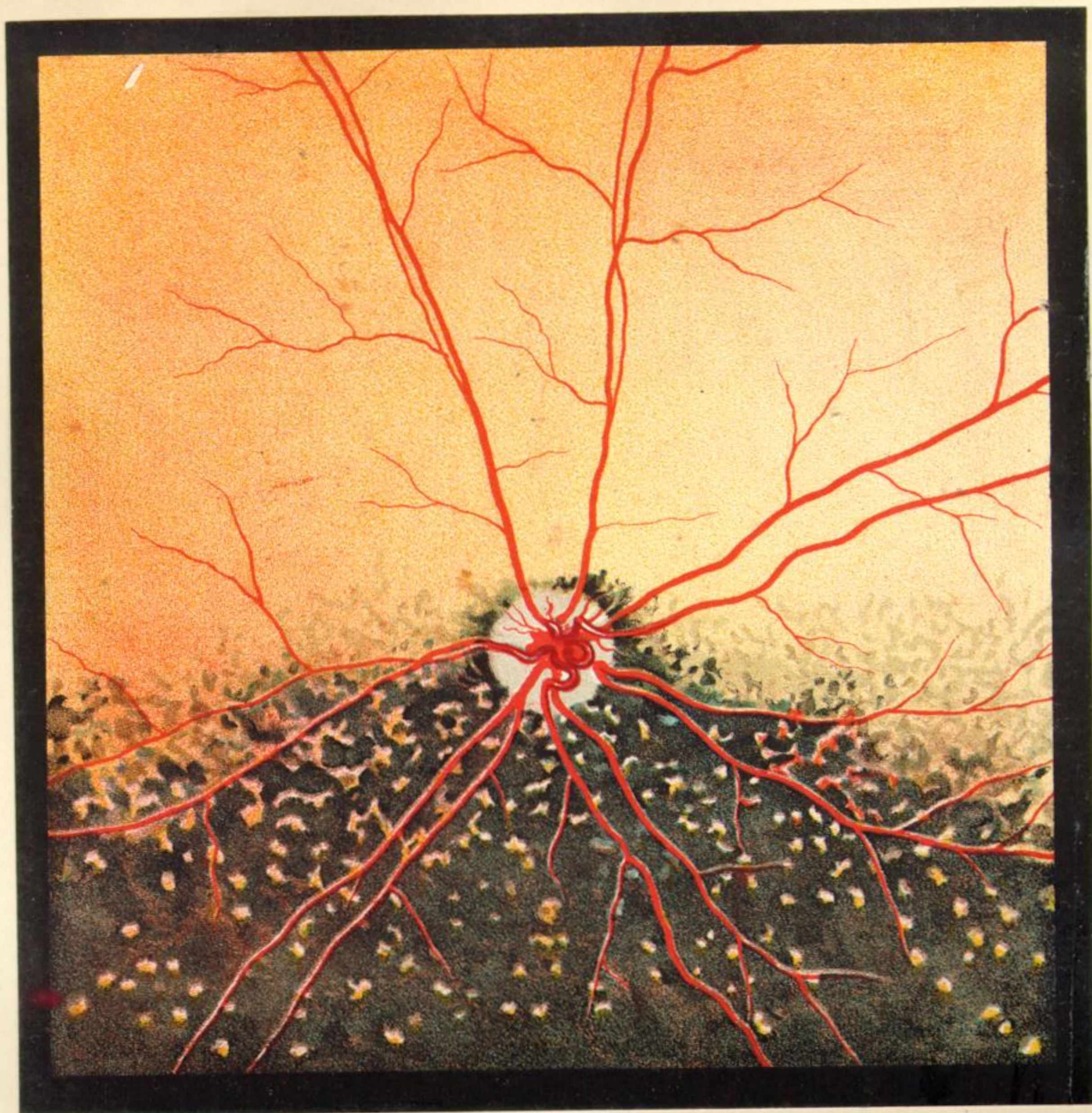
B. SCIURUS.

SQUIRREL-LIKE PHALANGER.

PLATE 24.

1. Fundus oculi of the Rufous Rat-kangaroo. The stroma of the choroid is of a mottled brown colour, covered everywhere with radiating choroidal vessels of uniform calibre, which anastomose in festoon-like fibres around the disc. The disc is yellowish-white in colour, and a peculiar basket-like vascular prominence derived from the arteria centralis passes into the vitreous. (See Plate 26, fig. 1.)

2. Fundus oculi of the Squirrel-like Phalanger. The fundus is reddish-orange, covered with a mottling of red patches; the disc is yellowish-white, partly obscured by a capillary network of vessels. There is no peripheral zone.

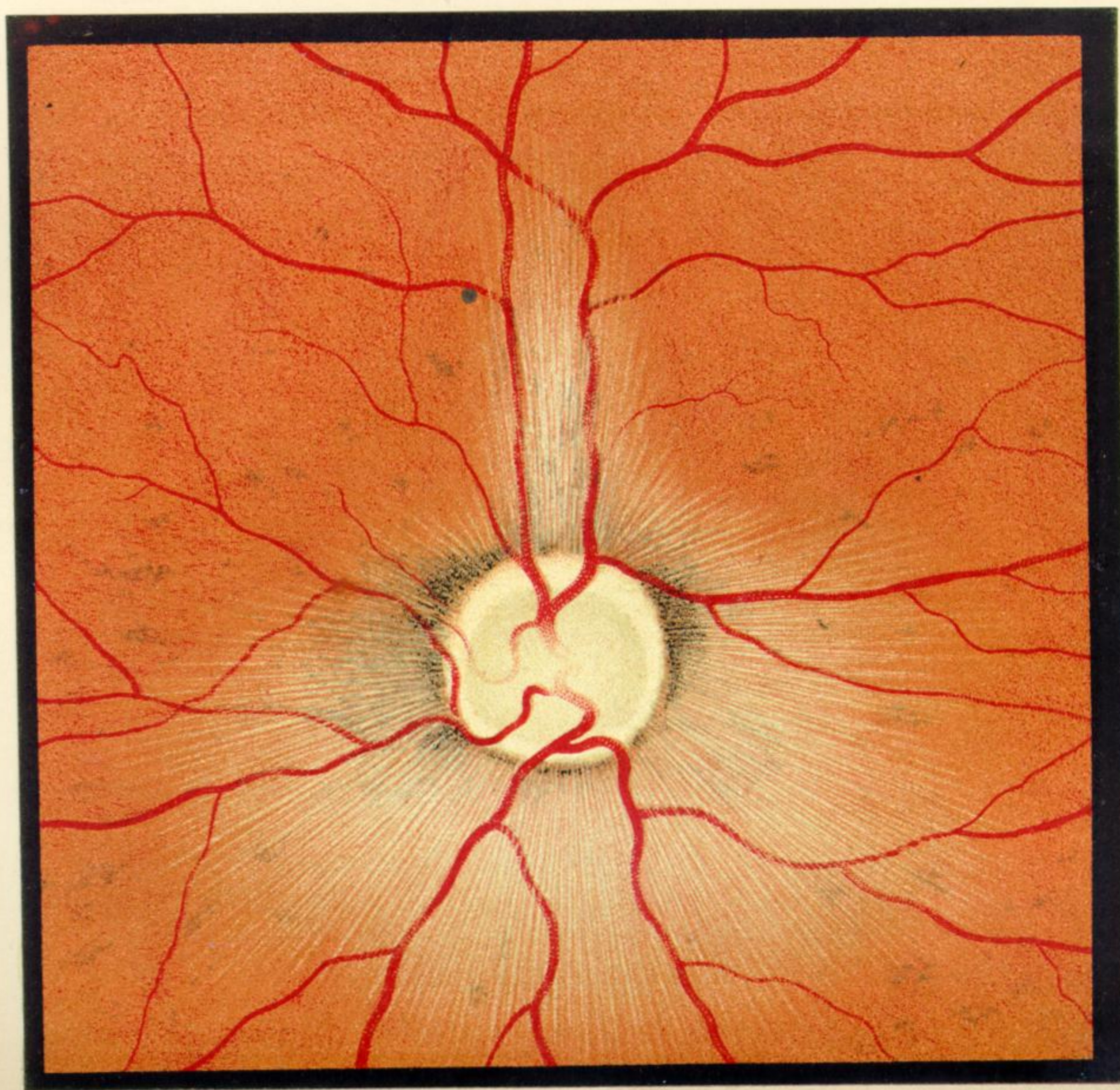


D. VIRGINIANA.

VIRGINIAN OPOSSUM.

DASYURUS.

2. DASYURIDAE.



D. URSINUS.

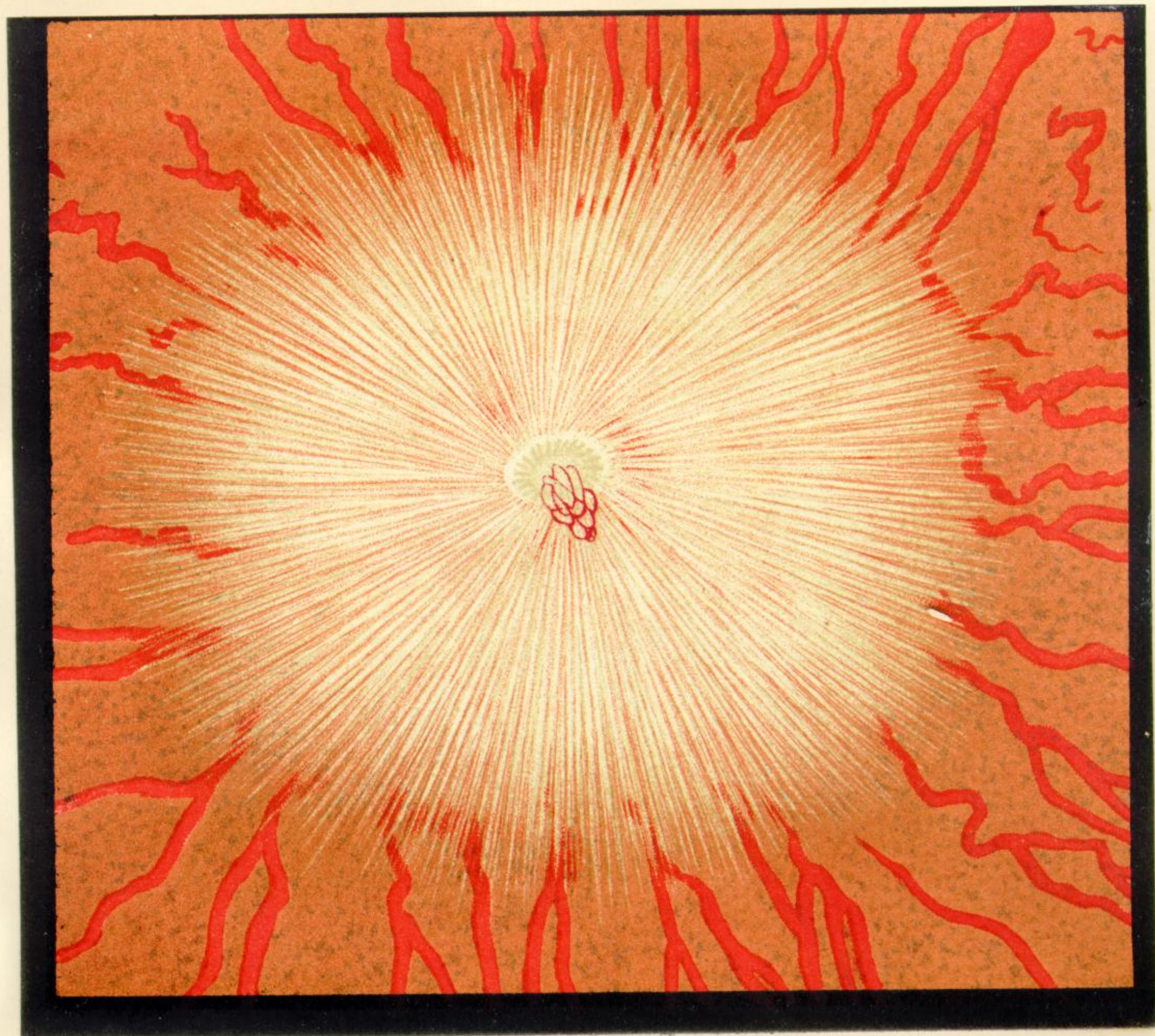
TASMANIAN DEVIL.

PLATE 25.

1. Fundus oculi of the Virginia Opossum. It is remarkable for possessing a golden central zone, which is surrounded by a peripheral zone densely pigmented. It also possesses a grey disc and well-developed retinal vessels.

2. Fundus oculi of the Tasmanian Devil. The fundus is of a deep Indian red colour faintly mottled with pigment. The disc is greyish-white, and the retinal vessels are numerous and large. Semi-opaque fibres are present, one set accompanying the main ascending trunks for some distance.


PERAMELES.



P. LAGOTIS.

RABBIT-EARED PERAMELES.

XI. MONOTREMATA.



ECHIDNA.

PLATE 26.

1. Fundus oculi of the Rabbit-eared Perameles. The arrangement of the nerve fibres is exceedingly curious, resembling a white aster. The fibres are not semi-transparent as in most animals, but semi-opaque; although not to such a degree as in the case of the Rabbit and Hare. The arteria centralis retinae terminates in a basket-like anastomosis of fine vessels, and resembles that seen in the Chameleon, except that the former is destitute of pigment cells or granules.

2. Fundus oculi of the Echidna. The background and the disc resemble that of many of the day-feeding birds, but the disc differs from all birds in being entirely destitute of a pecten. The whole eye is extremely primitive in structure.

Various Types of the obliterated Hyaloid Artery in Man.

Fig. 1

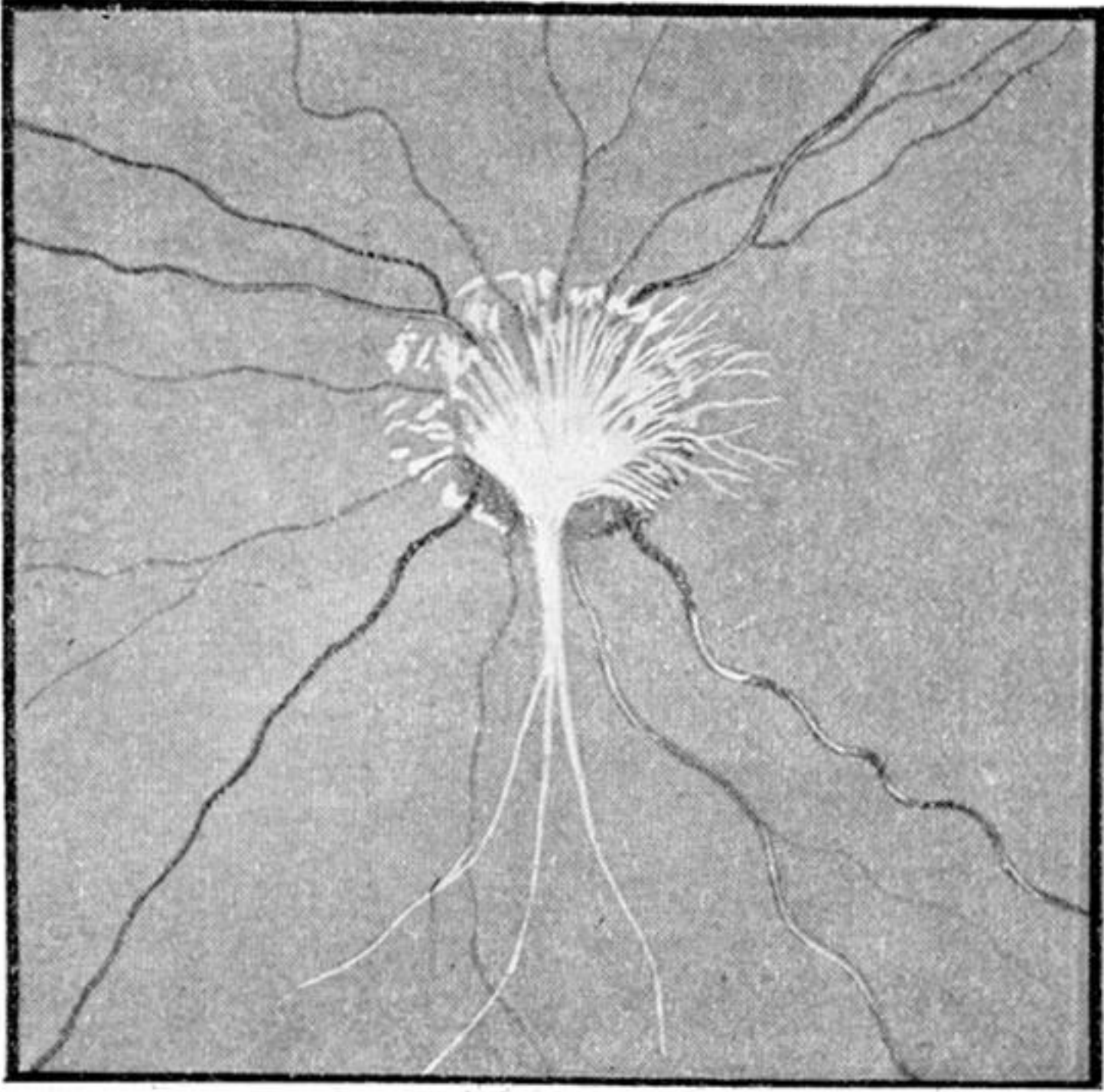


Fig. 2

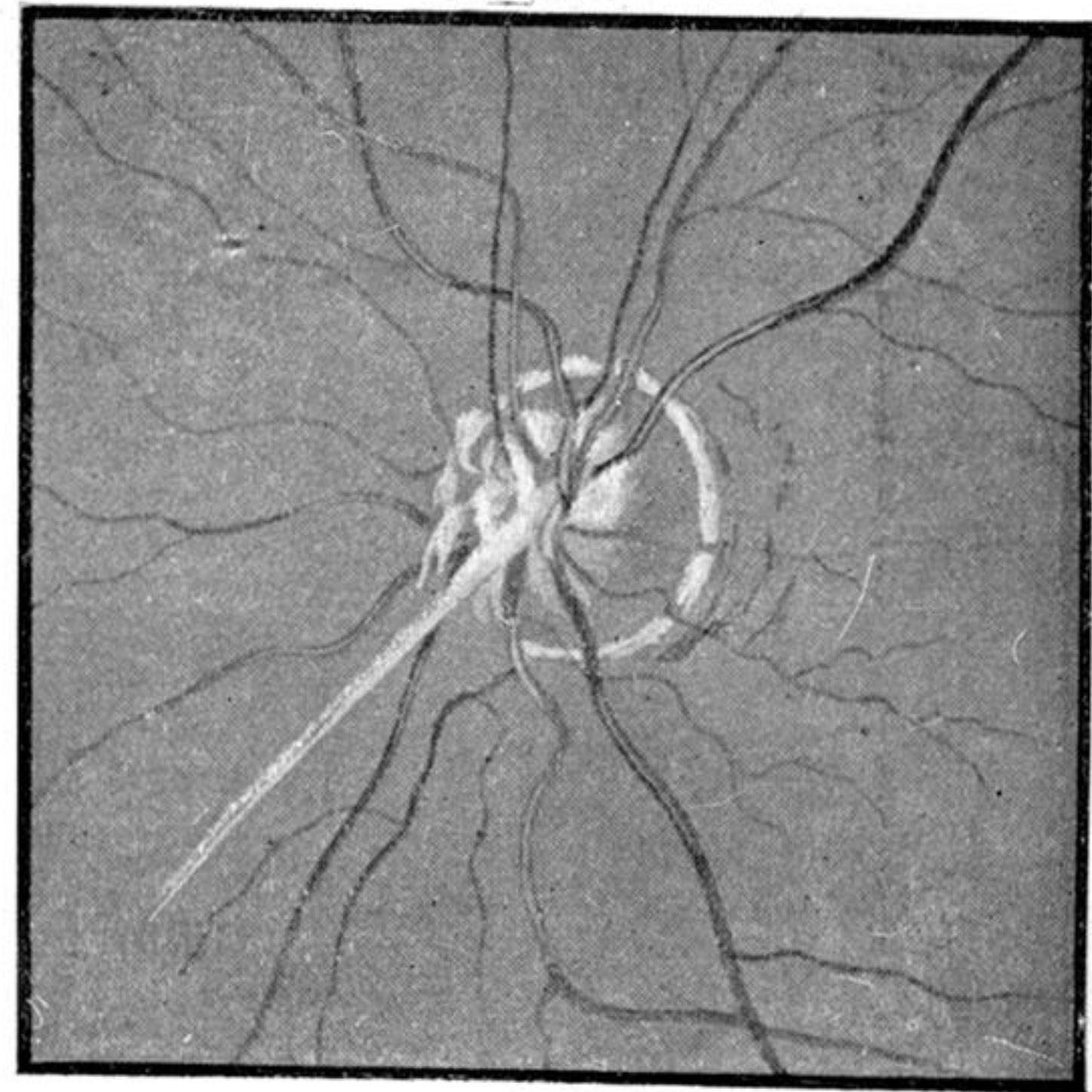


Fig. 3

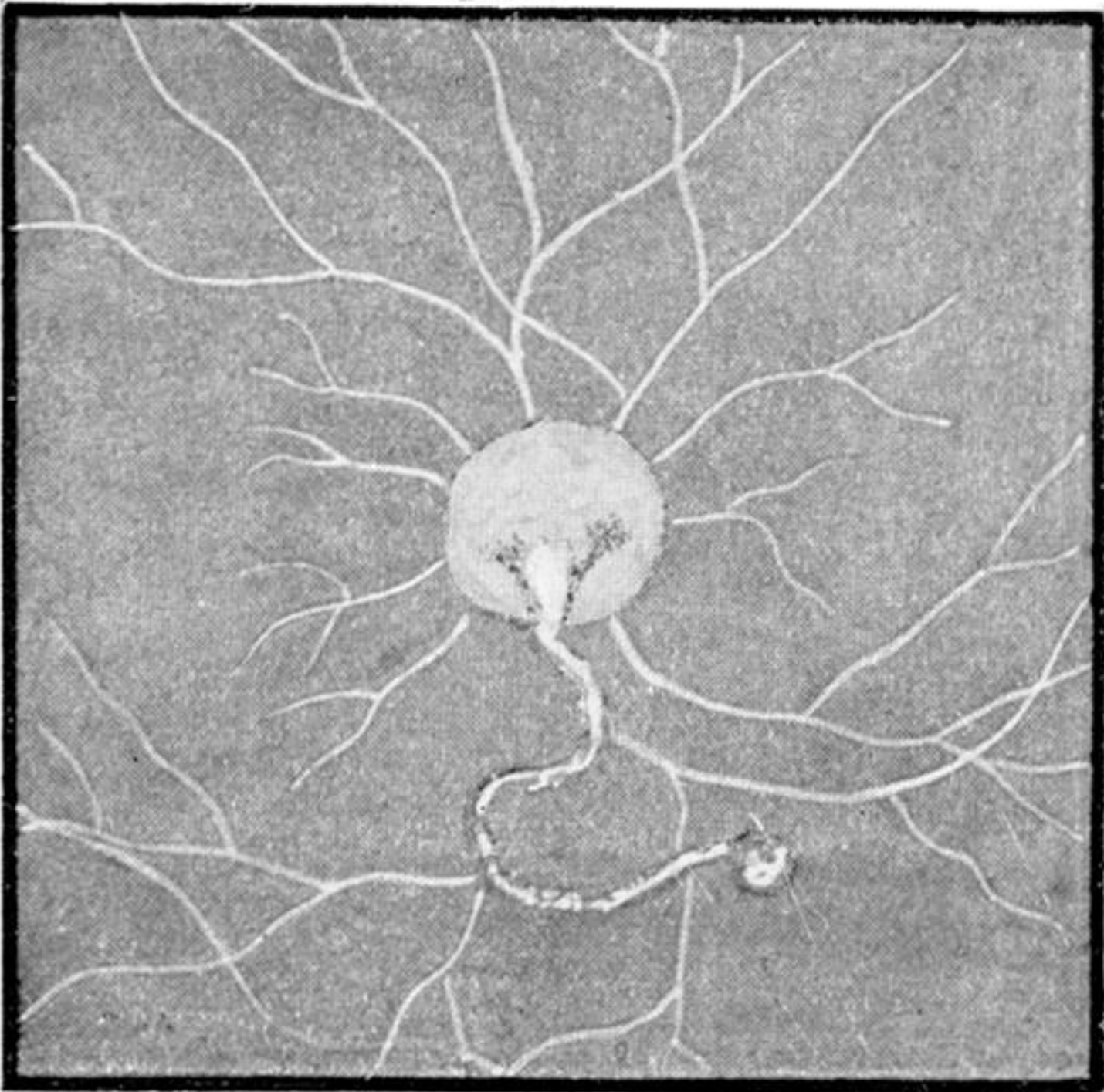


Fig. 4

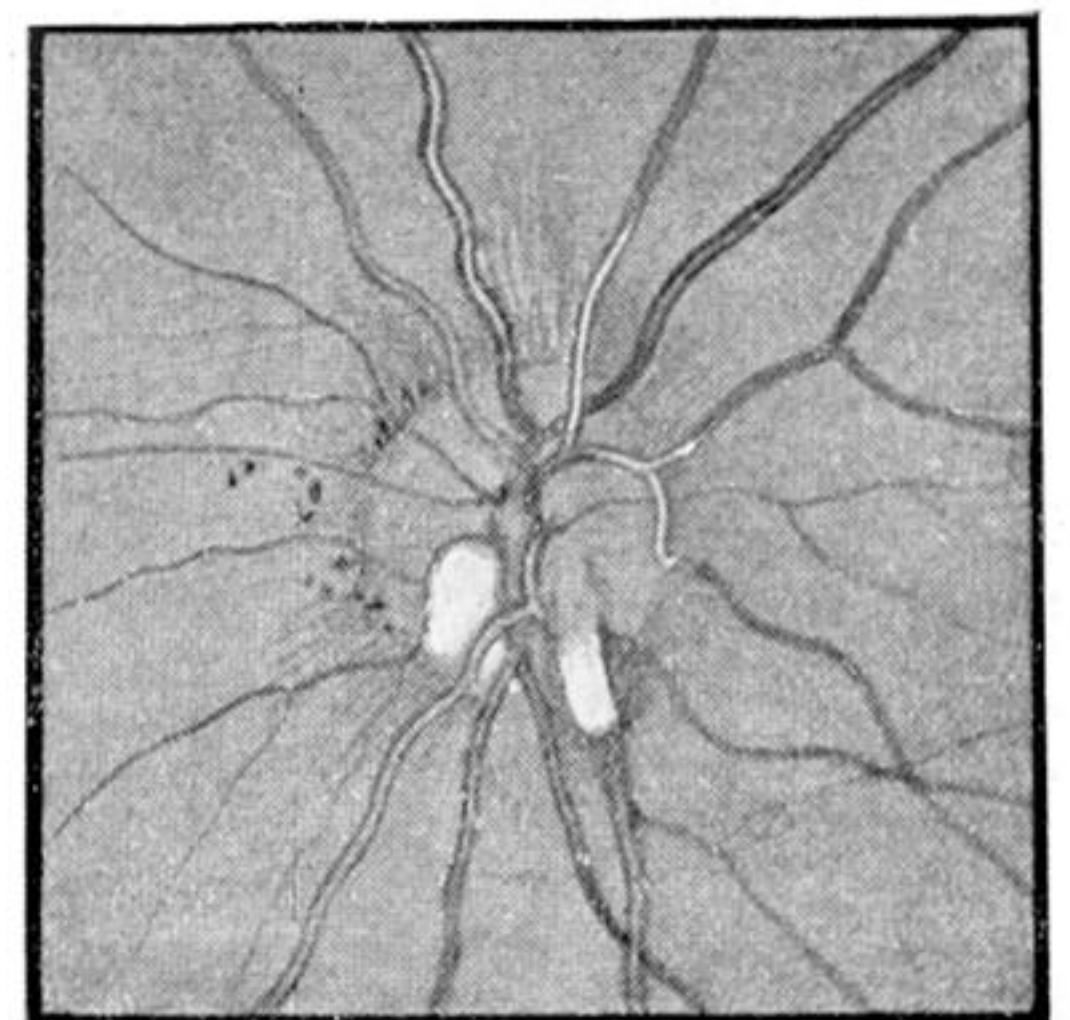


PLATE 27. (See pp. 53-54.)

Four drawings of the human Fundus Oculi to illustrate the three main forms of the persistent Hyaloid Artery.

Fig. 1. The hyaloid artery is seen as a white cord arising by a broad base covering the entire disc and even projecting beyond it in the form of fine fibrous filaments. The distal portion is split up into three cords, which could be seen in contact with the lens capsule. (Drawn from life.) $\times 10$ diam.

Fig. 2. A similar case, arising from the centre of the disc and projecting to the lens as a single cord. (Drawn from life by the author.)

Fig. 3. The hyaloid artery free from blood is seen arising by a hollow trumpet-shaped tube from the disc, the tube passing forwards towards the disc to end in a tiny trumpet-shaped mouth affixed to the lens capsule, and known as the *Campanula Halleri*. In this drawing it is lying free in the vitreous. (Copied from a drawing by SCHÖBL, in NORRIS and OLIVER'S 'System of Diseases of the Eye,' vol. 3, p. 422.)

Fig. 4. The hyaloid artery is in the form of a sausage-shaped coecal vessel arising from the main trunk of the *Arteria centralis retinae*. It was filled with blood, and pulsated with the trunk vessel. Its closed end projected into the vitreous. (Drawn from life by the author.)

Primitive and Retrograde forms of the PECTEN and other vestigial remains occurring in the Mammalia.

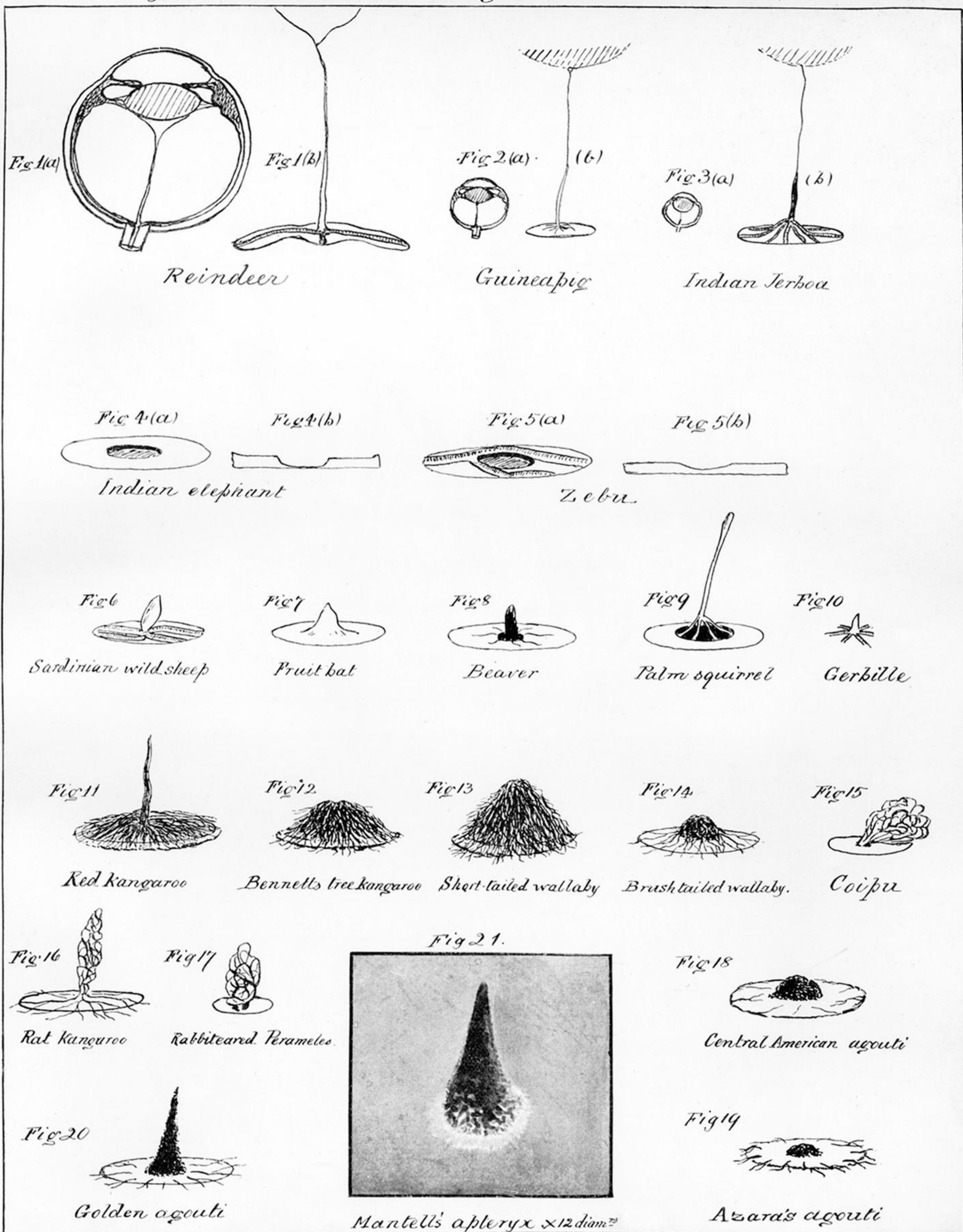


PLATE 28. (See pp. 24 to 54, *passim*.)

Illustrating the primitive and retrograde forms of the Pecten and Hyaloid Artery occurring in the Mammalia.

Fig. 1. The persistent hyaline artery in the Reindeer.

It is found as a white cord reaching from the disc to the lens, to the capsule of which it is attached by one or more fine threads.

Fig. 2. A similar cord seen in many of the Rodents.

In this case it ended in a small button or hollow cone (*Campanula Halleri*).

Fig. 3. The arteries branch out from the main trunk, forming a series of arches above the disc. From the top of this a pigmented process projects into the vitreous, and is continued to the lens as a fine cord (*Jerboa*).

Fig. 4. A circular depression occupying a third of the diameter of the disc. I found it in all the Elephants examined.

Fig. 5. A similar depression, but much shallower; repeatedly found in *Bos*.

Fig. 6. An oat-shaped white process arising from the main trunk and penetrating into the vitreous (*Ovis musimon*).

Fig. 7. A glistening white fibrous process arising from a broad base from the bloodless disc (*Pteropus*).

Fig. 8. A white stunted process of fibrous tissue arising from the base of a pit in the centre of the disc of *Castor*.

Fig. 9. A long stiff fibrous process ending in a club-shaped knob arising from several similar roots attached to the margin of a deep pit (*Sciurus palmarum*).

Fig. 10. A pointed fibrous process arising from the main trunk (*Gerbillus*).

Fig. 11. A deeply pigmented black process penetrating the vitreous and arising from the centre of a slightly-elevated cushion covered by innumerable fine blood vessels which cover the disc (*Macropus rufus*).

This and the remaining illustrations represent various degrees of development of the vestigial pecten.

Figs. 12, 13, and 14. Similar cushions covered with fine vessels.

Fig. 15. A basketwork of vessels arising from a depression in the centre of the disc, and partly covering one side of it (*Coipu*).

Fig. 16. A coarse vascular basketwork arising from the central artery. Numerous arterial twigs ramify over the disc (*Hypsiprymnus rufescens*).

Fig. 17. A similar network (*Perameles lagotis*).

Figs. 18, 19, and 20. Protuberances containing all the elements of a true pecten, viz., large pigment cells, pigment granules, basement membrane, and a network of blood-vessels (*Agouti*).

Fig. 20 shows a pecten formation closely resembling that of the *Apteryx*.

Fig. 21. A true pecten, but without plications (*Apteryx Mantelli*).

Types of the Appendages to the Iris occurring in the Ungulates, illustrating the successive stages from the Corpus nigrum of the Equidæ to the functionally active Umbraculum in the Hyrax.

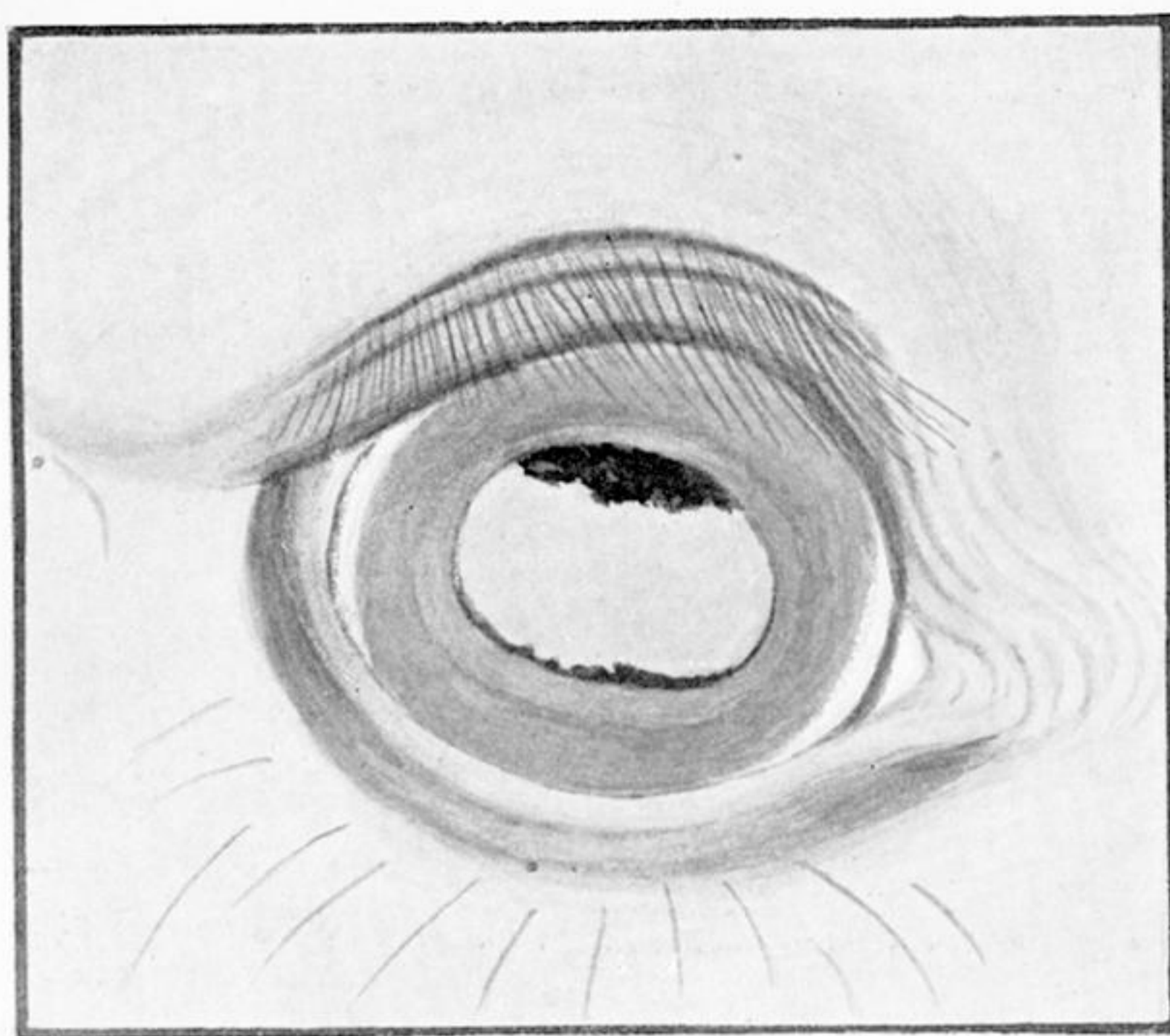


Fig. 1 Horse

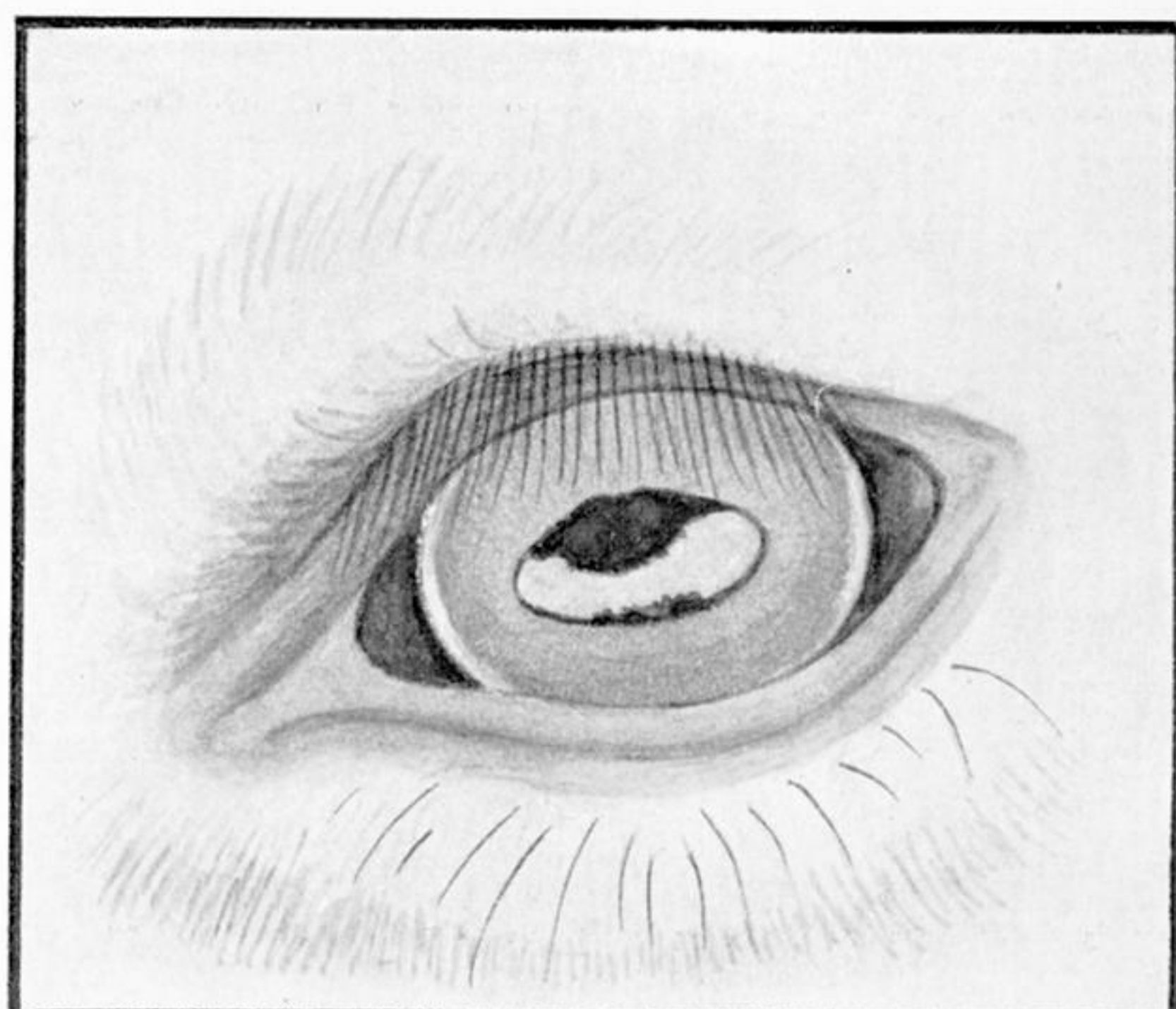


Fig. 2 Wild Ass

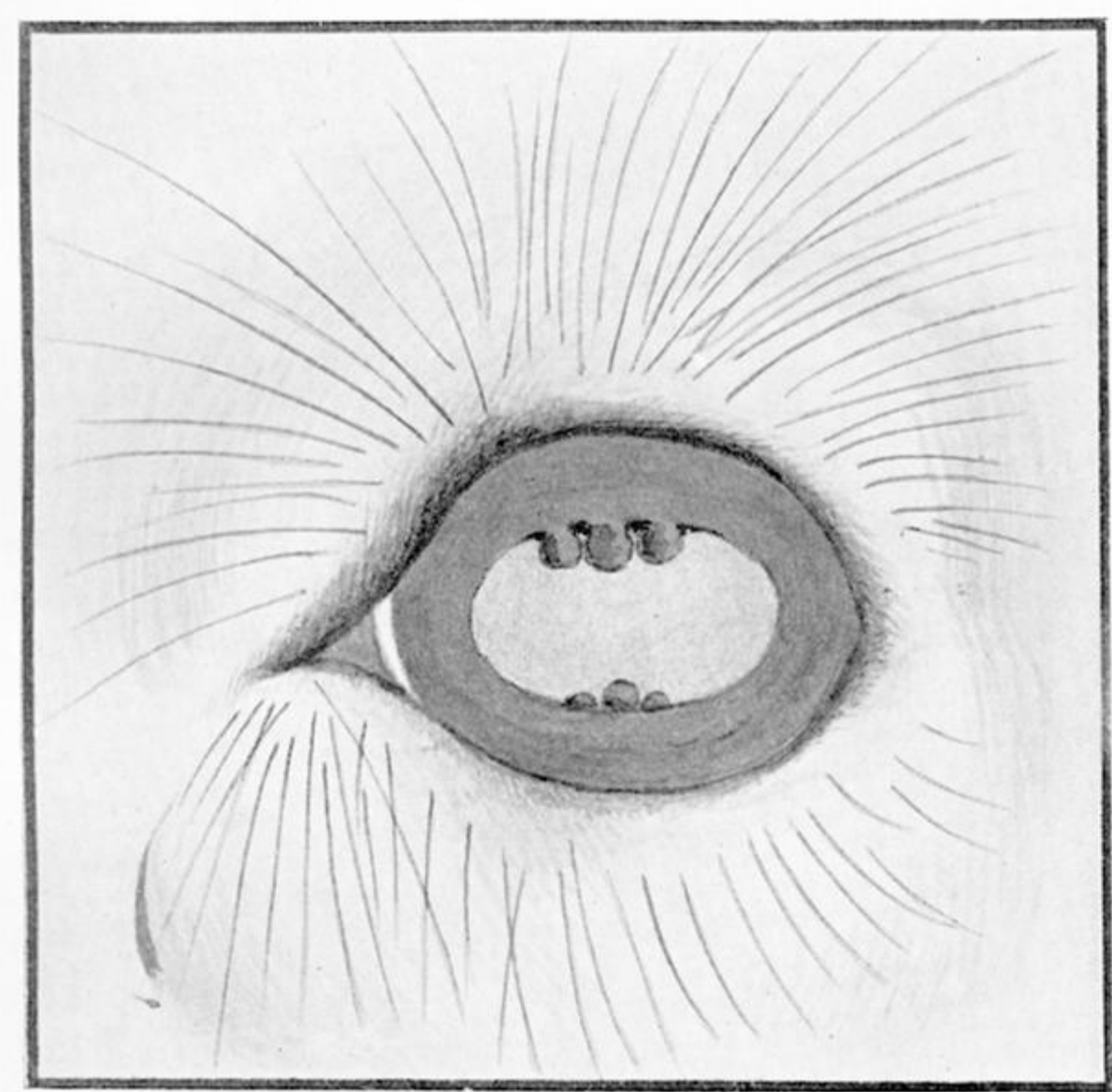
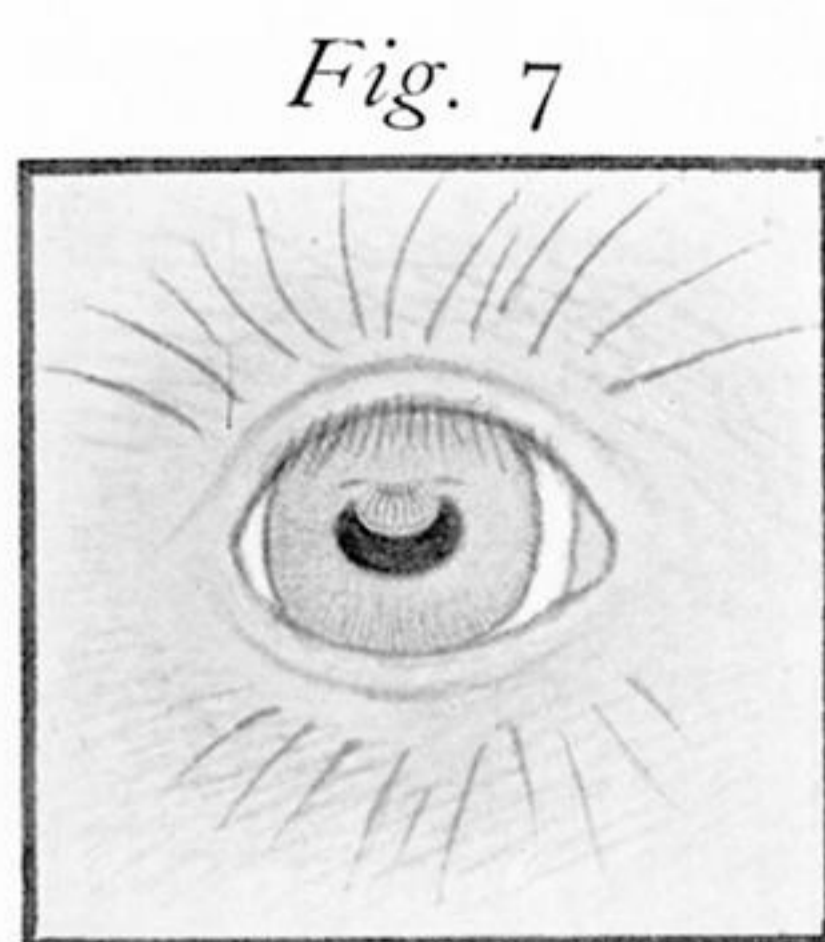
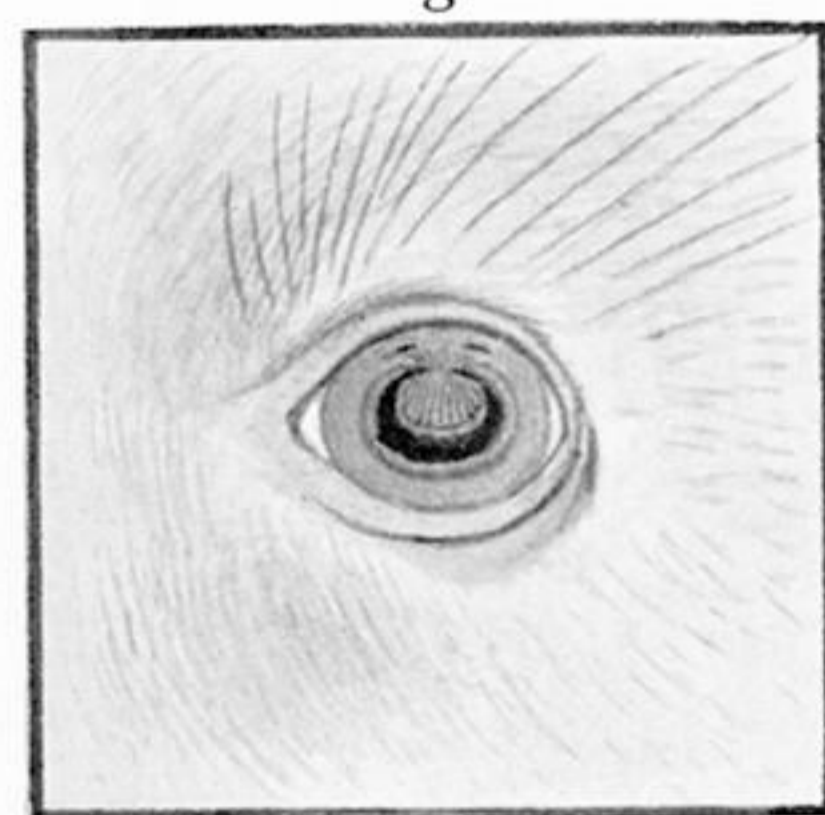


Fig. 3 Dorcas Gazelle



Hyrax Dorsalis



Hyrax Capensis

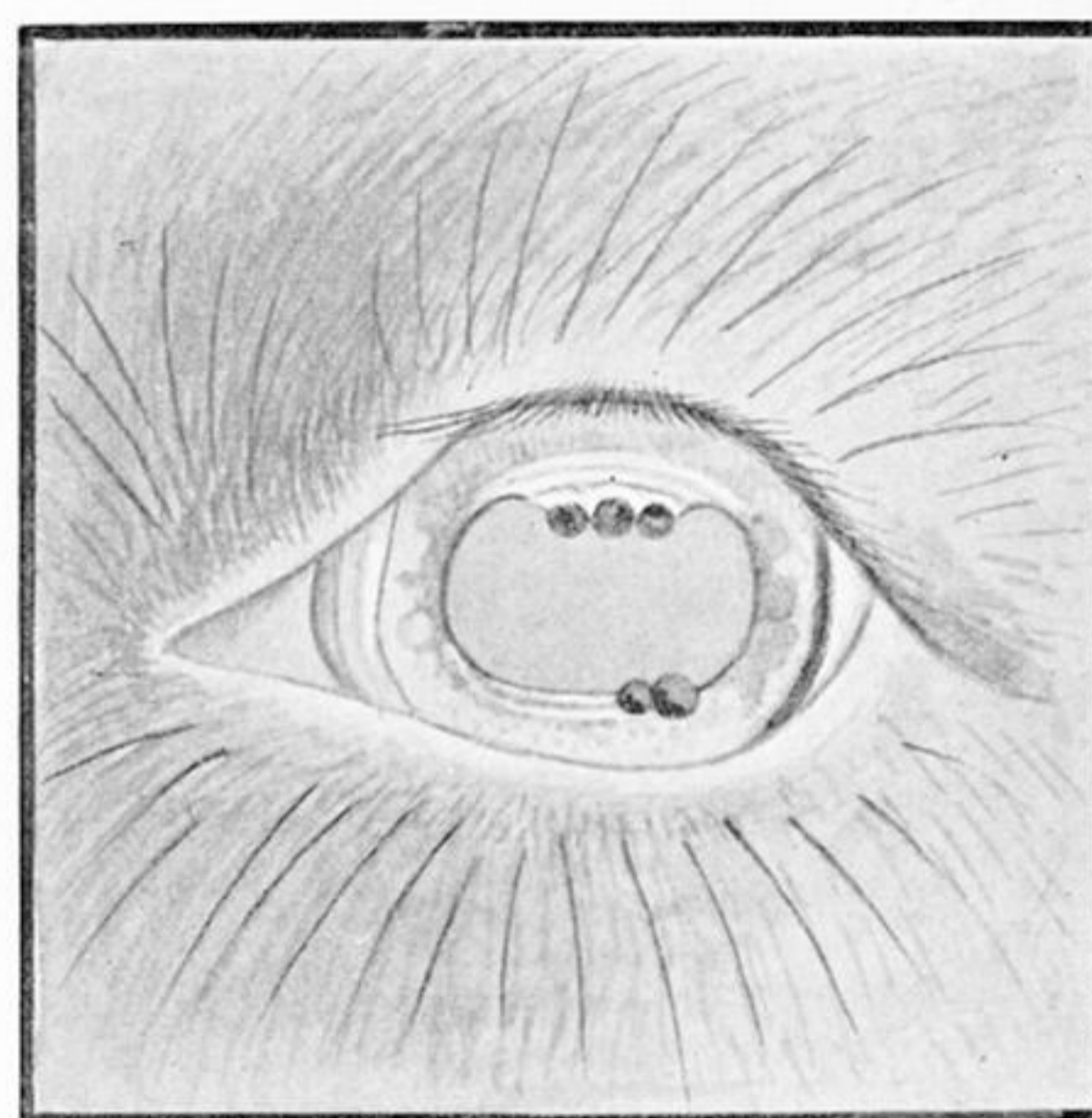


Fig. 4 Goat

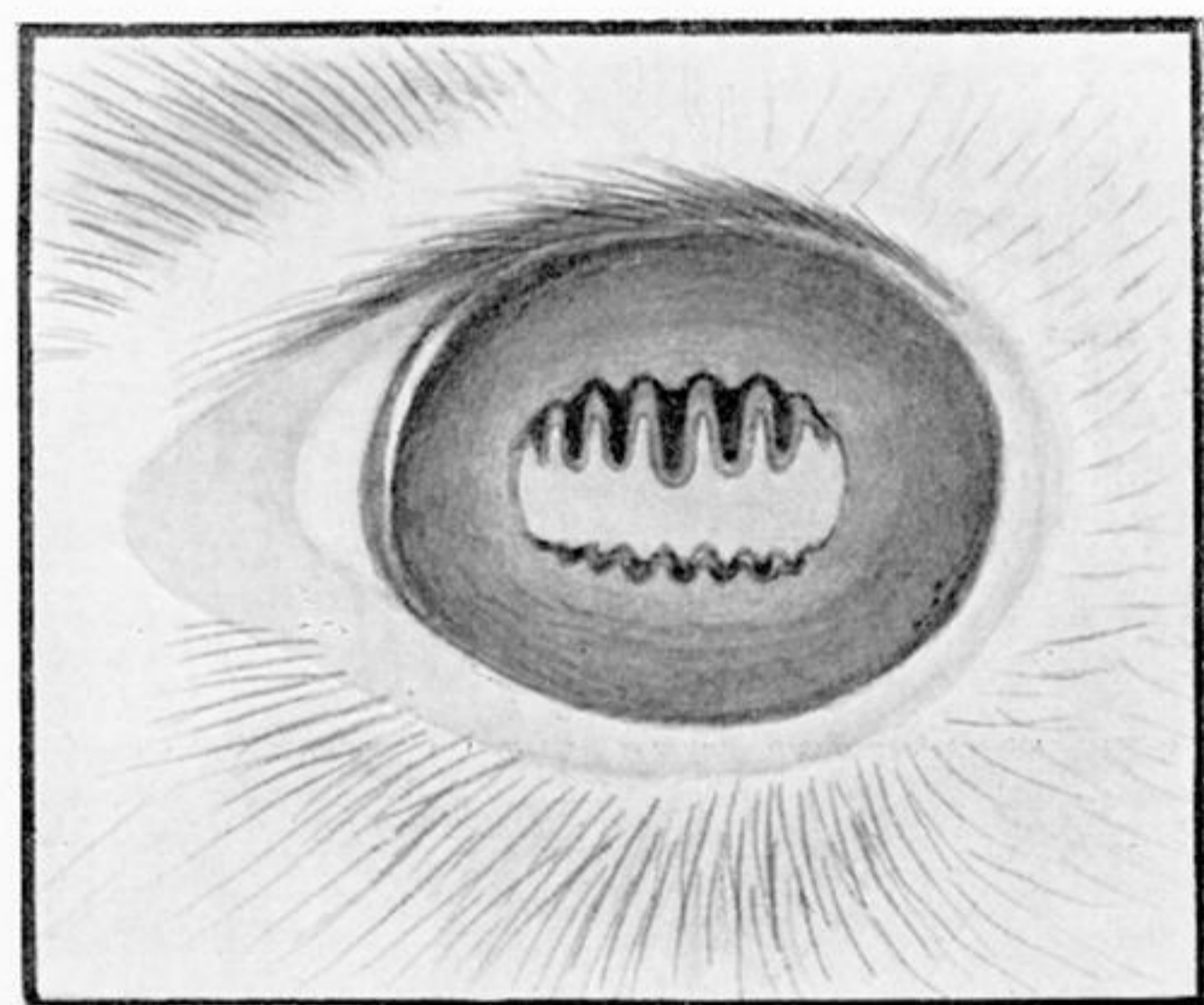


Fig. 5 Camel

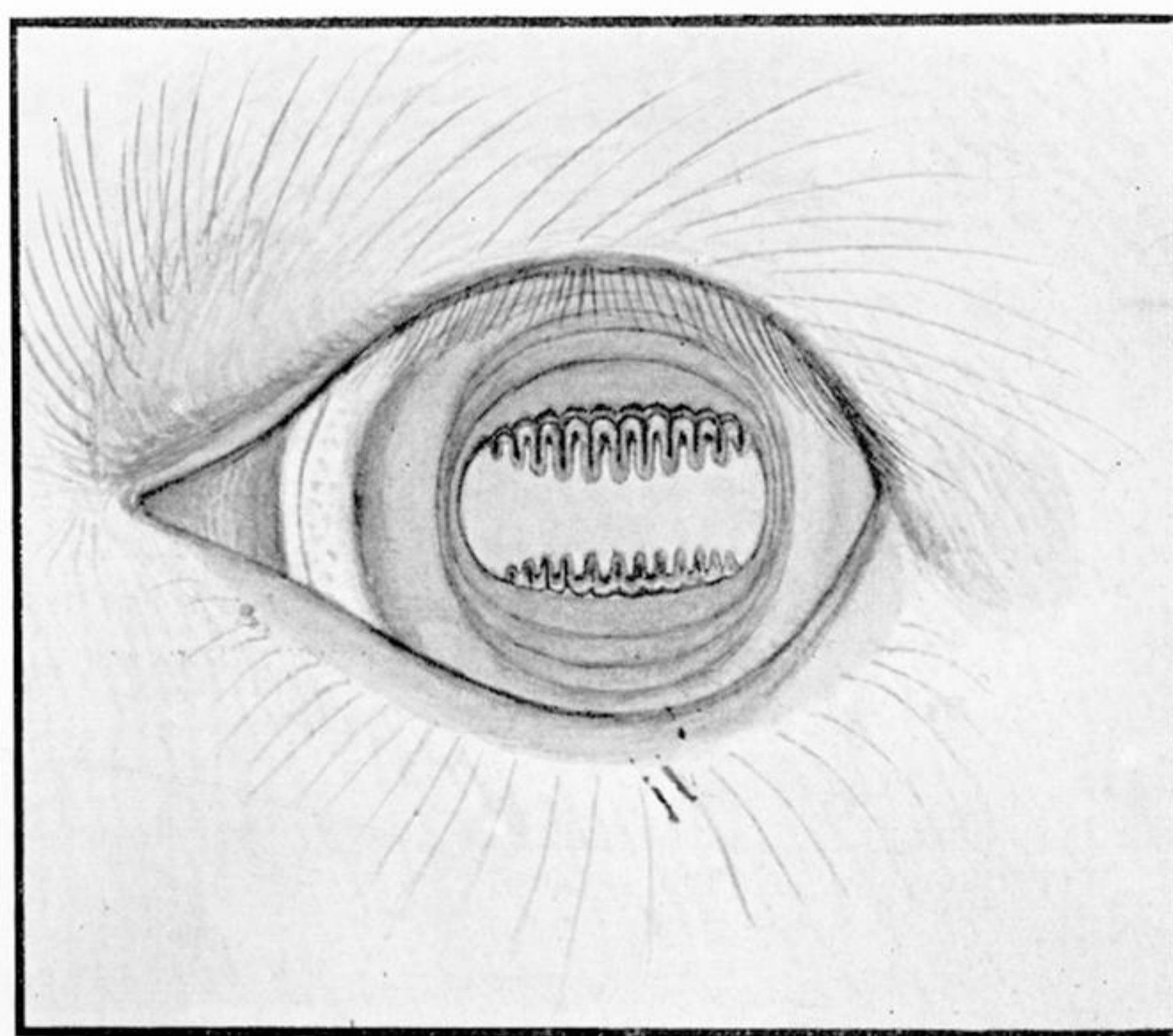


Fig. 6 Llama

Drawn from life. Natural size.

PLATE 29. (See pp. 22, 27, 56-59.)

Types of the Appendages to the Iris occurring in the Ungulates, to illustrate the successive stages from the Corpus nigrum seen in the Equidæ, to the functionally active Umbraculum which exists in the Hyrax.

The drawings are all taken from life, and the natural size.

Fig. 1. The Corpus nigrum. A simple hypertrophy of the under or pigment layer of the iris. It is most developed along the upper edge of the pupil (*Equus caballus*).

Fig. 2. A Corpus nigrum, similar in structure, but much thicker and larger (*Equus tæniopus*).

Fig. 3. Three well-formed symmetrical nodules formed by an outgrowth of both layers of the iris, the pigment being hidden by the upper layer of iris fibres.

Fig. 4. A similar contrivance, only more highly differentiated. The iris itself projects over the pupil, and is beautifully marked with stripes in the Wild Goat (*Capra dorcas*).

Figs. 5 and 6. A further elaboration of the two layers of the iris, forming a series of ridges and hollows, which interlock with the lower set when the pupil is fully contracted (*Camelus*, *Llama*).

Figs. 7 and 8 (Hyrax). The most highly developed of all iritic appendages, forming a highly contractile structure, which I have named the "Umbraculum," since it shields the eye from glare. It arises 2 millims. from the free edge of the iris by numerous elastic (muscular?) fibres, which radiate out like a fan to be inserted into a narrow band of fibres which run round the free margin of the umbraculum. On either side of its origin is a horizontal slit. These vary in size as the umbraculum lengthens or shortens. It appears to be under the control of the will, as it moves freely, independently of the amount of light. Its surface is directed obliquely forwards, forming an angle of from 30°—50° with the vertical, and its apex can be retracted almost out of the way of the pupil, or extended so as to nearly meet the lower border of the iris, or inclined so as to touch the posterior surface of the cornea (see p. 27).